



## **Lung Lesions in an Opossum (*Didelphis virginiana*) Associated with *Capillaria didelphis***

Authors: Snyder, Daniel E., Hamir, Amir N., Hanlon, Cathleen A., and Rupprecht, Charles E.

Source: Journal of Wildlife Diseases, 27(1) : 175-177

Published By: Wildlife Disease Association

URL: <https://doi.org/10.7589/0090-3558-27.1.175>

---

BioOne Complete ([complete.BioOne.org](https://complete.BioOne.org)) is a full-text database of 200 subscribed and open-access titles in the biological, ecological, and environmental sciences published by nonprofit societies, associations, museums, institutions, and presses.

Your use of this PDF, the BioOne Complete website, and all posted and associated content indicates your acceptance of BioOne's Terms of Use, available at [www.bioone.org/terms-of-use](https://www.bioone.org/terms-of-use).

Usage of BioOne Complete content is strictly limited to personal, educational, and non - commercial use. Commercial inquiries or rights and permissions requests should be directed to the individual publisher as copyright holder.

---

BioOne sees sustainable scholarly publishing as an inherently collaborative enterprise connecting authors, nonprofit publishers, academic institutions, research libraries, and research funders in the common goal of maximizing access to critical research.

## Lung Lesions in an Opossum (*Didelphis virginiana*) Associated with *Capillaria didelphis*

Daniel E. Snyder,<sup>1</sup> Amir N. Hamir,<sup>2</sup> Cathleen A. Hanlon,<sup>3</sup> and Charles E. Rupprecht,<sup>3</sup> <sup>1</sup>U.S. Department of Agriculture, Agricultural Research Service, Animal Parasite Research Laboratory, POB 952, Auburn, Alabama 36831, USA; <sup>2</sup>University of Pennsylvania, School of Veterinary Medicine, New Bolton Center, 382 West Street Road, Kennett Square, Pennsylvania 19348-1692, USA; <sup>3</sup>The Wistar Institute of Anatomy and Biology, 3601 Spruce St., Philadelphia, Pennsylvania 19104, USA

**ABSTRACT:** An opossum (*Didelphis virginiana*) live-trapped on Parramore Island, Virginia was infected with the lung parasite *Capillaria didelphis*. Lung lesions associated with this parasite were extensive and consisted of numerous areas with central necrosis deep within the parenchyma. Necrotic foci were present around airways and consisted of a mixture of inflammatory cells and cellular debris, adult nematodes and many bipolar eggs. This parasite causes severe verminous pneumonia in the opossum.

**Key words:** *Capillaria didelphis*, nematode, opossum, *Didelphis virginiana*, pathology, pulmonary, Virginia, case report.

Capillariid parasites identified as *Capillaria aerophila* or *Capillaria* sp. have been found in the bronchioles, alveolar spaces and within granulomata or necrotic foci of the lungs of opossum (*Didelphis virginiana*) in the southeastern and eastern United States (Miller and Harkema, 1970; Chitwood and Lichtenfels, 1972; Feldman et al., 1972; Nettles et al., 1975; Prestwood et al., 1977; Gardiner, 1982; Brown, 1988). Butterworth and Beverley-Burton (1977) proposed a new species name, *Capillaria didelphis*, for this parasite, in contrast to *C. aerophila* that is commonly found in the trachea and bronchi of red fox (*Vulpes vulpes*) and other wild carnivores. A previous report described the histopathologic lesions in the lung of opossum associated with concomitant *C. didelphis* and *Didelphostrongylus hayesi* infections (Prestwood et al., 1977). This report further describes lesions in the lung of an opossum naturally and monospecifically infected with *C. didelphis*.

The opossum was live-trapped on Parramore Island, Virginia (USA: 37°32'N, 75°38'W) in August 1989 as part of base-

line data collection prior to oral rabies vaccine field trials (Rupprecht et al., 1986). The animal was euthanized by an intravenous barbiturate overdose and a complete necropsy was performed. The animal was clinically normal prior to euthanasia. Except for two nematode species in the stomach, *Cruzia americana* and *Turgida* (*Physaloptera*) *turgida*, no other gross lesions or parasites were seen in the carcass. Representative tissue sections of all major organs were fixed in 10% neutral buffered formalin, embedded in paraffin, sectioned at 5 µm and stained with hematoxylin and eosin for examination by light microscopy. Histopathologic lesions were seen in the lungs and in the stomach tissue sections. The pulmonary lesions were quite extensive and consisted of many variably sized areas (1 to 3 mm) with central necrosis deep within the parenchyma. In the necrotic foci, a mixture of inflammatory cells and cellular debris, sections of nematodes, and many bipolar eggs were seen (Figs. 1, 2). Necrotic foci were present around airways and in some of the less severely affected areas, outlines of dilated bronchi could be identified with focally ulcerated mucosa (Fig. 3). Elsewhere in the lung, at some distance from the necrotic foci, bronchioles were dilated, had hyperplastic mucosa, and a mixture of mucus, inflammatory cells, and bipolar plugged nematode eggs filled the lumina. There was also marked hyperplasia of smooth muscle surrounding bronchioles and associated blood vessels. Bronchus-associated lymphoid tissue were present; however, this was not a prominent feature of the pulmonary reaction. Endogenous lipid pneumonia as

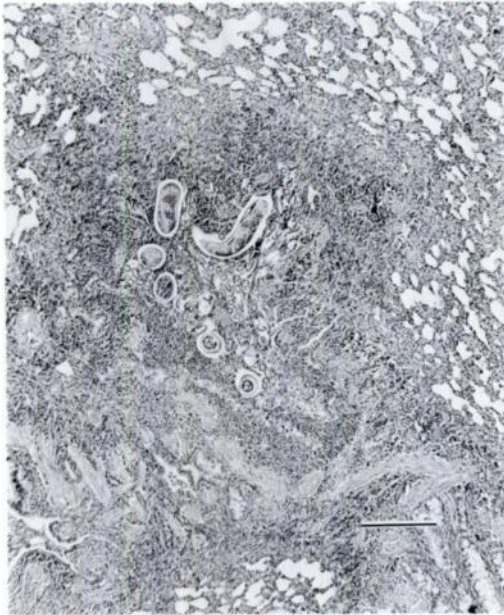

FIGURE 1. Low magnification of *Capillaria didelphis* induced pulmonary lesion containing sections of parasites, eggs, and a mixture of inflammatory cells and cellular debris. Bar = 200  $\mu$ m.

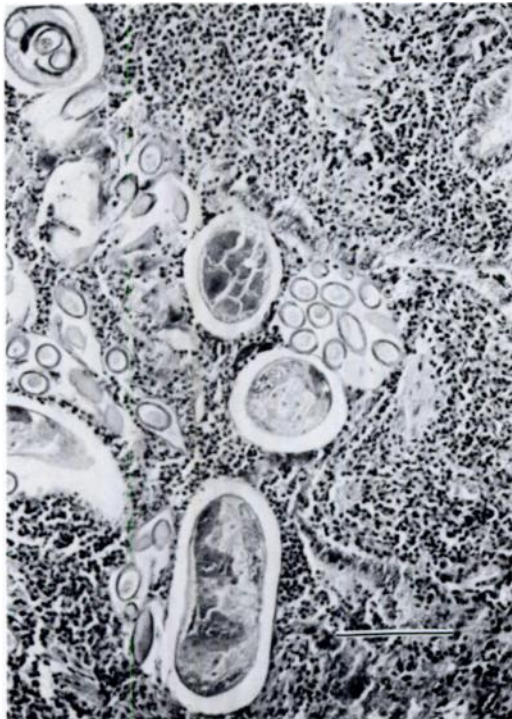


FIGURE 2. *Capillaria didelphis* adults, eggs, and inflammatory cells and cellular debris within pulmonary parenchyma. Bar = 50  $\mu$ m.

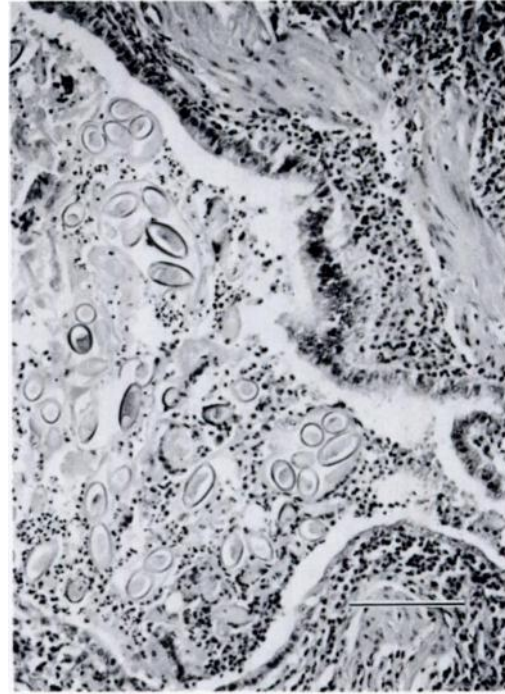


FIGURE 3. Dilated bronchiole containing eggs of *Capillaria didelphis* and inflammatory cells and debris. Mucosa of the dilated bronchiole is partially ulcerated. Bar = 50  $\mu$ m.

described by Brown (1988) in opossums with verminous pneumonia was not seen in this opossum. Gastric lesions were minor and consisted of a few eosinophilic submucosal granulomata with central areas of necrosis containing degenerating nematodes.

Portions of adult worms were dissected from the fixed lung and morphologic features and measurements of these parasites and eggs corresponded to the description of *C. didelphis* given by Butterworth and Beverley-Burton (1977). Representative specimens of *C. didelphis*, including a portion of formalin fixed lung with parasites in situ, are deposited in the U.S. National Parasite Collection (Beltsville, Maryland 20705, USA; accession number 81194).

The microscopic lesions described above are similar to those reported by Prestwood et al. (1977). As these authors noted, the inflammatory reaction in response to *C. didelphis* causes extensive damage to the

pulmonary parenchyma. Extensive pulmonary damage by this parasite and a concomitant burden of gastrointestinal parasites can be lethal to opossum (Prestwood et al., 1977).

The opossum has been used as a laboratory animal in several studies (Sherwood et al., 1969; Vakilzadeh et al., 1971; Jurgelski, 1979). Opossum that are wild caught may harbor *C. didelphis*, other parasites, and associated pulmonary lesions as described above. Thus, researchers should be aware of these infections as they interpret their results.

We thank D. Hayes for technical assistance in the field. This work was supported in part by the Pennsylvania Department of Agriculture.

#### LITERATURE CITED

- BROWN, C. C. 1988. Endogenous lipid pneumonia in opossums from Florida. *Journal of Wildlife Diseases* 24: 214-219.
- BUTTERWORTH, E. W., AND M. BEVERLEY-BURTON. 1977. *Capillaria didelphis* n. sp. (Nematoda: Trichuroidea) from the opossum, *Didelphis virginiana* L. in Georgia. *Canadian Journal of Zoology* 55: 616-619.
- CHITWOOD, M., AND J. R. LICHTENFELS. 1972. Identification of parasitic metazoa in tissue sections. *Experimental Parasitology* 32: 407-519.
- FELDMAN, D. B., J. A. MOORE, M. W. HARRIS, AND J. L. SELF. 1972. Characteristics of common helminths of the Virginia opossum (*Didelphis virginiana*) from North Carolina. *Laboratory Animal Science* 22: 183-189.
- GARDINER, C. H. 1982. Identification of animal parasites in histologic section. Registry of Veterinary Pathology, Armed Forces Institute of Pathology, Washington, D.C., p. 31.
- JURGELSKI, W. 1979. The marsupial as a laboratory animal. *International Laboratory Animal Research News* 22: 18-21.
- MILLER, G. C., AND R. HARKEMA. 1970. Helminths of the opossum (*Didelphis virginiana*) in North Carolina. *Proceedings of the Helminthological Society of Washington* 37: 36-39.
- NETTLES, V. F., A. K. PRESTWOOD, AND W. R. DAVIDSON. 1975. Severe parasitism in an opossum. *Journal of Wildlife Diseases* 11: 419-420.
- PRESTWOOD, A. K., V. F. NETTLES, AND R. L. FARREL. 1977. Pathologic manifestations of experimentally and naturally acquired lungworm infections in opossums. *American Journal of Veterinary Research* 38: 529-532.
- RUPPRECHT, C. E., T. J. WIKTOR, A. N. HAMIR, B. DIETZSCHOLD, W. H. WUNNER, L. T. GLICKMAN, AND H. KOPROWSKI. 1986. Oral immunization and protection of raccoons (*Procyon lotor*) with a vaccinia rabies glycoprotein recombinant virus vaccine. *Proceedings of the National Academy of Sciences USA* 83: 7947-7950.
- SHERWOOD, B. F., D. T. ROWLAND, D. B. HACKEL, AND J. C. LEMAY. 1969. The opossum, *Didelphis virginiana*, as a laboratory animal. *Laboratory Animal Care* 19: 494-499.
- VAKILZADEH, J., B. F. SHERWOOD, D. B. HACKEL, AND J. C. LEMAY. 1971. Experimental study of pulmonary adenomas in the opossum (*Didelphis virginiana*). *Laboratory Animal Science* 21: 224-228.

Received for publication 7 February 1990.