

Introgenic Transmission of *Cytauxzoon felis* from a Florida Panther (*Felis concolor coryi*) to a Domestic Cat

Authors: Butt, Mark T., Bowman, Dwight, Barr, Margaret C., and Roelke, Melody E.

Source: Journal of Wildlife Diseases, 27(2) : 342-347

Published By: Wildlife Disease Association

URL: <https://doi.org/10.7589/0090-3558-27.2.342>

BioOne Complete (complete.BioOne.org) is a full-text database of 200 subscribed and open-access titles in the biological, ecological, and environmental sciences published by nonprofit societies, associations, museums, institutions, and presses.

Your use of this PDF, the BioOne Complete website, and all posted and associated content indicates your acceptance of BioOne's Terms of Use, available at www.bioone.org/terms-of-use.

Usage of BioOne Complete content is strictly limited to personal, educational, and non-commercial use. Commercial inquiries or rights and permissions requests should be directed to the individual publisher as copyright holder.

BioOne sees sustainable scholarly publishing as an inherently collaborative enterprise connecting authors, nonprofit publishers, academic institutions, research libraries, and research funders in the common goal of maximizing access to critical research.

Iatrogenic Transmission of *Cytauxzoon felis* from a Florida Panther (*Felis concolor coryi*) to a Domestic Cat

Mark T. Butt,¹ Dwight Bowman,² Margaret C. Barr,² and Melody E. Roelke,³ ¹Departments of Pathology, and ²Microbiology, Immunology and Parasitology, New York State College of Veterinary Medicine, Cornell University, Ithaca, New York 14853, USA; ³Florida Game and Freshwater Fish Commission, 4005 South Main Street, Gainesville, Florida 32601, USA

ABSTRACT: A laboratory cat died 12 days after intraperitoneal inoculation of a 1 ml suspension containing 1.5×10^6 blood mononuclear cells from a Florida panther (*Felis concolor coryi*). Gross, histologic and ultrastructural investigations revealed the cause of death to be infection by *Cytauxzoon felis*, a protozoal parasite known to cause a rapidly fatal disease (cytauxzoonosis) in domestic cats. The bobcat (*Felis rufus*) has been identified as a natural host for *C. felis*. This report implicates the Florida panther as another possible host for *C. felis*.

Key words: *Cytauxzoon felis*, cytauxzoonosis, Florida panther, *Felis concolor coryi*, iatrogenic infection.

Cytauxzoon felis is a protozoal parasite with an erythrocytic, piroplasm stage and

a schizogenous stage that occurs within cells of the monocyte-phagocyte system (Ferris, 1979; Neitz and Thomas, 1948; Simpson et al., 1985b). It has been reported in bobcats (*Lynx rufus*) (Blouin et al., 1984; Glenn et al., 1982, 1983; Kier et al., 1982a, b; Kocan et al., 1985), and domestic cats (*Felis domesticus*) (Blouin et al., 1982; Ferris, 1979; Franks et al., 1988; Glenn and Stair, 1984; Hauk et al., 1982; Kier et al., 1982b; Wagner, 1976; Wagner et al., 1980). Other species of *Cytauxzoon* have been reported in various African ungulates (Brocklesby, 1962; McCully et al., 1970; Neitz and Thomas, 1948).

Whole blood from a wild, adult (ap-

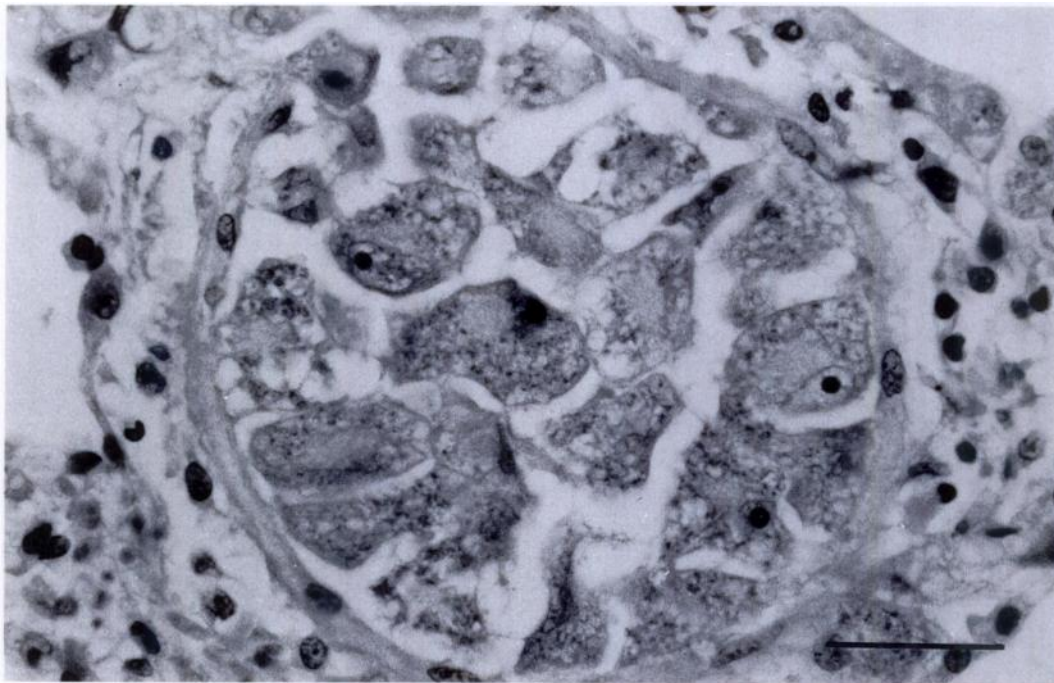


FIGURE 1. A pulmonary vein filled with multiple, enlarged, mononuclear cells containing schizonts of *Cytauxzoon felis*. H&E. Bar = 100 μ m.

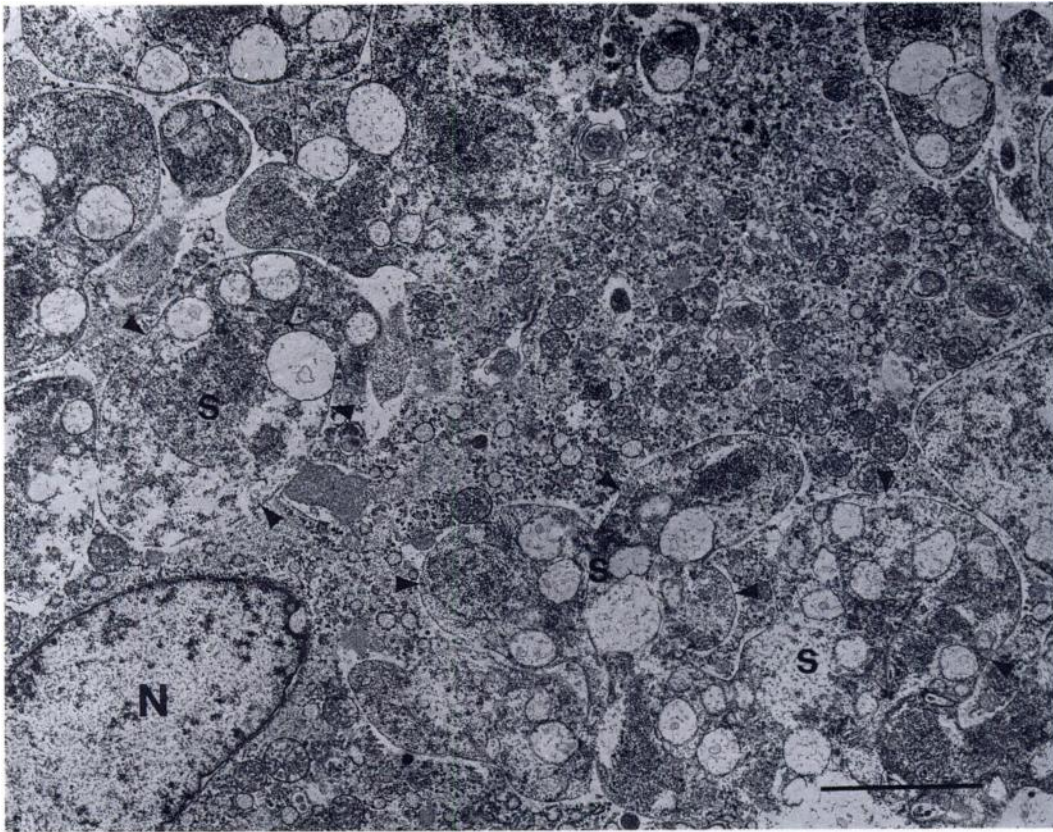


FIGURE 2. Transmission electron micrograph of a macrophage containing multilobated schizonts (s) of *Cytauxzoon felis* (N = cell nucleus) in the spleen. Bar = 1 μ m.

proximately 3-yr-old), female Florida panther (*Felis concolor coryi*) was sent to the New York State College of Veterinary Medicine (Cornell University, Ithaca, New York 14853, USA) to determine the feline immunodeficiency virus (FIV) status. This panther was in the longterm care of the Florida Game and Fresh Water Fish Commission (FGFC) (Wildlife Research Laboratory, Gainesville, Florida 32601, USA) recovering from orthopedic injuries sustained when she was struck by an automobile. Using Western blot analysis (Barr et al., 1989), two previous serum samples from this animal had been examined for the presence of FIV antibody. The first sample had been positive; the second sample was negative.

Mononuclear cells were separated from the whole blood using a ficoll/diatrizoate

sodium gradient, washed and suspended in phosphate buffered saline. One milliliter of the suspension, containing approximately 1.5×10^6 mononuclear cells (as determined by trypan blue exclusion/hemocytometer) was administered by intraperitoneal inoculation into an adult, 3.9 kg, female, spayed domestic cat. This cat was SPF reared (Liberty Labs, Liberty Corners, New Jersey 07938, USA), laboratory housed (AAALAC accredited facilities) without direct contact with other cats, feline leukemia virus (FeLV) antigen negative (Virachek/FeLV, Synbiotics, San Diego, California 92127, USA) and FIV antibody negative (Pet Chek FTLV Antibody Test Kit, IDEXX Corp., Portland, Maine 04101, USA). Seroconversion of the recipient animal would indicate presence of FIV antigens in the blood mononuclear

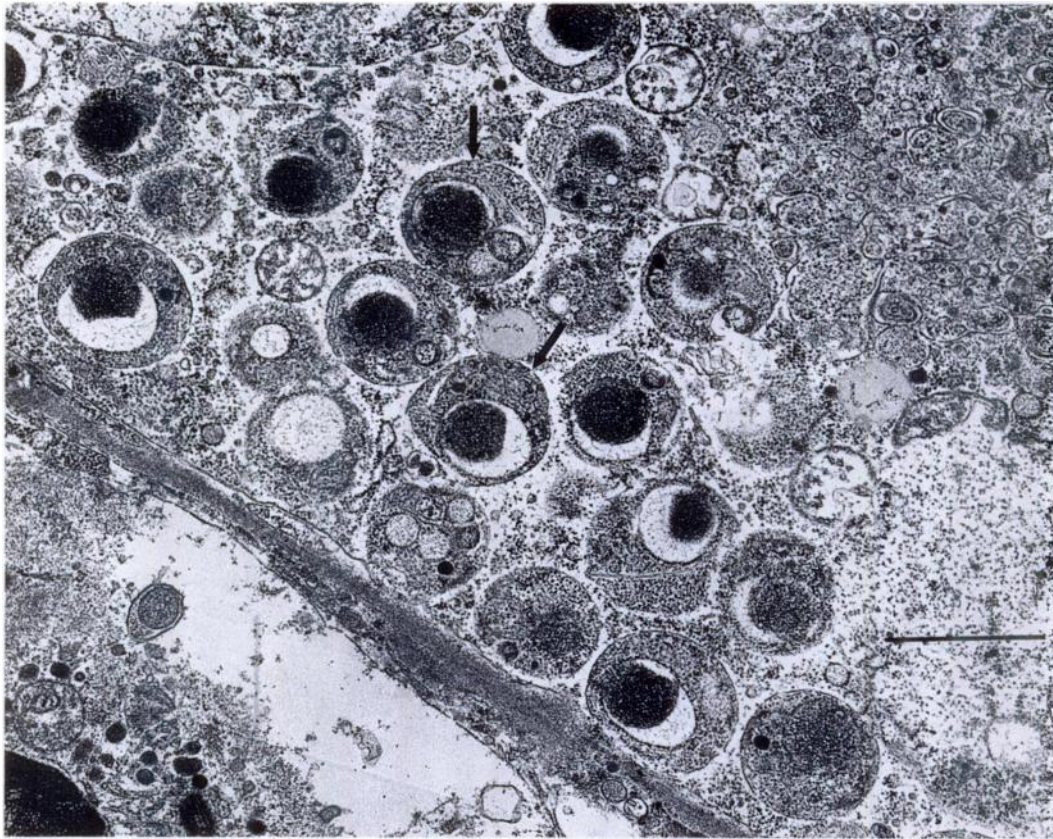


FIGURE 3. Transmission electron micrograph of a splenic macrophage with many, mature *Cytosporidium felis* merozoites (arrows) free in the cytoplasm. Bar = 0.5 μm .

cells of the donor panther and probable FIV infection of the domestic cat. Eleven days postinoculation, the cat was found depressed and febrile (40.1 C) with a hematocrit of 25% and a white blood cell count of 7,920/ μl . The cat was started on trimethoprim/sulfadiazine (Tribrissen (R) injectable, Coopers Animal Health, Inc., Kansas City, Missouri 64108, USA; 60 mg subcutaneous twice a day) and lactated ringers solution subcutaneously but died the following day.

At post mortem, gross lesions were mild splenic enlargement, 25 ml of clear, slightly yellow, serous fluid in the pleural cavity, and many petechia scattered throughout the pleural surface of the lungs and the subcapsular portion of both kidneys. Tissues from the major organs were placed in 10% neural buffered formalin. Formalin

fixed tissues were paraffin embedded, sectioned at 6 μm and stained with hematoxylin and eosin. Slides were deposited in the U.S. National Parasite Collection (Animal Parasitology Institute, U.S. Department of Agriculture, Beltsville, Maryland 20705, USA; Accession number 81003). Multiple 1 mm³ portions of spleen, kidney and lung were placed in a solution of 2% paraformaldehyde/2.5% glutaraldehyde and processed for transmission electron microscopic examination. A sample of spleen and cardiac blood were submitted for FIV isolation and serologic examination. Smears of heart blood were stained with a Wrights procedure (Coles, 1986).

On light microscopic examination, vascular spaces in the lung, liver, spleen, bone marrow, kidney and brain contained, and often were filled by numerous, greatly en-

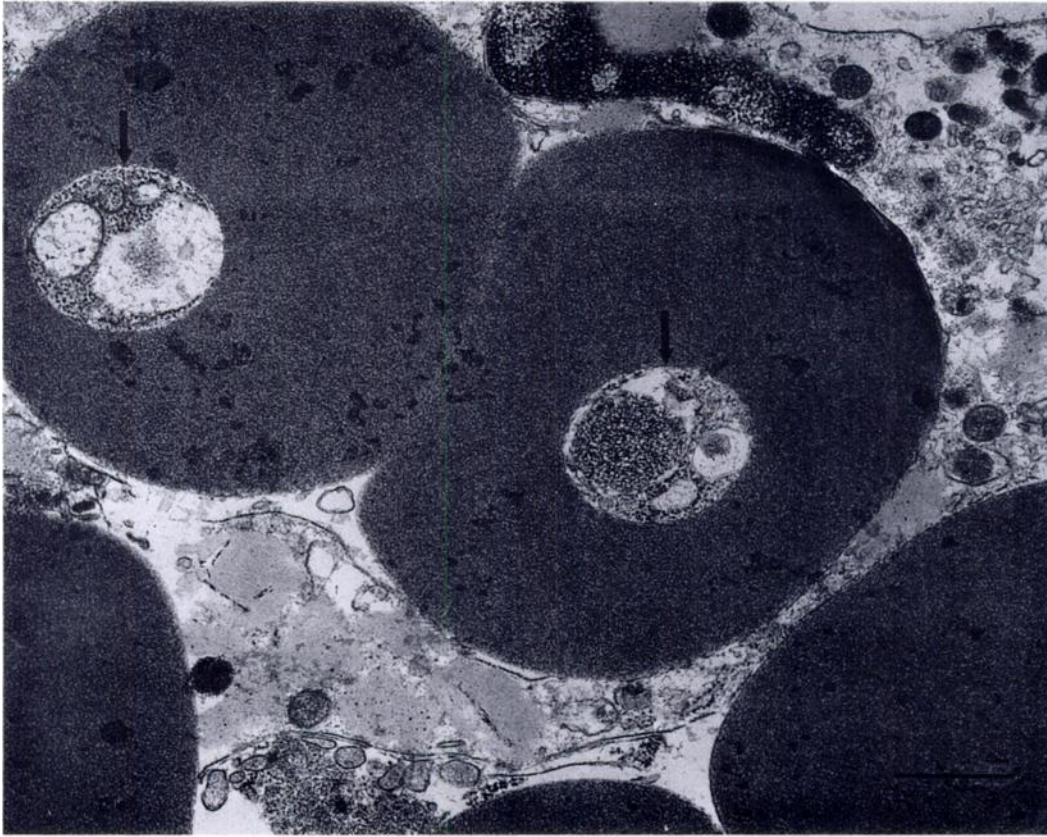


FIGURE 4. Transmission electron micrograph of intraerythrocytic (piroplasm) form (small arrows) of *Cytauxzoon felis* in the spleen. Bar = 1 μm .

larged mononuclear cells. The venous vasculature was consistently affected and many veins appeared totally occluded by accumulations of mononuclear cells. The mononuclear cells were 40 to 100 μm in diameter and contained a 10 to 30 μm , vesicular nucleus with a prominent round to oval, magenta nucleolus. The cytoplasm of most cells contained multiple, variably definable, lobulated structures which were coarsely vacuolated, granular and basophilic. At 1,000 \times magnification, the granularity was observed to be due to an accumulation of many, 2 to 3 μm , clear to vesicular, round structures with moderately defined borders and one or more distinct basophilic round structures. The lobulated cytoplasmic structures were comparable to those described as schizonts containing developing stages of *C.*

felis (Ferris, 1979; Glenn and Stair, 1984; MacWilliams, 1987; Wagner et al., 1980) (Fig. 1). Histologic sections and blood smears revealed approximately 10% of intact erythrocytes contained one (occasionally two), 1 to 2 μm , central, round to oval structures with distinct, unipolar chromatin and clear to pale grey cytoplasm. These structures were comparable to previously described piroplasms of *C. felis* (MacWilliams, 1987; Simpson et al., 1985a). The ultrastructure of the mononuclear (schizogenous) stages and the intraerythrocytic (piroplasm) stage of the organism was comparable to previous descriptions of *C. felis* (Simpson et al., 1985a, b) (Figs. 2, 3, 4).

Antibodies to FIV (Western blot analysis (Barr, 1989); PetChek FTLV Antibody Test Kit, IDEXX Corp.) were not detected in

the serum; FIV was not isolated from the blood or spleen.

The infection of this domestic cat shows the typical clinical signs, gross lesions, and histologic and ultrastructural features of previously described experimental and natural cytauxzoonosis in the domestic cat (Blouin et al., 1984; Ferris, 1979; Franks et al., 1988; Glenn and Stair, 1984; Hauck et al., 1982; Kier et al., 1982a, b; MacWilliams, 1987; Simpson et al., 1985b; Wagner, 1976; Wagner et al., 1980). The bobcat (*L. rufus*) is believed to be the natural reservoir host for the organism based on the prevalence of the erythrocytic form in wild bobcats, the geographic distribution of the natural infection in domestic cats and the experimental transmission of the organism from bobcats to domestic cats (Glenn et al., 1982; Kier et al., 1982a, b). The panther (*F. concolor*) has not been previously documented to be a carrier of *C. felis*. A previous attempt to experimentally infect a panther using infected bobcat blood was unsuccessful (Kier et al., 1982b). However, the fatal infection of this domestic cat following inoculation of blood constituents from a Florida panther provides evidence that this sub-species can be a host for *C. felis*. Retrospective examination of the donor panther's blood smears has revealed rare, intraerythrocytic piroplasms. Because this panther had received two blood transfusions (from *F. concolor* donors), it is not known whether her infection was natural or iatrogenic. The source of this panther's infection and the prevalence of *C. felis* infection in the Florida panther is presently under investigation by the FGFC and the College of Veterinary Medicine (University of Florida, Gainesville, Florida 32601, USA).

Partial funding for this project was provided by the Florida Game and Freshwater Fish Commission, federal grant-in-aid funds, administered through the United States Fish and Wildlife Service under section 6 of the Endangered Species Act of 1973 (PL no. 93-205, PG1-GFC).

LITERATURE CITED

- BARR, M. C., P. P. CALLE, M. E. ROELKE, AND F. W. SCOTT. 1989. Feline immunodeficiency virus infection in nondomestic felids. *Journal of Zoo and Wildlife Medicine* 20: 265-272.
- BLOUIN, E. F., A. A. KOCAN, B. L. GLENN, K. M. KOCAN, AND J. A. HAIR. 1984. Transmission of *Cytauxzoon felis* Kier, 1979 from bobcats, *Felis rufus* (Schreber), to domestic cats by *Dermacentor variabilis* (Say). *Journal of Wildlife Diseases* 20: 241-242.
- BROCKLESBY, D. W. 1962. *Cytauxzoon taurotragti*, Martin and Brocklesby, 1960, a piroplasm of the eland (*Taurotragus oryx pattersonianus* Lydekker, 1906). *Research in Veterinary Science* 3: 334-434.
- COLES, E. H. 1986. *Veterinary clinical pathology*, 4th ed., W. B. Saunders Co., Philadelphia, Pennsylvania, 486 pp.
- FERRIS, D. H. 1979. A progress report on the status of a new disease of American cats: Cytauxzoonosis. *Comparative Immunology, Microbiology and Infectious Disease* 1: 269-276.
- FRANKS, P. T., J. W. HARVEY, R. P. SHIELDS, AND M. J. LAWMAN. 1988. Hematological findings in experimental feline cytauxzoonosis. *Journal of the American Animal Hospital Association* 24: 395-401.
- GLENN, B. L., R. E. ROLLEY, AND A. A. KOCAN. 1982. *Cytauxzoon*-like piroplasms in erythrocytes of wild trapped bobcats in Oklahoma. *Journal of the American Veterinary Medical Association* 181: 1251-1253.
- , A. A. KOCAN, AND E. F. BLOUIN. 1983. Cytauxzoonosis in bobcats. *Journal of the American Veterinary Medical Association* 183: 1155-1158.
- , AND E. L. STAIR. 1984. Cytauxzoonosis in domestic cats: Report of two cases in Oklahoma, with a review and discussion of the disease. *Journal of the American Veterinary Medical Association* 184: 822-825.
- HAUCK, W. N., T. G. SNIDER, AND J. E. LAWRENCE. 1982. Cytauxzoonosis in a native Louisiana cat. *Journal of the American Veterinary Medical Association* 180: 1472-1474.
- KIER, A. B., J. E. WAGNER, AND L. G. MOREHOUSE. 1982a. Experimental transmission of *Cytauxzoon felis* from bobcats (*Lynx rufus*) to domestic cats (*Felis domesticus*). *American Journal of Veterinary Research* 43: 97-101.
- , S. R. WIGHTMAN, AND J. E. WAGNER. 1982b. Interspecies transmission of *Cytauxzoon felis*. *American Journal of Veterinary Research* 43: 102-105.
- KOCAN, A. A., E. F. BLOUIN, AND B. L. GLENN. 1985. Hematologic and serum chemical values for free-ranging bobcats, *Felis rufus* (Schreber), with reference to animals with natural infections of *Cy-*

- tauxoon felis* Kier, 1979. *Journal of Wildlife Diseases* 21: 192-194.
- MACWILLIAMS, P. S. 1987. Erythrocytic rickettsia and protozoa of the dog and cat. *In* Parasitic infections. *Veterinary Clinics of North America, Small Animal Practice* 17: 1443-1461.
- MCCULLY, R. M., M. E. KEEP, AND P. A. BASSON. 1970. Cytauxzoonosis in a giraffe (*Giraffa camelopardalis* (Linnaeus, 1758)) in Zululand. *Onderstepoort Journal of Veterinary Research* 37(1): 7-10.
- NEITZ, W. O., AND A. D. THOMAS. 1948. *Cytauxzoon sylvicaprae* gen. nov., spec. nov., a protozoan responsible for a hitherto undescribed disease in the duiker (*Sylvicapra grimmia* (Linne)). *Onderstepoort Journal of Veterinary Science and Animal Industry* 23: 63-76.
- SIMPSON, C. F., J. W. HARVEY, AND J. W. CARLISLE. 1985a. Ultrastructure of the intraerythrocytic stage of *Cytauxzoon felis*. *American Journal of Veterinary Research* 46: 1178-1180.
- , ———, M. J. LAWMAN, J. MURRAY, A. A. KOCAN, AND J. W. CARLISLE. 1985b. Ultrastructure of schizonts in the liver of cats with experimentally induced cytauxzoonosis. *American Journal of Veterinary Research* 46: 384-390.
- WAGNER, J. E. 1976. A fatal cytauxzoonosis-like disease in cats. *Journal of the American Veterinary Medical Association* 168: 585-588.
- , D. H. FERRIS, A. S. KIER, S. R. WIGHTMAN, E. MARING, L. G. MOREHOUSE, AND R. D. HANSEN. 1980. Experimentally induced cytauxzoonosis-like disease in domestic cats. *Veterinary Parasitology* 6: 305-311.

Received for publication 22 May 1990.