



KERATITIS IN FREE-RANGING KOALAS (PHASCOLARCTOS CINEREUS) ON MAGNETIC ISLAND, TOWNSVILLE

Authors: Hirst, Lawrence W., Brown, Anthony Stephen, Kempster, Roxanne, Hall, Jenny, and Woolcock, John B.

Source: Journal of Wildlife Diseases, 28(3) : 424-427

Published By: Wildlife Disease Association

URL: <https://doi.org/10.7589/0090-3558-28.3.424>

BioOne Complete (complete.BioOne.org) is a full-text database of 200 subscribed and open-access titles in the biological, ecological, and environmental sciences published by nonprofit societies, associations, museums, institutions, and presses.

Your use of this PDF, the BioOne Complete website, and all posted and associated content indicates your acceptance of BioOne's Terms of Use, available at www.bioone.org/terms-of-use.

Usage of BioOne Complete content is strictly limited to personal, educational, and non - commercial use. Commercial inquiries or rights and permissions requests should be directed to the individual publisher as copyright holder.

BioOne sees sustainable scholarly publishing as an inherently collaborative enterprise connecting authors, nonprofit publishers, academic institutions, research libraries, and research funders in the common goal of maximizing access to critical research.

KERATITIS IN FREE-RANGING KOALAS (*PHASCOLARCTOS CINEREUS*) ON MAGNETIC ISLAND, TOWNSVILLE

Lawrence W. Hirst,¹ Anthony Stephen Brown,² Roxanne Kempster,¹ Jenny Hall,³ and John B. Woolcock³

¹ Division of Ophthalmology, 2nd Floor, Lions Research Building, Princess Alexandra Hospital, Ipswich Road, Woolloongabba, Brisbane 4102, Queensland, Australia

² C/- Division of Environment, Prime Minister's Office, Apia, Western Samoa

³ Department of Microbiology, The University of Queensland, St. Lucia, Brisbane 4072, Queensland, Australia

ABSTRACT: Seventy free-ranging koalas (*Phascolarctos cinereus*) from Magnetic Island (Queensland, Australia) underwent an ocular examination, blood collection and serological examination for *Chlamydia psittaci* antibodies, and an examination of their teeth and genitalia. In 12 koalas long-standing unilateral keratitis was noted and in another 10 animals long-standing bilateral keratitis was observed. All animals were seronegative for *Chlamydia psittaci* and apart from some nasal discharge and a variety of assorted medical findings there was no sign of chlamydial infection. These ocular findings probably represent a new disease of unknown etiology.

Key words: *Phascolarctos cinereus*, keratitis, *Chlamydia psittaci*, survey, unknown etiology.

INTRODUCTION

Koalas (*Phascolarctos cinereus*) were released onto Magnetic Island (Townsville, Queensland, Australia) from the mainland in the 1920's. Magnetic Island is a tropical island located off the coast of Townsville in Queensland Australia between 20° and 25° latitude and 145° and 150° longitude. Since that time, there have been anecdotal reports of an endemic eye disease in this free-ranging population of koalas. This study was undertaken to describe and attempt to identify this disease.

MATERIALS AND METHODS

During March 1989 over a 3 wk period, koalas were coaxed down from trees using a red flag and a noose and restrained in hessian bags upon capture. Hand light examination of the eyes and, in some cases, portable slit-lamp examination of the eyes were undertaken. Eyes with abnormalities were photographed using external macrophotographic equipment (Nikon Corporation, Fuji Building, 2–3 Marunouchi 3 chome, Chiyoda-ku, Tokyo 100, Japan) giving a final magnification of one to one. The animals also were aged by examination of toothwear (Martin, 1981), sexed by examination of external genitalia and a blood sample was collected for serological examination. This appearance is in marked contrast to the regressed state of chlamydial keratitis and conjunctivitis in koalas where subconjunctival scarring is seen, and diffuse vascularization with minimal stromal

changes is noted in the cornea. The animals were identified using plastic ear tags and then released immediately back into their trees. The appropriate Queensland National Parks and Wildlife Service permits were obtained.

RESULTS

Seventy animals were captured. One animal was found ill and died within 2 days of capture. Autopsy revealed a generalized toxemia caused by *Pseudomonas pseudomallei* (Ladds et al., 1990). The age range was 1 yr to about senility, weight range 1.65 to 8.7 kg in males and 1.5 to 6.6 kg in females and sex distribution of 32 females and 38 males. Two back-young (from the previous breeding season) and 16 pouch-young also were recorded.

Old unilateral keratitis was observed in 12 koalas, while old bilateral keratitis (Fig. 1) was seen in another 10 animals. The slit-lamp appearance of the quiescent keratitis was uniform but non-specific in most of the animals. There was a dense, usually central corneal scar involving much of the stromal thickness frequently leaving the peripheral cornea spared (Fig. 2). Occasionally, patent blood vessels crossed the limbus to enter the stromal scar. There was a noticeable lack of inflammation of the cornea and anterior chamber, the cornea was epithelialized, the stroma was not



FIGURE 1. Koala showing bilateral old keratitis and opaque corneas from old keratitis.

oedematous nor infiltrated with inflammatory cells, and the conjunctiva was unremarkable.

Additional ocular pathology consisted of a descemetocele in one animal and a cataract in another koala. Acute ocular discharge was seen in 16 animals and nasal discharge in five. In 11 eyes with keratitis associated ocular discharge was noted. In a further 17 eyes some ocular discharge was present but no keratitis was seen. In only three cases was nasal discharge present in koalas in which old keratitis was seen. In a further two cases nasal discharge was observed with no associated old ocular changes. Additional medical findings in these koalas were urinary incontinence in five, emaciation in two, cestodes (*Bertiella obesa*) in one, oral tumour in one, ulcerative facial dermatitis in one and scoliosis in one.

The sera taken from all koalas were seronegative for *Chlamydia psittaci* antibodies and eight were seropositive for *Pseudomonas pseudomallei* antibodies.

DISCUSSION

Currently, *Chlamydia psittaci* has been considered a primary cause of ocular infections and corneal opacities in koalas. However, an estimate of the prevalence of chlamydial infected koalas and the range of chronic ocular change in Australia is

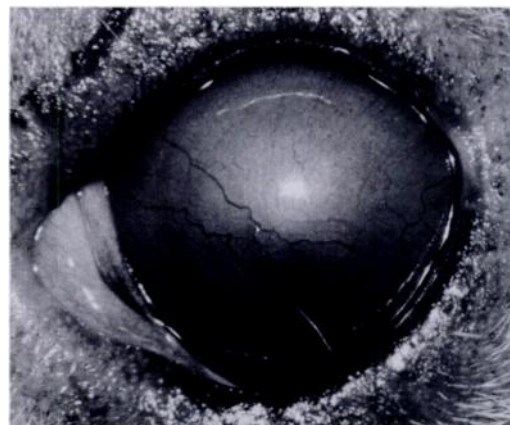


FIGURE 2. External photograph of left eye of koala with old keratitis demonstrating opacity of the cornea and widespread surface vascularization.

unknown (Brown, 1987; Cockram and Jackson, 1974).

We undertook a survey of free-ranging koalas in a restricted geographic environment which had not had recent contact with koala populations on the mainland. Of 70 koalas captured on Magnetic Island, there were ocular abnormalities found in 33%. Of these, 22 had sufficient corneal changes to suggest that the koala would have very limited vision or be blind. Despite ocular discharge and occasional nasal discharge in some, none of the lesions resembled either the acute or chronic changes noted in koalas with chlamydial ocular infection as described (Brown and Grice, 1986). The dense central corneal opacities with vascularization are unlike the acute oedema and vascularization that may be seen in acute chlamydial infection. It is also not typical of the faint subconjunctival scarring, corneal vascularization and opacity in regressed chlamydial keratitis. In addition, 16 koalas were observed with unilateral keratitis which was unusual if the disease was caused by *Chlamydia psittaci*. No acute corneal changes were noted, which also is unusual if an endemic infective process was present taking into account the number of eyes that had corneal abnormalities. This may be explained by a previous epidemic of infectious nature which had now spontaneously remitted or may be due to some other possible etiology. However, experience with chlamydial infection in koalas does not suggest that there is a likelihood of spontaneous remission in an entire infected population, and that even if there was remission of such ocular infections, accompanying genitourinary involvement could almost certainly be expected. This could be explained in the Magnetic Island population by a chlamydial infection some time in the past with only those koalas surviving which did not have significant systemic involvement. Failure to detect anti-chlamydial antibodies in all of these animals would make it unlikely that *Chlamydia psittaci* was the causative agent of these corneal changes.

However, it is possible that they may still seroconvert.

If these corneal changes are not caused by infection with *Chlamydia psittaci*, then another etiology must be found. In an examination of the aerobic bacterial flora of diseased and normal eyes of koalas, no potential pathogens were regularly recovered (Mutimer et al., 1990). In the present study, general lack of systemic disease, the corneal morphology with the large but well localized area of corneal involvement, significant vascularization and otherwise unremarkable ocular appearance may suggest that an external environmental agent is responsible. This agent has not been identified.

Despite significant bilateral corneal opacities in some koalas, most of them appear to be surviving well in the wild, although one blind animal had previously been brought into captivity because of an inability to fend for itself and is maintained in a sanctuary (Koala Park Oasis, Horseshoe Bay, Magnetic Island, Queensland, Australia). This might suggest that the inability of apparently blind koalas with acute chlamydial infection to survive is related to their general systemic disease rather than their visual disability.

Affected animals appeared to be capable of mating and producing off-spring despite their corneal opacities. All of the lesions we observed were apparently old. If an ongoing insult is present in the Magnetic Island koala population then we could have expected to see at least some koalas with corneal disease representing the acute manifestations of the process. It is possible that the disease is associated with an acute high mortality, although this appears unlikely with the surviving animals manifesting no other systemic abnormalities and no accompanying report of mortality within the population. The more likely explanation is that either the acutely affected koalas cannot be accessed or examined by virtue of their acute disease, or that the disease is epidemic and the last epidemic was some time ago.

This survey has described an unusual new ocular disease, unlike typical regressed chlamydial disease, which is extremely common in the Magnetic Island population. Although koalas may function normally, despite significant visual impairment from corneal opacities, further investigation needs to be undertaken to determine the etiology and pathogenesis of this disease.

ACKNOWLEDGMENTS

Financial support was provided in part by the Australian Foundation for the Prevention of Blindness (Queensland Division), the Centre for Wildlife Research Incorporated, the Australian Koala Foundation, Care for the Wild, Rusper, England, and the Centre for Wildlife Research Inc., Bond University, Queensland. We also are grateful for the generous assistance provided by Mr. and Mrs. Geoff d'Argeavel of Koala Park Oasis, Horsehoe Bay, Magnetic Island, Queensland, Australia.

LITERATURE CITED

- BROWN, A. S., AND R. G. GRICE. 1986. Experimental transmission of *Chlamydia psittaci* in the koala. In Chlamydial infections, D. Oriel, R. Ridgway, J. Schachter, D. Taylor-Robinson, and M. Wards (eds.). Proceedings of the Sixth International Symposium of Human Chlamydial Infections, Cambridge University Press, Cambridge, England, pp. 349–352.
- . 1987. Infertility in the female koala (*Phascolarctos cinereus*). Ph.D. Thesis. University of Queensland, St. Lucia, Queensland, Australia, 256 pp.
- COCKRAM, F. A., AND A. R. B. JACKSON. 1974. Isolation of a *Chlamydia* from cases of keratoconjunctivitis in koalas. Australian Veterinary Journal 50: 82–83.
- LADDS, P. W., A. D. THOMAS, R. SPEARE, AND A. S. BROWN. 1990. Meliodosis in a koala. Australian Veterinary Journal 67: 304–305.
- MARTIN, R. W. 1981. Age-specific fertility in three populations of the koala (*Phascolarctos cinereus*) Goldfuss, in Victoria. Australian Wildlife Research 8: 275–283.
- MUTIMER, M. D., J. B. WOOLCOCK, AND A. S. BROWN. 1990. Aerobic bacterial flora of the conjunctiva of *Phascolarctos cinereus* (koala). Australian Wildlife Research 17: 189–193.

Received for publication 18 September 1990.