

## **ECTOPARASITE-INDUCED LESIONS IN MITE POCKETS OF THE YARROW'S SPINY LIZARD, SCELOPORUS JARROVII (PHRYNOSOMATIDAE)**

Authors: Goldberg, Stephen R., and Holshuh, H. J.

Source: Journal of Wildlife Diseases, 28(4) : 537-541

Published By: Wildlife Disease Association

URL: <https://doi.org/10.7589/0090-3558-28.4.537>

---

BioOne Complete ([complete.BioOne.org](https://complete.BioOne.org)) is a full-text database of 200 subscribed and open-access titles in the biological, ecological, and environmental sciences published by nonprofit societies, associations, museums, institutions, and presses.

Your use of this PDF, the BioOne Complete website, and all posted and associated content indicates your acceptance of BioOne's Terms of Use, available at [www.bioone.org/terms-of-use](https://www.bioone.org/terms-of-use).

Usage of BioOne Complete content is strictly limited to personal, educational, and non - commercial use. Commercial inquiries or rights and permissions requests should be directed to the individual publisher as copyright holder.

---

BioOne sees sustainable scholarly publishing as an inherently collaborative enterprise connecting authors, nonprofit publishers, academic institutions, research libraries, and research funders in the common goal of maximizing access to critical research.

## ECTOPARASITE-INDUCED LESIONS IN MITE POCKETS OF THE YARROW'S SPINY LIZARD, *SCELOPORUS JARROVII* (PHRYNOSOMATIDAE)

Stephen R. Goldberg,<sup>1</sup> and H. J. Holshuh<sup>2</sup>

<sup>1</sup> Department of Biology, Whittier College, Whittier, California 90608, USA

<sup>2</sup> Comparative Medical and Veterinary Services, County of Los Angeles,  
Laboratory and Disease Investigation, 12824 Erickson Avenue, Downey, California 90242, USA

**ABSTRACT:** Histopathological effects of the chigger, *Eutrombicula lipovskyana*, on the mite pockets of neonatal, juvenile and adult Yarrow's spiny lizard, *Sceloporus jarrovi*, were investigated. Focal ulcerative dermatitis was noted in all age classes. This reaction was more diffuse in older animals in which penetration as deep as the panniculus occurred. Based on the occurrence of inflammatory reactions in neonatal lizards, *S. jarrovi* appears capable of recognizing foreign antigens shortly after birth. There was an increased inflammatory response in older lizards that may have been an augmented host sensitivity following repeated exposure to chiggers. Granulomas, which were interpreted as an attempt to isolate the effects of chigger bites, were noted in juveniles and adults. We propose that *S. jarrovi* does not develop resistance after repeated exposures to *E. lipovskyana*.

**Key words:** *Sceloporus jarrovi*, Phrynosomatidae, histopathology, inflammation, mite pocket, granuloma, ectoparasite, chigger, *Eutrombicula lipovskyana*.

### INTRODUCTION

While lizards give an inflammatory response to ectoparasite attachment (Goldberg and Bursey, 1991; Auffenberg and Auffenberg, 1990), little is known about the nature of these ectoparasite-induced inflammatory responses. Basic reptilian inflammatory reactions have been reviewed by Montali (1988). Our objective was to characterize inflammatory responses in neonatal, juvenile and adult Yarrow's spiny lizard, *Sceloporus jarrovi*. We selected *S. jarrovi* for our study as this live-bearing lizard gives birth in late June each year (Goldberg, 1971) allowing us to collect neonatal lizards. We limited our examination to the mite pockets. These are two areas, one on each side of the gular region, where ectoparasites aggregate (Arnold, 1986). The mite pockets lack scales and are covered by squamous epithelium.

### MATERIALS AND METHODS

Neonatal, juvenile and adult Yarrow's spiny lizards, *Sceloporus jarrovi* were collected by hand-held noose at Kitt Peak (31°95'N, 111°59'W, elevation 1,889 m) in the Baboquivari Mountains, 85 km southwest of Tucson, Pima County, Arizona. Neonates were collected 28 to 30 June 1991; juveniles and adults were

collected 3 to 6 October 1991. We examined 31 neonatal lizards; their mean (SD) snout-vent length (SVL) was 30.1 (2.1) mm, with a range of 26 to 36 mm. Nine juveniles had a mean SVL of 54.6 (4.0) mm, with a range of 48 to 57 mm; 12 adults had a mean SVL of 81.3 (5.8) mm, with a range of 72 to 92 mm. Approximate ages of neonates (1 to 14 days) were determined by comparing them to 223 *S. jarrovi* neonates born of 37 captive female lizards in 1967 to 1969 (Goldberg, 1970). Juveniles were born June 1991; adults were born June 1990 or in an earlier year. Lizards were euthanized by a 0.05 cc intraperitoneal injection of sodium pentobarbital (Nembutal® Sodium, Abbott Laboratories, North Chicago, Illinois, USA). Infested tissues (mite pockets) were preserved in 10% neutral buffered formalin. Tissues were embedded in paraffin, sectioned at 5 µm and stained with hematoxylin and eosin. Selected tissues were stained with Price's Giemsa stain or Masson's trichrome stain (Luna, 1968).

### RESULTS

The two ectoparasites found on *S. jarrovi* were the chigger, *Eutrombicula lipovskyana* and the mite, *Geckobiella texana*. *Eutrombicula lipovskyana* was the main occupant of the mite pockets with only rare nymphal *G. texana* present. Representative specimens were deposited in the U.S. National Helminthological Collection (Beltsville, Maryland 20705) as U.S.

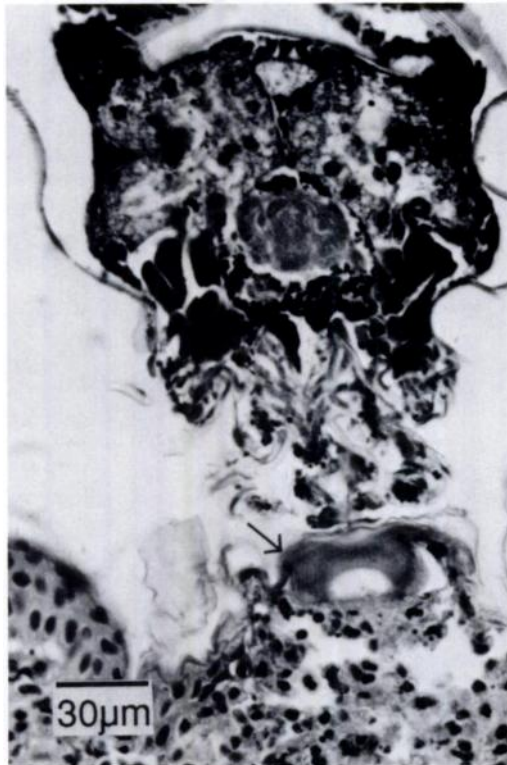


FIGURE 1. Neonatal *Sceloporus jarrovi*. Attachment of chigger, *Eutrombicula lipovskyana*; note eosinophilic mass (arrow) where stylostome penetrates integument. H&E.

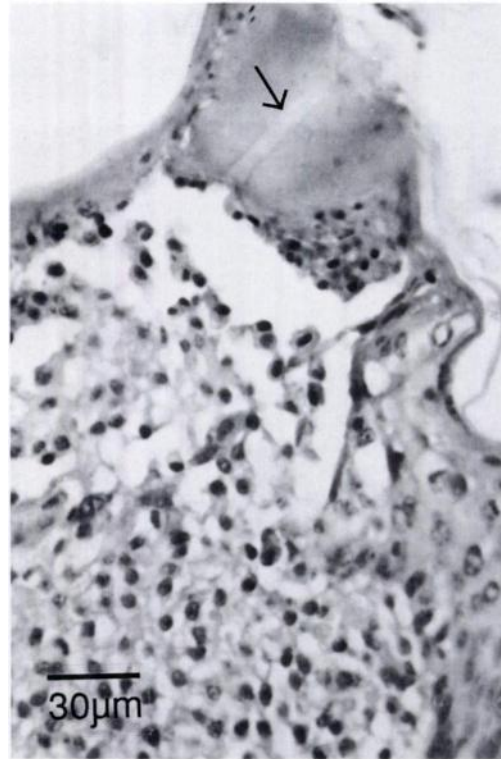


FIGURE 2. Neonatal *Sceloporus jarrovi*. Focal ulcerative dermatitis with underlying cellular response to chigger stylostome. Note feeding channel (arrow). H&E.

National Helminthological Collection No. 81992 for *E. lipovskyana* and 82007 for *G. texana*.

In neonate lizards, the stylostomes, tubes through which chiggers (Fig. 1) take fluid from the host, were surrounded by an eosinophilic mass of coagulated host proteins with underlying inflammatory cells. There was focal ulcerative dermatitis with mild to moderate epithelial hyperplasia and keratosis surrounding the chigger attachment site. Some ballooning degeneration and early necrosis were noted in this epithelium. A cluster of macrophages typically migrated through the disrupted basement membrane beneath the stylostome which was anchored in the epidermis (Fig. 2). The dermal inflammatory cell infiltrate included heterophils, lymphocytes, plasma cells and macrophages (histiocytes). In one

case lymphocytes had infiltrated skeletal muscle bundles. Well-organized granulomas were not seen in neonatal lizards. Some neonates had a relatively mild reaction, with few inflammatory cells present.

A greater response was noted among juveniles, and all elements of the neonatal inflammatory reaction were present with increased cellularity. Focal ulceration was seen at the point of stylostome penetration. We noted necrotic epithelial cells at the base of the stylostome. There was migration of inflammatory cells including heterophils and histiocytes into the pit of the ulcer. A serocellular crust of serum proteinaceous exudate sometimes was present adjacent to the ulcer. There was an attempt to wall off the ulcer with layers of hyperplastic squamous epithelial cells at the base of the lesion. Hyperkeratosis and

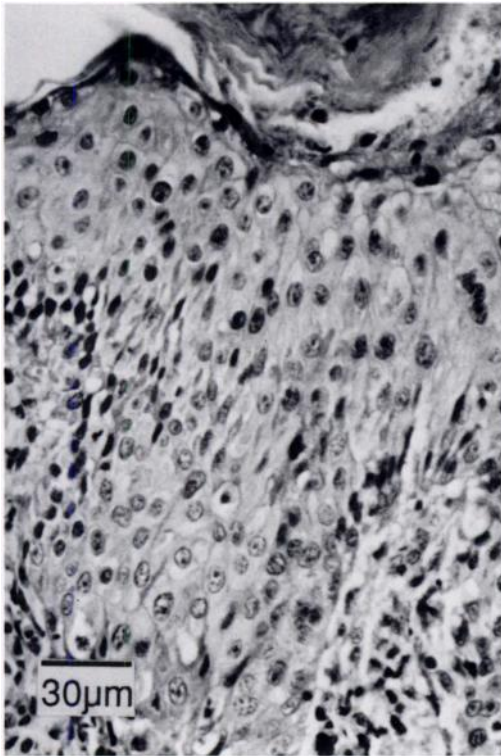


FIGURE 3. Juvenile *Sceloporus jarrovi*. Epidermal hyperplasia with hyperkeratosis and exocytosis. H&E.

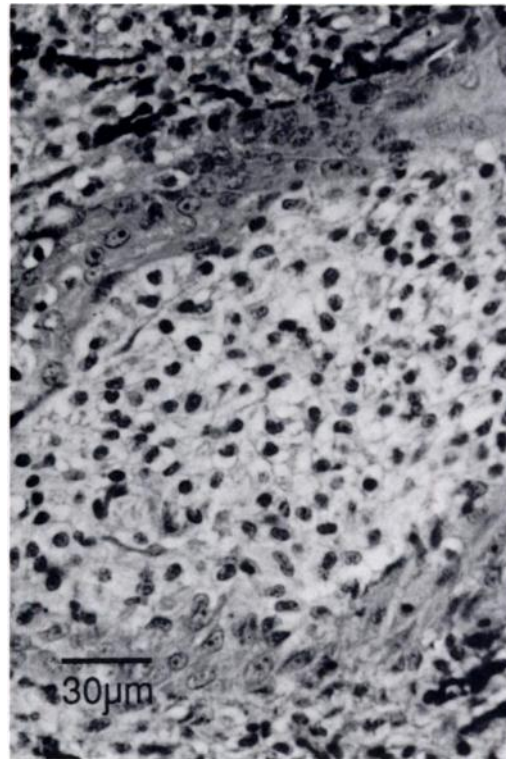


FIGURE 4. Juvenile *Sceloporus jarrovi*. Granuloma predominantly consisting of histiocytes with foamy cytoplasm. H&E.

irregular epithelial hyperplasia (Fig. 3) with multiple dermal confluent granulomas were observed. Granulomas contained histiocytes with foamy and often vacuolated cytoplasm, as well as heterophils (Fig. 4). The granulomas were surrounded by inner epithelioid cells and outer fibroblasts and probably represent a more advanced host response to isolate the effects of the chigger bites. There were aggregates of histiocytes and lymphocytes beneath the granulomas. Occasional mast cells were noted on Giemsa-stained tissue. The severity of the elicited response was consistent with a hypersensitivity reaction.

The inflammatory response was most severe and diffuse among adult lizards (Fig. 5). It penetrated further inside the dermis where it infiltrated collagenous tissues and often reached into the panniculus. The dermal inflammatory infiltrate again consisted of heterophils and macrophages with

some lymphocytes. The layer of melanophores which normally underlies the epidermis was interrupted and dispersed with many melanophores that migrated deeper into the dermis.

The tissue response to the stylostome consisted of marked epithelial hyperplasia with hyperkeratosis of the squamous epithelium. This epidermal thickening was grossly visible. Mitotic figures were common in the basal layers. Hydropic degeneration and mild edema of the epithelium was noted. Focal ulcerations, indicative of more recent lesions, were present at the epithelial surface in some animals. Older stylostomes were walled off by epithelium and fibroblasts. These stylostomes were invaded by histiocytes and heterophils and eventually were transformed into necrotic proteinaceous masses. Stylostomes were not observed to penetrate the dermis.



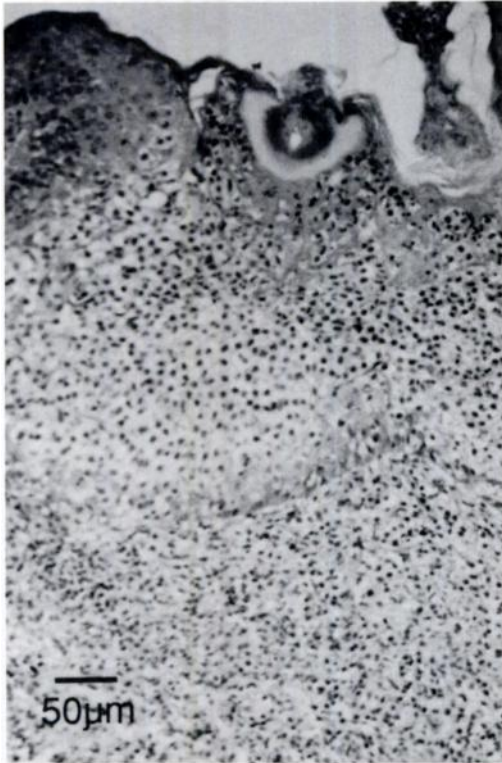


FIGURE 5. Adult *Sceloporus jarrovi*. Severe ulcerative inflammatory reaction in mite pocket. H&E.

Multifocal, nodular dermal granulomas typically were present beneath each stylostome, often reaching into the panniculus. There was a mixture of fully granulated and degranulated heterophils and histiocytes within the granulomas.

With Masson's trichrome stain, moderate collagen deposition within the inflammatory dermal infiltrate was seen. Collagen was not present inside the granulomas. Giemsa-stained sections contained mast cells scattered through inflamed areas. Eosinophils could not be distinguished from other granulocytes.

#### DISCUSSION

Lizards appeared to respond to chigger bites by forming granulomas which were later walled off by epithelioid cells and fibroblasts. Similar granuloma formation was noted in a wild population of the side-blotched lizard, *Uta stansburiana*, when

exposed to chigger and tick bites (Goldberg and Bursey, 1991). However, Goldberg and Bursey (1991) did not observe invasion of the stylostome by inflammatory cells in *U. stansburiana*.

Based on the ectoparasite-induced inflammatory responses in neonates, *S. jarrovi* appears capable of recognizing foreign antigens shortly after birth. This implies immunocompetence, at least by this one criterion. Immunocompetence at birth previously was found in the agamid lizard, *Calotes versicolor* (Kanakambika and Muthukkaruppan, 1972).

However, our finding of an inflammatory response during first exposure in neonatal *S. jarrovi* differs from what has been reported for naive mammals. Wright et al. (1988) found that initial exposure of mice to the chigger, *Eutrombicula cinnabaris* elicited only a slight inflammatory response consisting of a few lymphocytes and eosinophils; after a subsequent (4th) infestation, there was a more severe reaction with many more lymphocytes and eosinophils as well as an increase in basophils and neutrophils. Latif et al. (1990) reported rabbits previously sensitized to ticks (*Amblyomma variagatum* and *Rhipicephalus appendiculatus*) had epidermal vesiculation and eosinophil mobilization when reinfested. This reaction did not occur when tick-naive rabbits were infested for the first time. We have no explanation for the ability of *S. jarrovi*, a natural host for this chigger, to react to ectoparasite infestation on first exposure whereas mammals do not react or react only slightly.

Well-organized granulomas were not seen in neonatal lizards, although we did note the beginnings of lymphocyte aggregations. These lymphocyte masses are consistent with a continuing antigenic reaction. Based on the more severe responses including granulomas in older *S. jarrovi*, we propose there to be an increased host sensitivity following repeated exposure to ectoparasite-injected antigens. Thus, as reported for mammals (Wright et al., 1988; Latif et al., 1990), previous exposures to

ectoparasites appeared positively correlated with intensity of the inflammatory response.

In mammals, marked increases in basophil numbers have been associated with immune responses to ticks; on immune mammals, ticks had a lowered success (Gill and Walker, 1985; Brown et al., 1984; Brown, 1985). In contrast, we found no substantial qualitative differences in inflammatory cell populations in neonatal, juvenile, and adult *S. jarrovi*. Also, we observed heavy chigger infestations in older lizards previously infested with *E. lipovskiyana*; thus, *S. jarrovi* may not have developed resistance after repeated exposure. Furthermore, all age groups of *S. jarrovi* were observed to contain chiggers in their mite pockets at every season of the year.

Arnold (1986) suggested that mite pockets evolved in lizards prone to chigger infestations as a way to localize the damage they cause. Thus, it was surprising to see such a severe reaction in these seemingly specialized adaptive sites. Mite pockets are found in at least ten lizard families (Arnold, 1986) and typically occur in close proximity to either the front or hind limbs. While mites were seen on other areas of the *S. jarrovi* integument, their numbers were low when compared to the dense aggregations seen within mite pockets. Thus, our observations would tend to support the hypothesis of Arnold (1986).

#### ACKNOWLEDGMENTS

We thank M. L. Goff, University of Hawaii at Manoa for identification of ectoparasites and P. Firth for assistance with figures.

#### LITERATURE CITED

- ARNOLD, E. N. 1986. Mite pockets of lizards, a possible means of reducing damage by ectoparasites. *Biological Journal of the Linnean Society* 29: 1-21.
- AUFFENBERG, W., AND T. AUFFENBERG. 1990. The reptile tick *Aponomma gervaisi* (Acarina: Ixodidae) as a parasite of monitor lizards in Pakistan and India. *Bulletin of the Florida Museum of Natural History* 35: 1-34.
- BROWN, S. J. 1985. Immunology of acquired resistance to ticks. *Parasitology Today* 1: 166-171.
- , B. G. BAGNALL, AND P. W. ASKENASE. 1984. *Ixodes holocyclus*: Kinetics of cutaneous basophil responses in naive, and actively and passively sensitized guinea pigs. *Experimental Parasitology* 57: 40-47.
- GILL, H. S., AND A. R. WALKER. 1985. Differential cellular responses at *Hyalomma anatolicum anatolicum* feeding sites on susceptible and tick-resistant rabbits. *Parasitology* 91: 591-607.
- GOLDBERG, S. R. 1970. Ovarian cycle of the mountain spiny lizard *Sceloporus jarrovi* Cope. Ph.D. Thesis. University of Arizona, Tucson, Arizona, 115 pp.
- . 1971. Reproductive cycle of the ovoviviparous iguanid lizard *Sceloporus jarrovi* Cope. *Herpetologica* 27: 123-131.
- , AND C. R. BURSEY. 1991. Integumental lesions caused by ectoparasites in a wild population of the side-blotched lizard (*Uta stansburiana*). *Journal of Wildlife Diseases* 27: 68-73.
- KANAKAMBIKA, P., AND VR. MUTHUKARUPPAN. 1972. Immunological competence in the newly hatched lizard, *Calotes versicolor*. *Proceedings of the Society for Experimental Biology and Medicine* 140: 21-23.
- LATIF, A. A., J. N. MAINA, T. S. DHADIALLA, AND S. NOKOE. 1990. Histological reactions to bites of *Amblyomma variagatum* and *Rhipicephalus appendiculatus* (Acari: Ixodidae) fed simultaneously on naive or sensitized rabbits. *Journal of Medical Entomology* 27: 316-323.
- LUNA, L. 1968. *Manual of histologic staining methods of the Armed Forces Institute of Pathology*, 3rd ed. McGraw-Hill Book Company, New York, New York, 258 pp.
- MONTALI, R. J. 1988. Comparative pathology of inflammation in the higher vertebrates (reptiles, birds and mammals). *Journal of Comparative Pathology* 99: 1-26.
- WRIGHT, S. M., S. K. WIKEL, W. J. WRENN. 1988. Host immune responsiveness to the chigger, *Eutrombicula cinnabaris*. *Annals of Tropical Medicine and Parasitology* 82: 283-293.

Received for publication 25 November 1991.