



## **MORPHOLOGY, PREVALENCE, AND DISTRIBUTION OF SARCOCYSTIS SPP. IN WHITE-TAILED DEER (ODOCOILEUS VIRGINIANUS) FROM FLORIDA**

Authors: Atkinson, Carter T., Wright, Scott D., Telford, Sam R., McLaughlin, Grace S., Forrester, Donald J., et al.

Source: Journal of Wildlife Diseases, 29(1) : 73-84

Published By: Wildlife Disease Association

URL: <https://doi.org/10.7589/0090-3558-29.1.73>

---

BioOne Complete ([complete.BioOne.org](https://complete.BioOne.org)) is a full-text database of 200 subscribed and open-access titles in the biological, ecological, and environmental sciences published by nonprofit societies, associations, museums, institutions, and presses.

Your use of this PDF, the BioOne Complete website, and all posted and associated content indicates your acceptance of BioOne's Terms of Use, available at [www.bioone.org/terms-of-use](https://www.bioone.org/terms-of-use).

Usage of BioOne Complete content is strictly limited to personal, educational, and non - commercial use. Commercial inquiries or rights and permissions requests should be directed to the individual publisher as copyright holder.

---

BioOne sees sustainable scholarly publishing as an inherently collaborative enterprise connecting authors, nonprofit publishers, academic institutions, research libraries, and research funders in the common goal of maximizing access to critical research.

## MORPHOLOGY, PREVALENCE, AND DISTRIBUTION OF *SARCOCYSTIS* SPP. IN WHITE-TAILED DEER (*ODOCOILEUS VIRGINIANUS*) FROM FLORIDA

Carter T. Atkinson,<sup>1</sup> Scott D. Wright,<sup>2</sup> Sam R. Telford, Jr.,<sup>2</sup> Grace S. McLaughlin,<sup>2,3</sup>  
Donald J. Forrester,<sup>2</sup> Melody E. Roelke,<sup>2</sup> and James W. McCown<sup>4</sup>

<sup>1</sup> National Wildlife Health Research Center, Hawaii Volcanoes Field Station, P.O. Box 218, Hawaii Volcanoes National Park, Hawaii 96718, USA

<sup>2</sup> Department of Infectious Diseases, College of Veterinary Medicine, University of Florida, Gainesville, Florida 32610, USA

<sup>3</sup> Department of Wildlife and Range Sciences, School of Forest Resources and Conservation, University of Florida, Gainesville, Florida 32610, USA

<sup>4</sup> Florida Game and Fresh Water Fish Commission, 566 Commercial Boulevard, Naples, Florida 33942, USA

**ABSTRACT:** Three morphologically distinct types of sarcocysts (I, II, and III) were identified by light microscopy in tongues from 403 white-tailed deer (*Odocoileus virginianus*) collected in Florida (USA) over a 7-yr-period. Based on electron microscopy of representative examples of these sarcocysts, there were four distinctive wall structures. We concluded that one of these (Type I) was representative of *Sarcocystis odocoileocanis* and another (Type III) was representative of an unnamed species previously described from white-tailed deer in Montana. Type II could be divided further into two forms (IIA and IIB) that may represent two undescribed species or developmental stages of the same species. *Sarcocystis odoi*, another previously recognized sarcosporidian from white-tailed deer, was not found. Sarcocysts of Types I and II were distributed nonrandomly in tongue muscle, being more common in the basal portion, whereas Type III was distributed randomly throughout the tongue. Single infections (one of the three types) accounted for 63% of the infected deer, while double infections occurred in 28% and triple infections in 4%. Types I and II were found in deer throughout the state, but Type III occurred only in deer from southern Florida. In 1988 and 89, the statewide prevalences for Types I, II, and III were 57, 20, and 6%, respectively. Prevalences of Type I ranged from 94% in the panhandle region (northern Florida) to 34% in the southern part of the state. Prevalences of all three types increased with age.

**Key words:** White-tailed deer, *Odocoileus virginianus*, *Sarcocystis odocoileocanis*, *Sarcocystis* spp., morphology, prevalence, distribution, Florida.

### INTRODUCTION

Species of *Sarcocystis* are coccidian parasites that infect a variety of mammals, birds, and cold-blooded vertebrates (Dubey et al., 1989). Two named (*S. odocoileocanis* and *S. odoi*) and one unnamed species have been described in white-tailed deer from North America (Crum et al., 1981; Dubey and Lozier, 1983). Surveys of this host have resulted in the identification of high prevalences of infection throughout North America, but few studies have been conducted on the ultrastructure of the sarcocyst wall to distinguish individual species (Pond and Speer, 1979; Mahrt and Colwell, 1980; Crum and Prestwood, 1982; Dubey and Lozier, 1983). In this study, we document the ultrastructural morphology, prevalences, and distri-

bution of *Sarcocystis* spp. in a sample of white-tailed deer from Florida.

### MATERIALS AND METHODS

The study consisted of two phases. The first phase was an intensive 7-yr study conducted in southern Florida (USA) from 1984 to 1990. The second was a statewide survey in which deer were sampled throughout Florida during 1988 and 1989 (Fig. 1).

In the first phase, 307 deer were collected from seven locations within Collier (26°00'N, 81°20'W), Monroe (25°45'N, 81°00'W), and Dade (25°27'N, 80°47'W) counties in southern Florida (Sites 9 to 11, Fig. 1). Sites in Collier County included land owned by Collier Enterprises (CE), the Florida Panther National Wildlife Refuge (FPNWR), Fakahatchee Strand State Preserve (FSSP), and the Bear Island (BIU) and Corn Dance Units (CDU) of the Big Cypress National Preserve (BCNP). The Stairsteps Unit (SSU) of BCNP in Collier and Monroe counties and Ev-

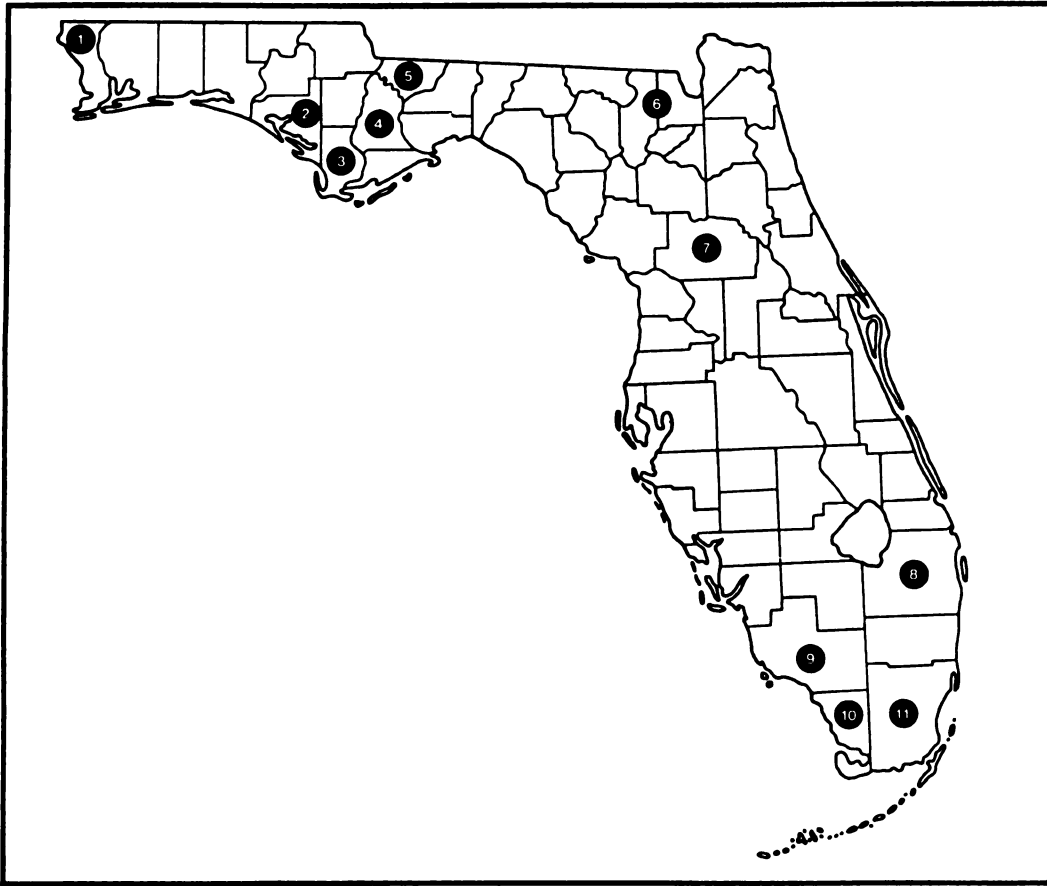


FIGURE 1. Distribution of white-tailed deer samples collected in Florida from 1984 to 1990: (1) Escambia County (30°42'N, 87°24'W),  $n = 10$ ; (2) Bay County (30°18'N, 85°36'W),  $n = 5$ ; (3) Gulf County (30°00'N, 85°16'W),  $n = 5$ ; (4) Calhoun County (30°17'N, 84°56'W),  $n = 5$ ; (5) Gadsden County (30°35'N, 84°40'W),  $n = 7$ ; (6) Osceola National Forest (Columbia and Baker Counties) (30°21'N, 82°28'W),  $n = 18$ ; (7) Marion County (29°10'N, 81°48'W),  $n = 26$ ; (8) Palm Beach County (26°34'N, 80°34'W),  $n = 20$ ; (9) Collier County (26°00'N, 81°20'W),  $n = 280$ ; (10) Monroe County (25°45'N, 81°00'W),  $n = 15$ ; (11) Dade County (25°27'N, 80°47'W),  $n = 12$ .

Everglades National Park (ENP) in Monroe and Dade counties were also included.

The SSU and ENP are sawgrass habitats in the Everglades physiographic region. The other sites include various mosaics of cypress swamps, hardwood hammocks, pine-oak forests, saw palmetto-wiregrass prairies, freshwater marshes and agricultural lands in the Big Cypress physiographic region. Detailed descriptions of these areas have been provided by Davis (1943), Duever et al. (1986), and McPherson (1973).

Deer were collected in August, October, March, and June from August 1984 to June 1986 at BIU and CDU. Subsequently, through 1990, deer were collected annually during October and November beginning in 1986 for BIU and FSSP, and in 1987 for CDU, CE, and FPNWR.

Samples were taken in SSU and ENP in October of 1988 and 1989. A sampling bias was created due to preference for collecting adult does for other objectives of the study. However, the collections were supplemented with hunter-killed bucks taken primarily from BIU and FPNWR. A sample of 241 does and 66 bucks, which consisted of 56 fawns (<13 mo of age), 79 subadults (13 to 24 mo), and 172 adults (>24 mo), was examined. Ages were determined by the patterns of toothwear and replacement in the lower jaw (Harlow and DeFoor, 1962).

From 1984 to 1987 sections were taken only from the distal third of deer tongues. In 1988, tissues from the distal, medial, and basal portions of the tongues were examined from 10 randomly selected deer to determine if the dis-

tribution of sarcocysts was nonrandom; in the remainder of the deer, a sample was taken only from the basal portion. In 1989, only the basal portion was examined, while in 1990 sections were taken from the basal, medial, and distal thirds of the tongue for all 40 deer collected. Tissues were fixed in 10% neutral buffered formalin, embedded in paraffin, sectioned at 6  $\mu\text{m}$ , and stained with hematoxylin and eosin (H&E) for examination by light microscopy.

Twenty-two sarcocysts from 10 different deer from southern Florida were examined by transmission electron microscopy (TEM). Both light microscopy and TEM were done to correlate morphology by light microscopy with structures seen by TEM. Formalin-fixed sarcocysts were located on the cut surface of paraffin-embedded blocks by using the corresponding H&E-stained slide as a guide. Small (5 mm) cubes of tissue containing the sarcocysts were trimmed from the surface of the paraffin blocks with a sharp razor blade, deparaffinized with xylene, rehydrated, fixed with osmium and glutaraldehyde, dehydrated, and embedded in Spurr's epoxy resin as described by Greiner et al. (1989). As fixation of sarcocysts processed by this procedure was poor, frozen tongues were thawed at 20 to 24 C and processed for TEM. A 1-cm thick section of the basal portion of each tongue was cut into 0.5 cm thick slabs with a sharp razor blade. One half of each slab was fixed in 10% neutral buffered formalin, embedded in paraffin, sectioned at 6  $\mu\text{m}$ , and stained with H&E. The corresponding slab of tissue was fixed and stored at 4 C in a solution of 2% paraformaldehyde and 2.5% glutaraldehyde in 0.1 M cacodylate buffer, pH 7.4, with 4% sucrose. Areas containing large numbers of sarcocysts were identified on paraffin sections stained with H&E. Corresponding areas on the cut face of the paraformaldehyde-glutaraldehyde-fixed tissue were identified under a dissecting microscope and 5 mm cubes of tissue were trimmed from the surface of the slabs with a sharp razor blade. These blocks were washed with 0.1 M cacodylate buffer (pH 7.4) and post-fixed with 1% osmium tetroxide in 0.1 M cacodylate buffer (pH 7.4) with 4% sucrose. The tissue was rinsed subsequently with distilled water, stained en bloc with 1% aqueous uranyl acetate, dehydrated with ethanol, and infiltrated and embedded in Spurr's epoxy resin. Thick sections were cut with glass knives to locate sarcocysts. Ultrathin sections were then cut with a diamond knife (Diatome Inc., Ft. Washington, Pennsylvania, USA), mounted on nickel grids, and stained with 2% uranyl acetate in 50% methanol and Reynolds' lead citrate (Reynolds, 1963). The sections were coated lightly with carbon in a vacuum evaporator (Hayat, 1981) and examined with a JEOL

100CX electron microscope (JEOL Limited, Tokyo, Japan).

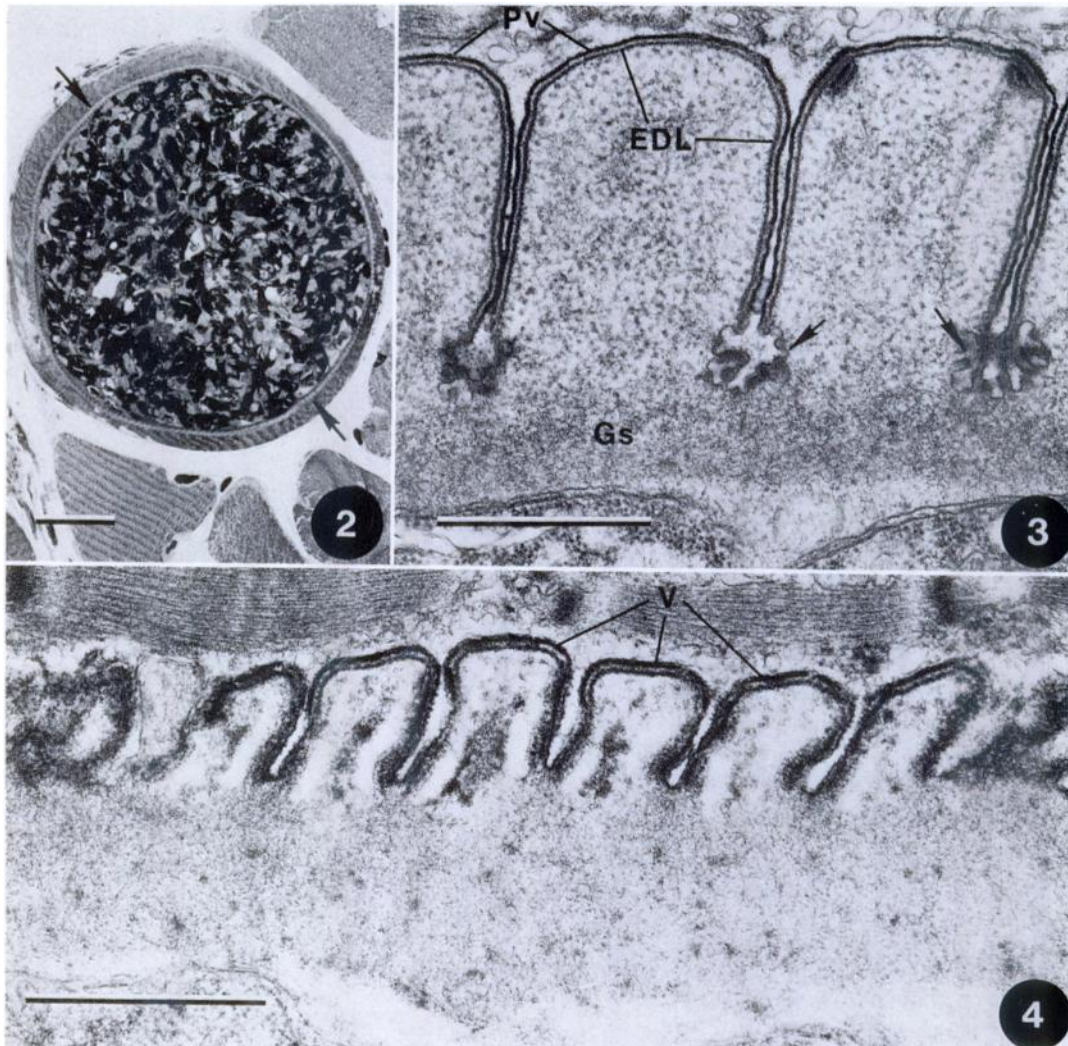
In the second phase, tongues from 96 deer were collected and frozen at check stations at eight sites in three areas (Sites 1 to 8, Fig. 1) during the 1988 to 89 deer hunting season (October to January) to determine the geographic range of morphological types of sarcocysts in Florida. Sites 1 to 5 were in the panhandle region (PH), sites 6 and 7 in the north central region (NC), and site 8 in the southern region. Later, the tongues were thawed and complete transverse sections from the basal portions were fixed in 10% neutral buffered formalin or paraformaldehyde-glutaraldehyde as described above for light microscopy or TEM. A total of 21 sarcocysts from four deer from PH ( $n = 6$  sarcocysts) and NC ( $n = 15$  sarcocysts) was examined by TEM. Data obtained by light microscopy were analyzed with those collected in 1988 from the other southern sites (9 to 11) to examine regional differences.

The Statistical Analysis System (SAS Institute, 1988) was used for data analysis. Prevalence data were compared using Fisher's exact test for sampling methodology, sex, and locality and Kendall's Tau-b test for age. The Chi-square test was used to assess the distribution of sarcocyst types within the tongue. Significance means a statistical significance of  $P \leq 0.05$ . Paraffin blocks containing representative sarcocysts have been deposited in the Registry of Comparative Pathology, Armed Forces Institute of Pathology, Washington, D.C. 20306, USA (Accession No. 2180034).

## RESULTS

### Morphology

Three different morphological types could be distinguished by light microscopy in H&E stained paraffin sections. Type I sarcocysts averaged 88.3  $\mu\text{m}$  in cross section (range = 57 to 147  $\mu\text{m}$ ;  $n = 27$ ) and 81.2  $\mu\text{m}$  (range = 43 to 170  $\mu\text{m}$ ;  $n = 38$ ) along the short axis of oblique sections. One apparently complete longitudinal section measured 1,449  $\times$  163  $\mu\text{m}$ . Septae were distinguishable in more than half of the sarcocysts measured. Sarcocysts lacking discernible septae by light microscopy had slightly smaller dimensions. Based on ultrastructural examination, twelve Type I sarcocysts had morphological characteristics identical to those of *S. odocoileocanis*. The sarcocyst walls were composed of



FIGURES 2 to 4. Light and electron micrographs of *Sarcocystis odocoileocanis* (Figs. 2, 3) and an unidentified *S. odocoileocanis*-like sarcocyst from the tongue of a white-tailed deer collected in the Florida Panhandle (Fig. 4). Figure 2. 1  $\mu\text{m}$  thick section of resin-embedded tongue that was stained with methylene blue-borax. Sarcocyst has a very thin striated wall (arrows). Bar = 25  $\mu\text{m}$ . Figure 3. Ultrathin section of the sarcocyst wall. Short, broad villi of the sarcocyst wall are bounded by a parasitophorous vacuole membrane (Pv) and an underlying electron-dense layer (EDL). Convoluted invaginations of the Pv at the base of villi (arrows) are characteristic of *S. odocoileocanis*. Villi contain granular material that merges gradually with the ground substance (Gs) of the cyst wall. Bar = 1  $\mu\text{m}$ . Figure 4. Ultrathin section of an *S. odocoileocanis*-like sarcocyst. Villi (V) are smaller, more numerous, and lack convoluted invaginations at their bases. Morphological similarities with *S. odocoileocanis*, i.e., villar shape and presence of an electron dense layer, suggest that it may be a younger form of the same species. Bar = 1  $\mu\text{m}$ .

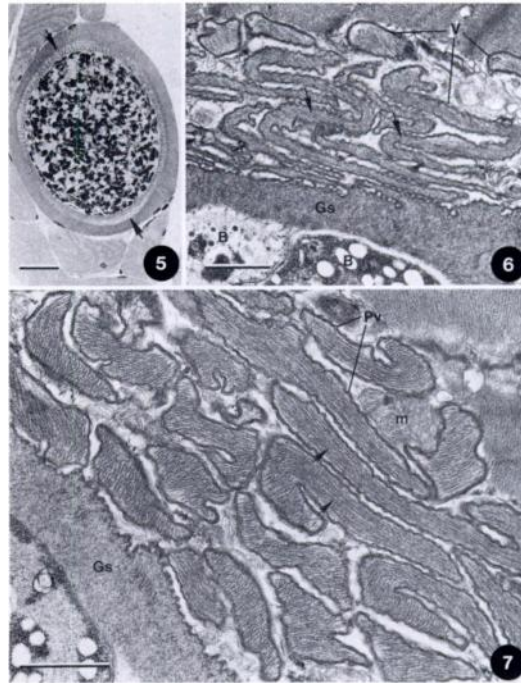
evenly spaced striations (Fig. 2) and averaged 2.04  $\mu\text{m}$  in thickness (range = 1.4 to 2.65  $\mu\text{m}$ ;  $n = 25$  measurements from five sarcocysts) in ultrathin sections with short, broad villi bounded by a parasitophorous vacuole membrane (Pv) and an un-

derlying electron-dense layer (Fig. 3). Villi contained fine to coarse granular material merging gradually with the ground substance of the cyst wall. At the base of villi, the Pv formed shallow convoluted invaginations in the ground substance (Gs),



which is characteristic of this species (Dubey and Lozier, 1983; Entzeroth et al., 1982). One deer collected from the panhandle area of northern Florida had numerous sarcocysts with a wall morphology similar to that of *S. odocoileocanis*, suggesting they may be immature forms of this species (Fig. 4). These sarcocysts contained mature bradyzoites, but had thinner walls, villi that were shorter and narrower than other examples of *S. odocoileocanis*, and lacked convoluted invaginations of the Pv between villi.

Type II sarcocysts had mean diameters of 77.6  $\mu\text{m}$  (range = 47 to 121  $\mu\text{m}$ ;  $n = 23$ ) in cross sections, averaging 71.4  $\mu\text{m}$  (range = 59 to 80  $\mu\text{m}$ ;  $n = 10$ ) along the short axis of oblique sections. Sarcocysts that lacked discernible septae by light microscopy had smaller dimensions. The walls of Type II sarcocysts were approximately twice as thick as that of Type I cysts and were composed of narrow, irregularly spaced striations that, by light microscopy, occasionally appeared to have two or three separate layers (Fig. 5). However, a single layer, which had appeared more complex due to orientation of the tissue, was seen when correlative electron microscopy was performed on these sarcocysts. Using ultrastructural examination, 25 Type II sarcocysts had two structurally similar forms indistinguishable by light microscopy. Type IIA sarcocyst walls averaged 3.56  $\mu\text{m}$  (range = 2.7 to 4.59  $\mu\text{m}$ ,  $n = 15$  measurements from four sarcocysts) with ground substance averaging 0.66  $\mu\text{m}$  in thickness (range = 0.38 to 0.86  $\mu\text{m}$ ,  $n = 25$  measurements from four cysts) (Figs. 5, 6). Numerous narrow villar protrusions averaging 0.30  $\mu\text{m}$  in diameter (range = 0.16 to 0.58  $\mu\text{m}$ ,  $n = 25$  measurements from four cysts) were often curved, folded, and twisted around one another and adjacent host cell mitochondria (Figs. 6, 7). Villi were bounded by a thickened undulating Pv and filled with densely packed, coarsely striated filaments originating in the ground substance of the cyst wall and extending to the ends of the protrusions (Fig. 7). The



FIGURES 5 TO 7. Light and electron micrographs of Type IIA sarcocysts from tongues of white-tailed deer in Florida. Figure 5. 1  $\mu\text{m}$  thick section of resin-embedded tongue that was stained with methylene blue-borax. Sarcocyst has a thick striated wall composed of numerous densely-packed narrow protrusions (arrows). Bar = 25  $\mu\text{m}$ . Figure 6. Ultrathin section of the sarcocyst wall. The wall has numerous narrow villi (V) that are bent and folded around one another. The villi are continuous with the ground substance (Gs) of the sarcocyst wall. Note coarsely striated filamentous cores (arrows) of the villi. Bradyzoites (B) are beneath the ground substance of the sarcocyst wall. Bar = 1  $\mu\text{m}$ . Figure 7. Higher magnification of the sarcocyst wall. Note coarsely striated filaments (arrows) within the villi, the undulating parasitophorous vacuole membrane (Pv) that bounds the villi, and the fine granular material of the ground substance (Gs). Host cell mitochondria (m) are often surrounded by villi. Bar = 1  $\mu\text{m}$ .

walls of Type IIB sarcocysts also had numerous narrow villar protrusions, but these were much smaller in diameter ( $\bar{x} = 0.12$   $\mu\text{m}$ , range = 0.04 to 0.26  $\mu\text{m}$ ) and lacked the coarsely striated cores characteristic of Type IIA sarcocysts (Fig. 8). These often had a hair-like appearance and either were apposed closely to the ground substance of the sarcocyst wall or extended away from the wall into the host cell cytoplasm (Fig.

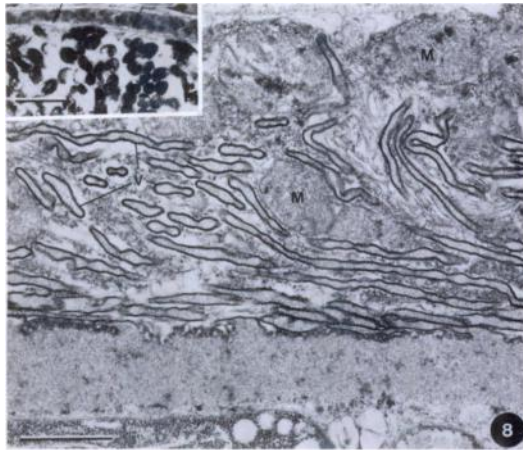
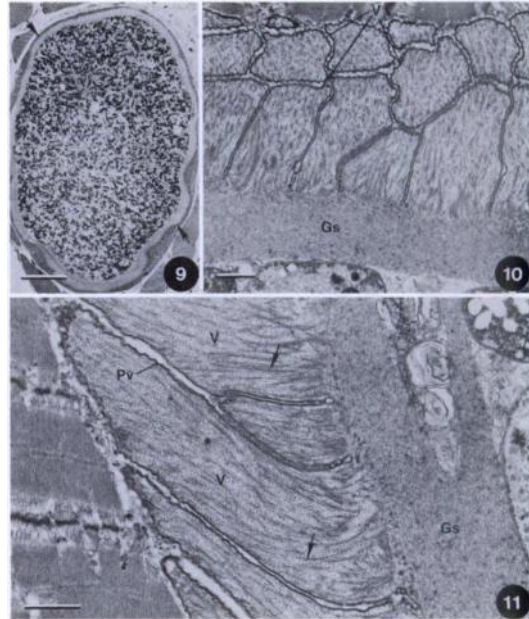


FIGURE 8. Light and electron micrographs of a Type IIB sarcocyst from the tongue of a white-tailed deer in Florida. The wall has numerous hair-like villi (V) that are bent or twisted around each other and adjacent host cell mitochondria (M). The villi lack the coarsely striated cores that are characteristic of Type IIA sarcocysts. Bar = 1  $\mu\text{m}$ . Inset: 1  $\mu\text{m}$  thick section of resin-embedded tongue that was stained with methylene blue-borax. Hair-like villar projections (arrows) of the sarcocyst wall are barely discernible. Bar = 5  $\mu\text{m}$ .

8). The walls of Type IIB sarcocysts were thinner ( $\bar{x} = 2.6 \mu\text{m}$ , range = 0.92 to 5.84  $\mu\text{m}$ ,  $n = 23$  from five sarcocysts) than those of Type IIA, only slightly thicker than Type I sarcocyst walls, and had a ground substance averaging 0.73  $\mu\text{m}$  in thickness (range = 0.35 to 1.62  $\mu\text{m}$ ,  $n = 25$  measurements from five cysts) (Fig. 8).

Type III sarcocysts were larger than Types I or II, averaging 166  $\mu\text{m}$  (range = 117 to 317  $\mu\text{m}$ ;  $n = 6$ ) in cross sections and 111.7  $\mu\text{m}$  (range = 60 to 156  $\mu\text{m}$ ;  $n = 3$ ) along the short axis of oblique sections (Fig. 9). Sarcocysts lacking discernible septae by light microscopy were slightly smaller. The wall of Type III sarcocysts was approximately 7  $\mu\text{m}$  in thickness and composed of coarse, evenly spaced striations (Fig. 9). Based on ultrastructural examination, four Type III sarcocysts (Figs. 10, 11) had characteristics similar to those of an unnamed species of *Sarcocystis* described by Dubey and Lozier (1983) from the esophagus of a white-tailed deer collected in Montana (USA). The cyst wall averaged 6.39  $\mu\text{m}$



FIGURES 9 to 11. Light and electron micrographs of a Type III sarcocyst from the tongue of a white-tailed deer in Florida. Figure 9. 1  $\mu\text{m}$  thick section of resin-embedded tongue that was stained with methylene blue-borax. Sarcocyst has a thick striated wall composed of broad, closely spaced villi (arrows). Bar = 50  $\mu\text{m}$ . Figure 10. Ultrathin tangential section of the sarcocyst wall. Villi (V) are broad and contain a mixture of coarse granular material and filaments. The contents of the villi merge abruptly with the fine granular material of the ground substance (Gs) to form a clear line of demarcation. Bar = 1  $\mu\text{m}$ . Figure 11. Higher magnification of the sarcocyst wall. Villi (V) are broad at their bases where they merge with the ground substance (Gs) and taper toward their tips. Villi are bounded by a thickened parasitophorous vacuole membrane (Pv) and contain coarse granular material and filaments. Note absence of coarse striations in the filaments (arrows). Bar = 1  $\mu\text{m}$ .

thick (range 5.41 to 9.16  $\mu\text{m}$ ,  $n = 23$  measurements from four sarcocysts), with a ground substance averaging 1.46  $\mu\text{m}$  in thickness (range = 0.7 to 2.86  $\mu\text{m}$ ,  $n = 31$  measurements from four sarcocysts). A secondary cyst wall was absent. Villi of this type of sarcocyst averaged 2.09  $\mu\text{m}$  in diameter at their bases (range = 1.67 to 3.0  $\mu\text{m}$ ,  $n = 22$  measurements from four sarcocysts) where they joined the fine granular ground substance and were bounded by a thickened undulating Pv with interdigitating lateral margins (Figs. 10, 11).

TABLE 1. Distribution of sarcocyst type by region of the tongue in 50 white-tailed deer collected in 1988 and 1990 from southern Florida.

Type	Numbers of sarcocysts/section of tongue <sup>a</sup>		
	Basal	Medial	Distal
I	23	9	3
II	16	9	3
III	1	3	4

<sup>a</sup> Determined by light microscopy.

Depending on the plane of section, villi appeared to have broad flattened tips or to taper gradually to narrow points. Villi contained a mixture of coarse granular material and fine filaments clearly distinguished from the fine granular ground substance of the cyst wall. Filaments in the villi were scattered singly or in bundles and lacked coarse striations. None of the sarcocysts examined with TEM in this study resembled *S. odoi*.

#### Prevalence and distribution

Beginning in 1988, sampling methodology was changed to include tissues from the base of the tongue rather than only from the distal third because of the higher prevalence of sarcocysts in that area. Based on samples collected in 1988 ( $n = 10$ ) and 1990 ( $n = 40$ ), Type I sarcocysts occurred more frequently in the basal and less frequently in the distal portions of the tongues than expected ( $\chi^2 = 11.6$ ,  $P < 0.005$ ), as did Type II ( $\chi^2 = 9.1$ ,  $P < 0.025$ ). Type III cysts were distributed randomly; however, few cysts of that type were observed (Table 1). Therefore, data on prevalences by host sex, host age, and locality were analyzed by year-group (1984 to 87 and 1988 to 90) to reflect the change in methodology.

For the 307 deer studied in the first phase, 99 (32%) were positive for at least one type of sarcocyst. There was a highly significant difference ( $P < 0.002$ ) in overall prevalence of *Sarcocystis* spp. between the 162 samples collected in 1984 to 87 (24%) and the 145 collected in 1988 to 90 (41%). For 1984 to 87, Type I prevalence

TABLE 2. Prevalence of sarcocyst types from white-tailed deer in southern Florida by host age group, 1984 to 87 and 1988 to 90.

Sarcocyst type	Age group in months		
	<13	13–24	>24
	1984 to 87		
<i>n</i>	30 <sup>a</sup>	51	81
I	0	6	12
II	0	2	11
III	3	10	12
All types <sup>b</sup>	3	24	32
	1988 to 90		
<i>n</i>	26	28	91
I	4	21	40
II	0	18	27
III	8	11	20
All types <sup>b</sup>	8	32	54

<sup>a</sup> Number of deer in this age group.

<sup>b</sup> These values include sarcocysts which could not be assigned to Types I, II, or III.

was 8%, significantly lower than the 30% for 1988 to 90 ( $P < 0.001$ ). For Type II, 1984 to 87 prevalence was 6%; the 1988 to 90 prevalence was significantly greater at 20% ( $P < 0.001$ ). Type III prevalences did not differ significantly by year (10 vs. 16%). Of the 99 positive deer, 55 had only one identifiable type of sarcocyst (Type I: 23; Type II: 18; Type III: 14), 29 had two identifiable types (Types I and III: 13; Types I and II: 12; Types II and III: 4), seven were infected with all three types, and eight were infected only with sarcocysts unidentifiable as to type.

There were no significant differences between females and males for all types of sarcocysts collectively, nor for any of the three types individually, within either year-group.

For analysis of prevalence by host age, the southern sample was divided into three groups by estimated age in months (Table 2). Based on an analysis of the 1984 to 87 data, there were significant increases with age for prevalence of all sarcocyst types combined (3 to 32%,  $P < 0.0002$ ), of Type I (0 to 12%,  $P < 0.001$ ), of Type II (0 to 11%,  $P < 0.0001$ ), but not of Type III. Based on an analysis of the 1988 to 90 data,



TABLE 3. Prevalence of sarcocyst types identified by light microscopy in white-tailed deer from localities throughout Florida, 1988 to 89.

Area	Number of deer			Prevalence (%) by sarcocyst type		
	Examined	Positive	% Positive	I	II	III
Panhandle (1 to 5)*	32	30	94	94	9	0
North Central (6 and 7)	44	30	68	68	32	0
So. Florida (8 to 11)	74	43	58	34	18	12
Totals (1 to 11)	150	103	69	57	20	6

\* Numbers in parentheses refer to sites in Figure 1.

there were similar increases for all types combined (8 to 54%,  $P < 0.0001$ ), for Type I (4 to 40%,  $P < 0.0001$ ), for Type II (0 to 26%,  $P < 0.0001$ ), and also for Type III (8 to 20%,  $P < 0.025$ ).

Sarcocyst prevalence was examined for two physiographic regions (Big Cypress and Everglades) in the three southern counties (Sites 9 to 11, Fig. 1). The only significant difference among regions was the low prevalence in deer from the Everglades (ENP and SSU) (4 vs. 35%,  $P < 0.005$ ). There were no significant differences among the five Big Cypress sites.

For the second phase, tissues were collected in 1988 and 89 from 74 deer at southern sites (8 to 11, Fig. 1) and from 76 deer at seven northern sites (1 to 7, Fig. 1). These were examined by light and electron microscopy to determine the geographic distribution of different types of sarcocysts (Table 3). Using light microscopic examination of tissues, we observed the presence of Types I and II in deer throughout the state, but Type III only from southern Florida. Using electron microscopy, we observed Type I sarcocysts in deer from all areas. Type IIA sarcocysts were observed in tissues collected in the panhandle (PH, Sites 1 to 5) and southern Florida (SF, Sites 8 to 11), while Type IIB sarcocysts were found only in tissues collected in the north central region (NC, Sites 6 and 7). Type III sarcocysts were detected only by light microscopy.

There were no differences in prevalence by locality among the SF sites for 1988, so these data were combined. Deer taken in PH had an overall sarcocyst prevalence of

94%, significantly higher than the 68% in NC ( $P < 0.02$ ), and the 58% in SF ( $P < 0.001$ ). There was no significant difference among deer between NC and SF. Type I prevalences and significances were the same as the overall values for PH and NC, but much lower for SF (34%). The difference between NC and SF was significant ( $P < 0.001$ ) for Type I. Type II prevalence was lower in PH than in NC (9 vs. 32%,  $P < 0.05$ ), but neither differed from the prevalence in SF (18%). Type III prevalence was greater in SF than in PH and NC (12 vs. 0%,  $P < 0.05$ ). In PH, 27 deer were infected with only Type I, while three deer carried both Types I and II. In NC, 16 deer had only Type I, and 14 were infected with both Types I and II sarcocysts. For SF, 13 deer had only one identifiable type (Type I: 8; Type II: 4; Type III: 1), six had two types (Types I and III: 4; Types I and II: 1; Types II and III: 1), and three deer had all three types of sarcocysts.

In SF there were no differences in prevalences between sexes for all types collectively nor for any of the three types individually, even though no males ( $n = 15$ ) were infected with Type III sarcocysts (female  $n = 51$ , 16%;  $P < 0.08$ ). However, in the north, females ( $n = 36$ ) showed greater prevalences than males ( $n = 34$ ) for all types combined and for Type I (97 vs. 59%,  $P < 0.001$ ). The NC deer (female  $n = 13$ , male  $n = 26$ ) mirrored those values (92 vs. 54%,  $P < 0.03$ ). Although the PH females ( $n = 23$ ) also had higher prevalences than males ( $n = 8$ ) overall and of Type I sarcocysts, these were not quite

significant (100 vs. 75%,  $P < 0.06$ ). This may have been due to a sampling artifact. Females from NC and PH did not differ from each other, but had higher prevalences than SF females overall (97 vs. 56%,  $P < 0.001$ ) and of Type I sarcocysts (97 vs. 29%,  $P < 0.001$ ), while SF females had a higher prevalence of Type III (18 vs. 0%,  $P < 0.03$ ). For Type II, 42% of NC males were infected, compared to none in PH ( $P < 0.03$ ). Females did not have a similar difference (NC: 23%; PH: 13%).

### DISCUSSION

Previous surveys of white-tailed deer in North America have been based primarily on light microscopy to identify species or describe morphological types based on characteristics of the sarcocyst wall. We initially attempted to classify sarcocysts at the light microscopic level by wall thickness and morphology, but in studies with TEM, we found a more diverse range of wall structures than could be resolved with the light microscope alone. We identified four types of sarcocysts by electron microscopy, which may represent three or possibly four separate species of *Sarcocystis*.

Type I sarcocysts were identical in morphology to sarcocysts formed by *S. odocoileocanis* and had convolutions in the Pv at the bases of villi characteristic of this species (Entzeroth et al., 1982). They also were ultrastructurally similar to the sarcocysts of *S. hemionilatrantis* from mule deer (*Odocoileus hemionus*) (Dubey and Speer, 1986). Sarcocysts from a deer collected in the Florida Panhandle were similar to *S. odocoileocanis* in the general shape of villi, suggesting that they may be immature forms of that species. Merozoites were not observed, however, leaving the possibility that these may be mature sarcocysts of another undescribed species.

The walls of Type IIA appear to represent a new morphological type (Dubey et al., 1989). Both Type IIA and Type IIB sarcocysts were unlike any previously reported from North American cervids and

may represent new species. Villi of these sarcocysts were longer and narrower than *S. odoi* and more similar in morphology to *S. arieticanis* of sheep (Dubey et al., 1988). Wall thickness varied considerably by light microscopy, depending on whether villi extended into the host cell cytoplasm away from the sarcocyst wall or were flattened around its periphery. Final determination of the taxonomic status of these two types will depend on experimental studies to identify the definitive hosts and to determine whether morphological changes occur in the sarcocyst wall during development of the parasites. Dramatic changes in wall structure during maturation of some species of *Sarcocystis* have been documented (Mehlhorn et al., 1976; Dubey et al., 1983; Munday and Obendorf, 1984), raising the possibility that the walls of Type IIA and Type IIB sarcocysts are different chronological forms of the same species.

Type III sarcocysts found in our study were similar to an unnamed species reported by Dubey and Lozier (1983) from white-tailed deer in Montana and were structurally similar to sarcocysts of *S. youngi* from mule deer in Montana (Dubey and Speer, 1986). Based on our data, the range of this unnamed species is extended to include Florida. *Sarcocystis odoi* was described from white-tailed deer in areas with sympatric populations of mule deer and their morphologically similar species, *S. hemioni* (Dubey and Speer, 1985, 1986). Because of the apparent absence of *S. odoi* in our study, this species may require a definitive host or ecological conditions not found in Florida.

*Sarcocystis* infections in white-tailed deer in North America are common, with prevalences ranging from 44 to 88% (Lindsay et al., 1988). The prevalence in Florida is probably higher than our estimates indicate because we did not use more sensitive digestion techniques. The apparent preference of Type I (*S. odocoileocanis*) and Type II sarcocysts for basal regions of the tongue also created a sampling bias

that led us to underestimate prevalences overall and for those two types during the early years of the study. As only the basal portion of the tongue was collected for most of the 1988 sample and all of the 1989 sample, Type III prevalence may have been underestimated for those years. Previous workers have demonstrated the value of tongue tissue for detecting infection with *Sarcocystis* by histological section, but the procedure has not been refined to examine the distribution of individual species within this organ (Karstad and Trainer, 1969; Mahrt and Colwell, 1980; Crum and Prestwood, 1982; Dubey et al., 1988). From our work, it seems clear that different types of sarcocysts develop preferentially in different regions of the tongue, although the mechanisms responsible for this nonrandom distribution are unknown. Standardized sampling techniques are important for comparing prevalences among different geographic areas, age classes, and studies.

Crum and Prestwood (1982) found significantly higher prevalences of *Sarcocystis* spp. in adult deer (45%) than in fawns (26%), but did not find differences in prevalence among different physiographic provinces or between sexes. We found similar increases in prevalence during the first two years of life for *S. odocoileocanis* and Type II sarcocysts, which are consistent with transmission by continual exposure to contaminated forage. However, we also found differences in prevalences between the sexes, for different regions of the state, and for different physiographic provinces within a region. The differences between sexes may be based on differential use of macro- or micro-habitats within regions, and need to be explored further.

There are several possible explanations for the geographic differences. Prestwood and Smith (1969) reported that deer in Collier County originated from deer transplanted from Wisconsin (USA) in 1948 after the native deer were exterminated during a cattle fever tick eradication program

in the 1930's. As Type III sarcocysts were found only in that area, they may have been introduced from Wisconsin. If deer from Wisconsin also were relocated to the PH, Type IIA sarcocysts may have come in with them. But if Type III originated in Wisconsin, it should tolerate environmental conditions in northern as well as southern Florida. Therefore, it is possible that Type III is endemic to SF, and cannot withstand conditions further north. Alternatively, O'Brien et al. (1990) presented strong evidence for a recent (<50 years ago) introduction of Latin American pumas into SF, and this could have been the route for introduction of Type III sarcocysts. The reason why Type IIA was found in PH and SF and Type IIB was found only in NC is not clear, and the possibility that both types are the same species needs investigation. The almost total lack of sarcocysts in deer collected in the sawgrass habitats (ENP and SSU) may be due to inhospitable environmental conditions in that specific habitat.

The definitive host of *S. odocoileocanis* is the domestic dog (*Canis familiaris*) (Crum et al., 1981). Emmett (1986) demonstrated sporocysts of *Sarcocystis* spp. in the scats of experimentally infected timber wolves (*Canis lupus*) and from free-ranging wolves in northeastern Minnesota (USA). Because wolves are the primary predator of deer in northeastern Minnesota, Emmett (1986) suggested that they were a likely natural definitive host of *Sarcocystis* spp. In Florida, feral dogs, coyotes (*Canis latrans*), and gray foxes (*Urocyon cinereoargenteus*) may serve as definitive hosts of *S. odocoileocanis*. Many parts of Florida have a history of dog use for hunting, which may have played a part in disseminating *S. odocoileocanis* throughout the state.

Dubey and Lozier (1983) reported that felids, specifically the domestic cat (*Felis catus*), were definitive hosts for *S. odoi*, although their experiment did not rule out possible contamination with the thick-

walled sarcocysts similar to the Type III parasites we found. Significantly, Crum and Prestwood (1982) detected a species of *Sarcocystis* infective to cats and different from *S. odocoileocanis*, but the sarcocysts were not described. Thus, there is circumstantial evidence that felids may be definitive hosts for the Type III parasites in our study, but this will need to be established by experimental studies. In addition to domestic cats, including feral cats, there are two species of wild felids living in Florida, the Florida panther (*Felis concolor coryi*) and the bobcat (*Felis rufus*). Both species prey on white-tailed deer (Maehr and Brady, 1986; Maehr et al., 1990).

Assuming that environmental conditions necessary for survival of infective sporocysts are similar among different species of *Sarcocystis*, the prevalence of each *Sarcocystis* sp. should remain constant within a physiographic region if all are cycling through the same definitive hosts, or if the hosts have similar densities and distributions. Emmett and Huggins (1982) noted a positive correlation between density of the definitive host and prevalence of infection in white-tailed deer from South Dakota (USA). We failed to find significant changes in the prevalences of any type of sarcocysts at different study sites in the Big Cypress region, suggesting that all types may cycle through hosts which have wide distributions and relatively uniform densities in that area. The differences in prevalences among PH, NC, and SF may be related to densities of canids and felids in those areas.

Crum et al. (1981) infected deer experimentally with *S. odocoileocanis* and observed inflammation in association with apparently intact sarcocysts. In the present study, host inflammatory responses were not observed in tongue tissue in association with the sarcocysts. While we did not find any direct evidence implicating sarcocystosis as a limiting factor in deer populations in southern Florida, its potential im-

pact on predator-prey cycles, particularly those involving the endangered Florida panther, should be studied further in greater detail.

#### ACKNOWLEDGMENTS

The assistance of J. C. Roboski, D. S. Maehr, J. C. Roof, E. D. Land, S. M. Shea, M. C. Conner, T. W. Regan, and M. B. Brooks of the Florida Game and Fresh Water Fish Commission and O. L. Bass, C. H. Davis, D. K. Jansen, T. R. Smith, J. R. Snyder, and M. E. Spier of the National Park Service in the collection of deer was appreciated. The technical assistance of G. W. Foster, S. J. Tucker, J. H. Bogue, S. A. Ross, K. D. Luc, and A. Milosavljevic also was appreciated. R. C. Littell assisted with the statistical analyses. We thank J. P. Dubey for suggestions and advice on several aspects of this study and C. H. Courtney, E. C. Greiner, and M. D. Young for reading earlier drafts of the manuscript. This research was supported by contracts from the U. S. National Park Service and the Florida Game and Fresh Water Fish Commission and is a contribution of Federal Aid to Wildlife Restoration, Florida Pittman-Robertson Project W-41. Florida Agricultural Experimental Stations Journal Series No. R-01876.

#### LITERATURE CITED

- CRUM, J. M., AND A. K. PRESTWOOD. 1982. Prevalence and distribution of *Sarcocystis* spp. among white-tailed deer of the southeastern United States. *Journal of Wildlife Diseases* 18: 195-203.
- , R. FAYER, AND A. K. PRESTWOOD. 1981. *Sarcocystis* spp. in white-tailed deer. I. Definitive and intermediate host spectrum with a description of *Sarcocystis odocoileocanis* n. sp. *Journal of Wildlife Diseases* 17: 567-579.
- DAVIS, J. H. 1943. Natural features of southern Florida. Florida Geological Survey Bulletin 25. Tallahassee, Florida, 311 pp.
- DUBEY, J. P., AND S. M. LOZIER. 1983. *Sarcocystis* infection in the white-tailed deer (*Odocoileus virginianus*) in Montana: Intensity and description of *Sarcocystis odoi* n.sp. *American Journal of Veterinary Research* 44: 1738-1743.
- , AND C. A. SPEER. 1985. Prevalence and ultrastructure of three types of *Sarcocystis* in mule deer, *Odocoileus hemionus* (Rafinesque), in Montana. *Journal of Wildlife Diseases* 21: 219-228.
- , AND ———. 1986. *Sarcocystis* infections in mule deer (*Odocoileus hemionus*) in Montana and the descriptions of three new species. *American Journal of Veterinary Research* 47: 1052-1055.



- , W. R. JOLLEY, AND E. T. THORNE. 1983. *Sarcocystis sybillensis* sp.nov. from the North American elk (*Cervus elaphus*). Canadian Journal of Zoology 61: 737-742.
- , D. S. LINDSAY, C. A. SPEER, R. FAYER, AND C. W. LIVINGSTON, JR. 1988. *Sarcocystis arietianis* and other *Sarcocystis* species in sheep in the United States. The Journal of Parasitology 74: 1033-1038.
- , C. A. SPEER, AND R. FAYER. 1989. *Sarcocystis* of animals and man. CRC Press, Boca Raton, Florida, 215 pp.
- DUEVER, M. J., J. E. CARLSON, J. F. MEEDER, L. C. DUEVER, L. H. GUNDERSON, L. A. RIOPELLE, T. R. ALEXANDER, B. L. MYERS, AND D. P. SPANGLER. 1986. The Big Cypress National Preserve. Research Reprint #8. National Audubon Society, New York, New York, 455 pp.
- EMNETT, C. W. 1986. Prevalence of *Sarcocystis* in wolves and white-tailed deer in northeastern Minnesota. Journal of Wildlife Diseases 22: 193-195.
- , AND E. J. HUGHGINS. 1982. *Sarcocystis* of deer in South Dakota. Journal of Wildlife Diseases 18: 187-193.
- ENTZEROTH, R., B. CHOBOTAR, AND E. SCHOLTYSECK. 1982. Ultrastructure of *Sarcocystis* sp. from the muscle of a white-tailed deer (*Odocoileus virginianus*). Zeitschrift für Parasitenkunde 68: 33-38.
- GREINER, E. C., M. E. ROELKE, C. T. ATKINSON, J. P. DUBEY, AND S. D. WRIGHT. 1989. *Sarcocystis* sp. in muscles of free-ranging Florida panthers and cougars (*Felis concolor*). Journal of Wildlife Diseases 25: 623-628.
- HARLOW, R. F., AND M. DEFOOR. 1962. How to age white-tailed deer. Florida Wildlife 16: 18-21.
- HAYAT, M. A. 1981. Principles and techniques of electron microscopy, Vol. I. University Park Press, Baltimore, Maryland, pp. 445-446.
- KARSTAD, L., AND D. O. TRAINER. 1969. *Sarcocystis* in white-tailed deer. Bulletin of the Wildlife Disease Association 5: 25-26.
- LINDSAY, D. S., B. L. BLAGBURN, W. H. MASON, AND J. C. FRANSEN. 1988. Prevalence of *Sarcocystis odocoileocanis* from white-tailed deer in Alabama and its attempted transmission in goats. Journal of Wildlife Diseases 24: 154-156.
- MAEHR, D. S., AND J. R. BRADY. 1986. Food habits of bobcats in Florida. Journal of Mammalogy 67: 133-138.
- , R. C. BELDEN, E. D. LAND, AND L. WILKINS. 1990. Food habits of panthers in southwest Florida. The Journal of Wildlife Management 54: 420-423.
- MAHRT, J. L., AND D. D. COLWELL. 1980. *Sarcocystis* in wild ungulates in Alberta. Journal of Wildlife Diseases 16: 571-576.
- MCPHERSON, B. F. 1973. Vegetation map of southern parts of subareas A and C, Big Cypress Swamp, Florida. Atlas HA-492. U.S. Geological Survey Hydrologic Investigation, Washington, D.C.
- MEHLHORN, H., W. J. HARTLEY, AND A. O. HEYDORN. 1976. A comparative ultrastructural study of the cyst wall of 13 *Sarcocystis* species. Protistologica 12: 451-467.
- MUNDAY, B. L., AND D. L. OBENDORF. 1984. Morphology of *Sarcocystis gigantea* in experimentally-infected sheep. Veterinary Parasitology 16: 193-199.
- O'BRIEN, S. J., M. E. ROELKE, N. YUHKI, K. W. RICHARDS, W. E. JOHNSON, W. L. FRANKLIN, A. E. ANDERSON, O. L. BASS, JR., R. C. BELDEN, AND J. S. MARTENSON. 1990. Genetic introgression within the Florida panther *Felis concolor coryi*. National Geographic Research 6: 485-494.
- POND, D. B., AND C. A. SPEER. 1979. *Sarcocystis* in free-ranging herbivores on the National Bison Range. Journal of Wildlife Diseases 15: 51-53.
- PRESTWOOD, A. K., AND J. F. SMITH. 1969. Distribution of meningeal worm (*Pneumostrongylus tenuis*) in deer in the southeastern United States. The Journal of Parasitology 55: 720-725.
- REYNOLDS, E. S. 1963. The use of lead nitrate at high pH as an electron opaque stain in electron microscopy. The Journal of Cell Biology 17: 208.
- SAS INSTITUTE INC. 1988. SAS/STAT® user's guide, release 6.03 edition. Cary, North Carolina. 1028 pp.

Received for publication 24 September 1991.