



Morbilliviral Disease in an Atlantic Bottlenose Dolphin (*Tursiops truncatus*) from the Gulf of Mexico

Authors: Lipscomb, Thomas P., Kennedy, Seamus, Moffett, Deborah, and Ford, Byron K.

Source: Journal of Wildlife Diseases, 30(4) : 572-576

Published By: Wildlife Disease Association

URL: <https://doi.org/10.7589/0090-3558-30.4.572>

BioOne Complete (complete.BioOne.org) is a full-text database of 200 subscribed and open-access titles in the biological, ecological, and environmental sciences published by nonprofit societies, associations, museums, institutions, and presses.

Your use of this PDF, the BioOne Complete website, and all posted and associated content indicates your acceptance of BioOne's Terms of Use, available at www.bioone.org/terms-of-use.

Usage of BioOne Complete content is strictly limited to personal, educational, and non - commercial use. Commercial inquiries or rights and permissions requests should be directed to the individual publisher as copyright holder.

BioOne sees sustainable scholarly publishing as an inherently collaborative enterprise connecting authors, nonprofit publishers, academic institutions, research libraries, and research funders in the common goal of maximizing access to critical research.

Morbilliviral Disease in an Atlantic Bottlenose Dolphin (*Tursiops truncatus*) from the Gulf of Mexico

Thomas P. Lipscomb,¹ Seamus Kennedy,² Deborah Moffett,² and Byron K. Ford,³ ¹ Department of Veterinary Pathology, Armed Forces Institute of Pathology, Washington, DC 20306, USA; ² Department of Agriculture for Northern Ireland, Veterinary Sciences Division, Stoney Road, Stormont, Belfast, Northern Ireland; ³ Gulf World, Inc., 15412 Front Beach Road, Panama City Beach, Florida, USA

ABSTRACT: A free-living adult female Atlantic bottlenose dolphin (*Tursiops truncatus*) found dead near Panama City, Florida (USA), had necrotizing and ulcerative tracheitis, suppurative and hemorrhagic pneumonia, and necrotizing myocarditis; fungal hyphae were present in these lesions. Additionally, lungs had multifocal proliferative interstitial pneumonia with occasional syncytial cells. Some syncytial cells and type II pneumocytes contained eosinophilic intranuclear or intracytoplasmic inclusion bodies, or both. Based on an immunoperoxidase technique, there was morbilliviral antigen within cytoplasm and nuclei of type II pneumocytes and syncytial cells; antigen also occurred in trachea, skin, liver, stomach, intestine, and uterus. Based on pathologic and immunocytochemical findings, the dolphin had morbillivirus-induced disease. This is the first report of morbilliviral disease in a marine mammal from the Gulf of Mexico.

Key words: Atlantic bottlenose dolphin, *Tursiops truncatus*, morbillivirus, Gulf of Mexico, case report.

Over the last few years, morbilliviruses have emerged as causes of several major epizootics that affected populations of Baikal seals (*Phoca sibirica*) in Lake Baikal (Grachev et al., 1989), harbor seals (*Phoca vitulina*) in northwestern Europe (Kennedy et al., 1988, 1989), and striped dolphins (*Stenella coeruleoalba*) in the Mediterranean Sea (Domingo et al., 1992). Recently, morbilliviral infection was implicated as the primary cause of the 1987 to 1988 U.S. Atlantic coast bottlenose dolphin epizootic (Lipscomb et al., 1994). Morbillivirus-induced disease also has been reported in harbor porpoises (*Phocoena phocoena*) in Northern Ireland, England and Scotland (Kennedy et al., 1991, 1992) and harbor seals in Long Island, New York (USA) (Duignan et al., 1993).

On 5 June 1993, an adult female Atlantic bottlenose dolphin (*Tursiops truncatus*)

was found dead in shallow water of the Gulf of Mexico near Panama City, Florida (30°7'N, 85°44'W). A group of dolphins was swimming nearby. Sharks were biting the carcass when it was removed from the water.

At necropsy, lacerations caused by post-mortem shark bites were present on the ventral abdomen and around the urogenital slit. Blood was found in the urogenital slit and in the area of the left eye. The teeth were severely worn, suggesting that the dolphin was old. Two discrete ulcers were present on the dorsal surface of the tongue. Subcutaneous tissue contained several areas of hemorrhage. Although the brain appeared to be normal, the overlying meninges were congested. An extensive area of the tracheal mucosa was dark red and roughened. Ventral regions of the lungs were dark red and contained multiple abnormally firm areas. Gas-filled bubbles considered to have been caused by putrefaction were present in the mesentery. The gastrointestinal tract was empty. The spleen, uterine mucosa, and multiple foci of the small intestinal mucosa appeared congested. Specimens of trachea, lung, tongue, gingiva, esophagus, squamous and fundic stomachs, small and large intestine, spleen, liver, kidney, adrenal glands, ovaries, uterus, hilar and cervical lymph nodes, heart, skin, brain, and skeletal muscle were preserved in formalin, embedded in paraffin, sectioned at 5 μ m, and stained with hematoxylin and eosin. Selected sections were stained by the periodic acid-Schiff procedure (Gaffney, 1992). Tissues were not cultured, and no tissues were frozen.

Histologically, the tracheal mucosa was ulcerated and covered by necrotic cellular debris, erythrocytes, and numerous neu-

trophils. Fungal hyphae were present throughout the lesion and occasionally penetrated the walls of blood vessels. Multifocally within the lung, alveoli and bronchioles were filled with numerous neutrophils and erythrocytes and fewer macrophages. Many of the inflammatory cells were necrotic. Fungal hyphae, occasionally in radial arrays, often were present among the inflammatory cells (Fig. 1). The ventricular myocardium contained scattered foci of necrosis accompanied by a mild infiltrate of neutrophils and macrophages; small numbers of hyphae were present among the necrotic myocardial fibers. Fungal hyphae from all sites were basophilic in hematoxylin and eosin-stained sections, ranged from 3 to 6 μm in width, were septate, and branched dichotomously in an arboreal pattern. Branching usually was at acute angles, and branches generally were parallel. These features are consistent with *Aspergillus* sp. (Chandler and Watts, 1987).

In some areas of the lungs not affected by fungal pneumonia, alveolar septa were thickened by type II pneumocyte hyperplasia and small numbers of interstitial lymphocytes, macrophages, plasma cells, eosinophils, and neutrophils. Alveolar lumina contained proteinaceous exudate, exfoliated type II pneumocytes, macrophages, and syncytial cells with two to 11 nuclei. Round to oval, 3 to 5 μm diameter, homogeneous, eosinophilic, intranuclear and intracytoplasmic inclusion bodies were present within type II pneumocytes and syncytial cells (Fig. 2).

A variety of histologic changes were found in other tissues. There was acute necrotizing and ulcerative glossitis; the cause was not apparent. Acute necrosis of lymphocytes was present multifocally in a cervical lymph node. A single mineralized eosinophilic granuloma was found in the lung. The ventricular myocardium had multifocal, mild fibrosis. Foci of recent hemorrhage were scattered in the brain and splenic capsule.

An immunoperoxidase technique using

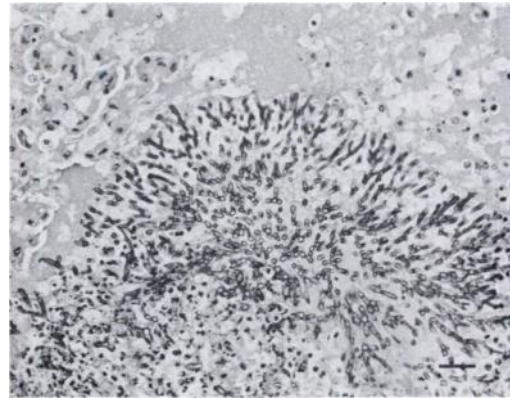


FIGURE 1. Radial array of fungal hyphae characteristic of *Aspergillus* sp. in lung of bottlenose dolphin. H&E. Bar = 25 μm .

a mouse monoclonal antibody against the glycosylated hemagglutinin protein of phocine distemper virus was used to detect morbilliviral antigen (Kennedy et al., 1991). This antibody also reacts with striped dolphin morbillivirus, harbor porpoise morbillivirus, canine distemper virus and measles virus (Domingo et al., 1990; Trudgett et al., 1991). The other reagents used for immunologic staining were part of a commercially available avidin-biotin-peroxidase technique kit (Vectastain Elite ABC Kit, Vector Laboratories Inc., Burlingame, California, USA). Tissue sections from morbillivirus-infected striped dolphins were used as positive controls. The specificity of immunologic staining was controlled by using an inappropriate antibody (to chicken anemia virus) on selected sections. Positive reactions, indicated by granular brown staining, were found in type II pneumocytes and syncytial cells (Fig. 3). Inclusion bodies stained intensely. Positive reactions also were found in tracheal glands, glossal epithelium, intrahepatic biliary epithelium, large intestinal epithelium, epidermis, and uterine epithelium.

The presence of histologic lesions characteristic of morbillivirus-induced disease, such as interstitial pneumonia with syncytial cells and intranuclear and intracytoplasmic inclusion bodies, combined with

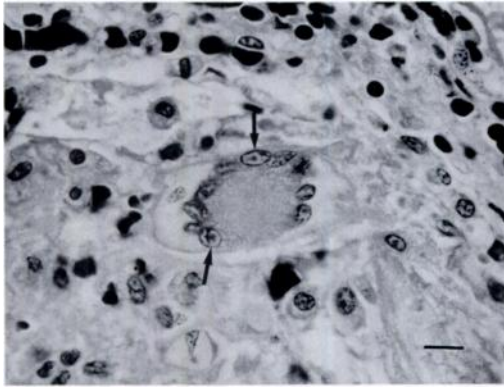


FIGURE 2. Syncytial cell in pulmonary alveolus of bottlenose dolphin. Note intranuclear inclusion bodies (arrows). H&E. Bar = 10 μ m.

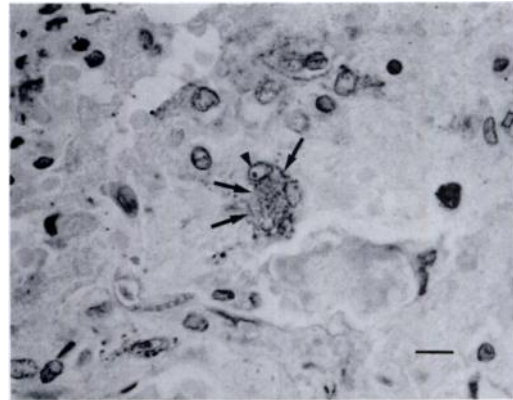


FIGURE 3. Immunoperoxidase staining of morbilliviral antigen filling cytoplasm (arrows) and focally within nucleus (arrowhead) of syncytial cell in lung of bottlenose dolphin. Bar = 10 μ m.

the demonstration of morbilliviral antigen within inclusion-bearing cells and many other cells are evidence that the dolphin was infected by a morbillivirus that was causing disease. This is the first recognized case of morbillivirus-induced disease in a marine mammal from the Gulf of Mexico.

The immediate cause of death was diagnosed as acute disseminated aspergillosis. Three of 58 striped dolphins that were examined during the morbilliviral epizootic in the Mediterranean Sea had fungal pneumonia and encephalitis; *Aspergillus fumigatus* was cultured (Domingo et al., 1992). A morbillivirus-infected harbor porpoise from the English coast had necrotizing pulmonary lesions associated with *Aspergillus* sp. fungi (Kennedy et al., 1992). Lungs of bottlenose dolphins from the 1987 to 1988 Atlantic coast epizootic that contained morbilliviral antigen often also had fungal pneumonia (Lipscomb et al., 1994). Morbilliviral infections of other species cause immunosuppression that frequently results in opportunistic infections (Dungworth, 1993). Morbillivirus-induced immunosuppression may have predisposed this dolphin to disseminated fungal infection.

The origin of this morbillivirus is unknown. Visser et al. (1993) and Barrett et al. (1993) found that morbilliviruses iso-

lated from North Sea harbor porpoises, Mediterranean striped dolphins, and North Sea harbor seals all were antigenically and genetically distinct. Because this dolphin was found within 1,260 km of the nearest site on the Atlantic coast of Florida where dolphins were known to have been affected by the 1987 to 1988 epizootic, we speculate that the same virus may have been involved in both instances.

The high mortality caused by morbilliviral infection of striped dolphins in the Mediterranean Sea and bottlenose dolphins in Atlantic coastal waters of the United States was consistent with infection of susceptible populations by highly pathogenic viruses. When this bottlenose dolphin died, increased mortality of dolphins in the Gulf of Mexico was not apparent. There are several possible explanations for this epizootiologic difference. The virus that infected the bottlenose dolphin from the Gulf of Mexico may be less pathogenic than other dolphin morbilliviruses. Alternatively, an epizootic might have occurred in the Gulf of Mexico, but it was not recognized. Also, bottlenose dolphins in the Gulf of Mexico may have had immunity to morbillivirus from previous exposures. During the 1987 to 1988 epizootic, six of 13 live-captured dolphins had antibodies

against canine distemper virus (Geraci, 1989); this is evidence of exposure to a morbillivirus. Thus, one or more morbilliviruses may have been present in U. S. bottlenose dolphin populations for at least the last several years.

The morbillivirus-induced lesions in this bottlenose dolphin were relatively subtle, but those caused by the disseminated fungal infection were extensive and severe. If this case was typical of morbilliviral infection in bottlenose dolphins, the viral lesions in other cases might be overlooked because of their subtlety or obscured by lesions caused by fulminant opportunistic infections. Additional studies are needed to characterize bottlenose dolphin morbillivirus and to determine its effects on dolphin populations in U.S. coastal waters and elsewhere.

We thank A. Trudgett and C. Lyons for providing the monoclonal antibody to phocine distemper virus and the participants in the Marine Mammal Stranding Network for facilitating examination of the dolphin. T. P. Lipscomb is a major in the U.S. Army. The opinions or assertions contained herein are the private views of the authors and are not to be construed as official or as reflecting the views of the Department of the Army or of the Department of Defense.

LITERATURE CITED

- BARRETT, T., I. K. G. VISSER, L. MAMAEV, L. GOATLEY, M.-F. VAN BRESSEM, AND A. D. M. E. OSTERHAUS. 1993. Dolphin and porpoise morbilliviruses are genetically distinct from phocine distemper virus. *Virology* 193: 1010-1012.
- CHANDLER, F. W., AND J. C. WATTS. 1987. Aspergillosis. *In* Pathologic diagnosis of fungal infections. American Society of Clinical Pathologists Press, Chicago, Illinois, pp. 55-74 and p. 87.
- DOMINGO, M. L., L. FERRER, M. PUMAROLA, A. MARCO, J. PLANA, S. KENNEDY, M. MCALISKEY, AND K. RIMA. 1990. Morbillivirus in dolphins. *Nature* 336: 21.
- , J. VISA, M. PUMAROLA, A. J. MARCO, L. FERRER, R. RABANAL, AND S. KENNEDY. 1992. Pathologic and immunocytochemical studies of morbillivirus infection in striped dolphins (*Stenella coeruleoalba*). *Veterinary Pathology* 29: 1-10.
- DUIGNAN, P. J., S. SADOVE, J. T. SALIKI, AND J. R. GERACI. 1993. Phocine distemper in harbor seals (*Phoca vitulina*) from Long Island, New York. *Journal of Wildlife Diseases* 29: 465-469.
- DUNGWORTH, D. L. 1993. The respiratory system. *In* Pathology of domestic animals, K. V. F. Jubb, P. C. Kennedy, and N. Palmer (eds.). Academic Press, San Diego, California, pp. 617-624.
- GAFFNEY, E. 1992. Carbohydrates. *In* Laboratory methods in histotechnology, E. B. Prophet, B. Mills, J. B. Arrington, and L. H. Sobin (eds.). American Registry of Pathology, Washington, D.C., pp. 151-152.
- GERACI, J. R. 1989. Clinical investigation of the 1987-88 mass mortality of bottlenose dolphins along the U.S. central and south Atlantic coast. Final report to National Marine Fisheries Service and U.S. Navy, Office of Naval Research, and Marine Mammal Commission, Guelph, Ontario, Canada, 63 pp.
- GRACHEV, M. A., V. P. KUMAREV, L. V. MAMAEV, V. L. ZORIN, L. V. BARANOVA, N. N. DENIKINA, S. I. BELIKOV, E. A. PETROV, V. S. KOLESNIK, R. S. KOLESNIK, V. M. DOROFEEV, A. M. BEIM, V. N. KUDELIN, F. G. NAGIEVA, AND V. N. SIDOROV. 1989. Distemper virus in Baikal seals. *Nature* 338: 209.
- KENNEDY, S., J. A. SMYTH, S. J. MCCULLOUGH, G. M. ALLAN, F. MCNEILLY, AND S. MCQUAID. 1988. Confirmation of cause of recent seal deaths. *Nature* 335: 404.
- , ———, P. F. CUSH, P. DUIGNAN, M. PLATTEN, S. J. MCCULLOUGH, AND G. M. ALLAN. 1989. Histopathologic and immunocytochemical studies of distemper in seals. *Veterinary Pathology* 26: 97-103.
- , ———, ———, M. MCALISKEY, S. J. MCCULLOUGH, AND B. K. RIMA. 1991. Histopathologic and immunocytochemical studies of distemper in harbor porpoises. *Veterinary Pathology* 28: 1-7.
- , T. KUIKEN, H. M. ROSS, M. MCALISKEY, D. MOFFETT, C. M. MCNIVEN, AND M. CAROLE. 1992. Morbillivirus infection in two common porpoises (*Phocoena phocoena*) from the coasts of England and Scotland. *The Veterinary Record* 131: 286-290.
- LIPSCOMB, T. P., F. Y. SCHULMAN, D. MOFFETT, AND S. KENNEDY. 1994. Morbilliviral disease in Atlantic bottlenose dolphins (*Tursiops truncatus*) from 1987-1988 epizootic. *Journal of Wildlife Diseases* 30: 567-571.
- TRUDGETT, A., C. LYONS, M. J. WELSH, N. DUFFY, S. J. MCCULLOUGH, S. MCNEILLY. 1991. Analysis of a seal and a porpoise morbillivirus using

- monoclonal antibodies. *The Veterinary Record* 128: 61.
- VISSEER, I. K. G., M.-F. VAN BRESSEM, R. L. DE SWART, M. W. G. VAN DE BILDT, H. W. VOS, R. W. J. VAN DER HEIJDEN, J. T. SALIKI, C. ÖRVELL, P. KITCHING, T. KUIKEN, T. BARRETT, AND A. D. M. E. OSTERHAUS. 1993. Characterization of morbilliviruses isolated from dolphins and porpoises in Europe. *Journal of General Virology* 74: 631-641.

Received for publication 30 November 1993.