

Ischemic Encephalopathy in Raccoons (*Procyon lotor*)

Authors: Hamir, A. N., and Rupprecht, C. E.

Source: Journal of Wildlife Diseases, 30(4) : 609-611

Published By: Wildlife Disease Association

URL: <https://doi.org/10.7589/0090-3558-30.4.609>

BioOne Complete (complete.BioOne.org) is a full-text database of 200 subscribed and open-access titles in the biological, ecological, and environmental sciences published by nonprofit societies, associations, museums, institutions, and presses.

Your use of this PDF, the BioOne Complete website, and all posted and associated content indicates your acceptance of BioOne's Terms of Use, available at www.bioone.org/terms-of-use.

Usage of BioOne Complete content is strictly limited to personal, educational, and non - commercial use. Commercial inquiries or rights and permissions requests should be directed to the individual publisher as copyright holder.

BioOne sees sustainable scholarly publishing as an inherently collaborative enterprise connecting authors, nonprofit publishers, academic institutions, research libraries, and research funders in the common goal of maximizing access to critical research.

Ischemic Encephalopathy in Raccoons (*Procyon lotor*)

A. N. Hamir¹ and C. E. Rupprecht,^{2,3} ¹ Department of Pathobiology, School of Veterinary Medicine, University of Pennsylvania, New Bolton Center, Kennett Square, Pennsylvania 19348, USA; ² Department of Microbiology and Immunology, Center for Neurovirology, Thomas Jefferson University, Philadelphia, Pennsylvania 19107, USA; ³ Present address: Centers for Disease Control, 1600 Clifton Road, Atlanta, Georgia 30333, USA

ABSTRACT: An acute and chronic case of cerebral infarction syndrome in two raccoons (*Procyon lotor*) respectively is described. The raccoon with an acute form of the condition had clinical neurologic signs whereas the raccoon with a chronic form of the condition had no evident clinical signs. In neither raccoon were significant vascular lesions seen. This is the first report of cerebral infarctions in raccoons.

Key words: Ischemic encephalopathy, cerebral infarction syndrome, raccoon, *Procyon lotor*.

Cerebral infarcts are not commonly observed in animals (Jones and Hunt, 1983; Jubb and Huxtable, 1993), and none have been documented in raccoons (*Procyon lotor*). We report here an acute and a chronic case, respectively in two different raccoons.

Case 1: In January 1986, an adult male raccoon was obtained from a breeder in Ohio (Dude's Exotic Farm, New Carlisle, Ohio, USA) for an experimental study of rabies virus pathogenesis. The raccoon was in captivity for >6 mo and then inoculated intramuscularly with a raccoon isolate of street rabies virus which was isolated from the salivary glands of a naturally infected raccoon from Pennsylvania (USA). (The inoculum had a titer of $10^{5.8}$ mouse intracerebral LD₅₀ per ml, and a volume of 0.3 ml was injected in the right masseter muscle). The animal developed characteristic signs of furious rabies and was euthanized by the intravenous administration of sodium pentobarbital (Euthanasia-6 Solution, Vet Labs Limited, Lenexa, Kansas, USA) on day 19 post-infection. At necropsy, gross lesions were confined to the brain. A well demarcated focal depression, approximately 15 mm long and involving the entire width of the anterior sylvian gyrus was present on the right side (Fig. 1). The

whole brain including the pituitary gland and representative tissue samples of organs (skin, tongue, salivary glands, heart, lung, trachea, thyroids, pancreas, liver, kidney, spleen, lymph nodes, esophagus, stomach, intestines, adrenals, and urinary bladder) were fixed in formalin. The fixed brain was cut at 3 mm width coronal sections and all the sections were embedded in paraffin, cut at 6 μ m and stained with hematoxylin and eosin for light microscopy.

Selected sections of brain (cerebral cortex, hippocampus, cerebellum, brainstem), Gasserian ganglion, tongue, salivary gland (parotid), pancreas, intestine (duodenum), and adrenal gland were stained by an immunoperoxidase technique (streptavidin-biotin complex, ABC) to detect rabies antigen (Hamir and Moser, 1994).

On examination of the affected area with the depression in the gyrus, the cavity was localized within the cortex (Fig. 2). There was extensive non-suppurative encephalitis, with mononuclear perivascular cuffing and multifocal gliosis in the brain. Tissue sections stained by the ABC technique had many cytoplasmic inclusions (Negri bodies) in neurons and ganglion cells of non-neuronal tissues, indicative of rabies infection. The grossly visible, focal cerebral cortical lesion, consisted essentially of empty space devoid of brain parenchyma. On one side, the cavity was covered by the meninges. Within the cavity and in the superficial layer of the neurophil bordering the cavity, there were moderate multifocal aggregates of foamy macrophages containing hemosiderin-like pigment. Also, at both sites, a few foci of cholesterol clefts were seen surrounded by macrophages and multinucleated giant cells. Elsewhere in the brain some of the smaller blood vessels in the meninges and choroid plexus had

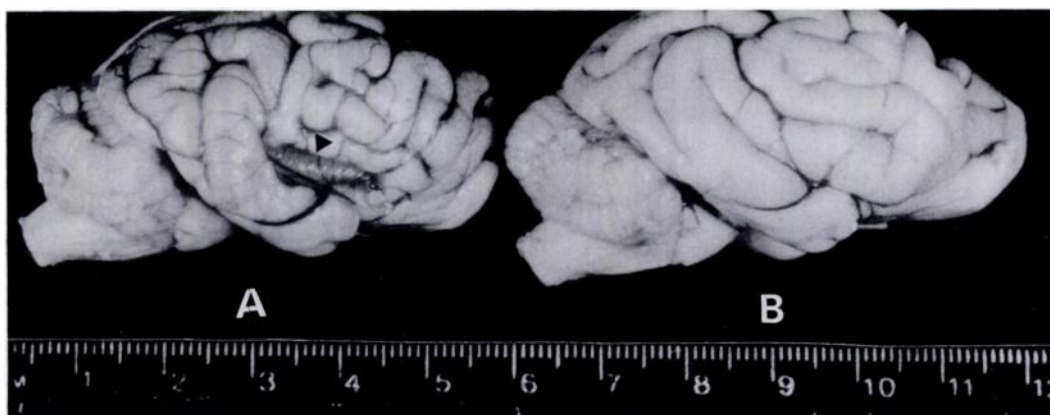


FIGURE 1. A—Brain of raccoon (case 1) showing a focal elongated depressed area (arrow head) of ischemia. B—Normal raccoon brain for comparison. Scale in cm.

multifocal mineralized areas, which appeared to have occluded their lumina.

Case 2: In November 1992, an adult female raccoon in Del Haven, New Jersey

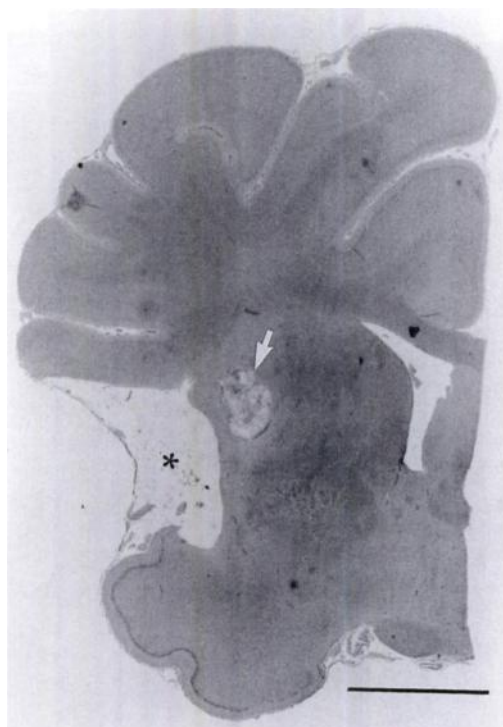

FIGURE 2. Brain section of a raccoon (case 1) showing focal area devoid of brain parenchyma (*). This is an ischemic focus. Subjacent to the ischemic area is an aggregate of macrophages and cholesterol clefts (arrow). H&E stain. Bar = 1 cm.

(USA) (39°00'N, 75°00'W), was found walking in circles during daylight hours. Since the raccoon was found close to a rabies enzootic area, it was live-trapped, and euthanized by the intravenous administration of sodium pentobarbital as in Case 1 for necropsy. Half of the brain was collected fresh for rabies diagnosis. The other half of the brain, together with the same tissues as sampled in Case 1 were fixed in 10% buffered formalin for histopathological examination and were evaluated for histopathology as described for Case 1.

The formalin-fixed brain was cut at approximately 3 mm wide transverse sections. The cut sections had a dark black focus approximately 4 mm in diameter in the cortex of the piriform area of the cerebrum. The approximate length of the lesion was 10 mm. Microscopic lesions in the brain were confined to the piriform area. There was a locally extensive central area of acute hemorrhagic and ischemic necrosis. Neurons, glial cells, blood vessels and inflammatory cells within the affected area had degenerative changes. The neuropil surrounding the necrohemorrhagic focus was vacuolated and blood vessels in this area were surrounded by inflammatory cells in which neutrophils predominated. Incidental lesions in this raccoon included the presence of a few mineralized blood vessels in the meninges and presence

of some cross-sections of a nematode with morphologic characteristics that were compatible with *Capillaria* sp. (Chitwood and Lichtenfels, 1972) in the epithelial layer of the tongue. Brain tissue was negative for rabies by the immunofluorescence test.

Based on gross and microscopic pathology, both cases were diagnosed as cerebrocortical infarcts. However, in neither of the raccoons were significant vascular lesions observed. Case 1 was considered as a chronic manifestation whereas case 2 was seen as an acute form of the syndrome.

Ischemic encephalopathy has been described in dogs (Norton, 1992) and in older pigs (Frankhauser et al., 1965). In cats a condition known as "feline ischemic encephalopathy-cerebral infarction syndrome" has been described (Jubb and Huxtable, 1993). It is characterized by a peracute onset of clinical signs which usually resolve in a few days (de Lahunta, 1983). Cats of mature age of both sexes are affected, and the lesion can be present either unilaterally or bilateral but not symmetrically (Jubb and Huxtable, 1993). In the raccoons, both animals were adults of different sex. In the case of chronic infarction (case 1), the lesion was present unilaterally; whereas in the acute case (case 2) it could not be confirmed whether the lesion was also located on the opposite side since only one half of the brain was available for histopathology.

The cause of the ischemia was unknown. The nature and distribution of the lesions was compatible with an ischemic etiology, although vascular lesions were not seen. The presence of mineralization of small meningeal and choroid plexus vessels in both raccoons was considered an incidental finding since such lesions frequently are seen in large numbers of normal as well

as ill raccoons from the eastern USA (A. N. Hamir, unpubl.).

It appears that the presentation of clinical signs in raccoons with cerebral infarctions cannot be readily distinguished from other neurologic conditions, such as rabies. Thus, we recommend a thorough diagnostic investigation of all raccoons with neurologic signs.

This study was supported in part by a grant from the Commonwealth of Pennsylvania Department of Agriculture. The technical expertise of R. Buchanan, D. Diehl, B. Lehmann and S. Hindman is greatly appreciated.

LITERATURE CITED

- CHITWOOD, M., AND J. R. LICHTENFELS. 1972. Parasitological review. Identification of parasitic metazoa in tissue sections. *Experimental Parasitology*. 32: 407-519.
- DE LAHUNTA, A. 1983. Feline ischemic encephalopathy—A cerebral infarction syndrome. *In* Current veterinary therapy, VI, R. W. Kirk (ed.). W.B. Saunders Company, Philadelphia, Pennsylvania, pp. 906-908.
- FRANKHAUSER, R., H. LUGINBUHL, AND T. J. MCGRATH. 1965. Cerebrovascular diseases in various animal species. *Annals of the New York Academy of Sciences* 127: 817-859.
- HAMIR, A. N., AND G. MOSER. 1994. Immunoperoxidase test for rabies: Utility as a diagnostic test. *Journal of Veterinary Diagnostic Investigation* 6: 148-152.
- JONES, T. C., AND R. D. HUNT. 1983. The nervous system. *In* Veterinary pathology. Lea and Febiger, Philadelphia, Pennsylvania, pp. 1637-1688.
- JUBB, K. V. F., AND C. R. HUXTABLE. 1993. The nervous system. *In* Pathology of domestic animals, Vol. 1, 4th ed., K. V. F. Jubb, P. C. Kennedy, and N. Palmer (eds.). Academic Press, Inc., San Diego, California, pp. 267-439.
- NORTON, F. 1992. Cerebral infarction in a dog. *Progress in Veterinary Neurology*. 3: 120-125.

Received for publication 16 August 1993.