

## **FLUORIDE EXPOSURE IN CERVIDS INHABITING AREAS ADJACENT TO ALUMINUM SMELTERS IN NORWAY. II. FLUOROSIS**

Authors: Vikøren, Turid, and Stuve, Gudbrand

Source: Journal of Wildlife Diseases, 32(2) : 181-189

Published By: Wildlife Disease Association

URL: <https://doi.org/10.7589/0090-3558-32.2.181>

---

BioOne Complete ([complete.BioOne.org](https://complete.BioOne.org)) is a full-text database of 200 subscribed and open-access titles in the biological, ecological, and environmental sciences published by nonprofit societies, associations, museums, institutions, and presses.

Your use of this PDF, the BioOne Complete website, and all posted and associated content indicates your acceptance of BioOne's Terms of Use, available at [www.bioone.org/terms-of-use](https://www.bioone.org/terms-of-use).

Usage of BioOne Complete content is strictly limited to personal, educational, and non - commercial use. Commercial inquiries or rights and permissions requests should be directed to the individual publisher as copyright holder.

---

BioOne sees sustainable scholarly publishing as an inherently collaborative enterprise connecting authors, nonprofit publishers, academic institutions, research libraries, and research funders in the common goal of maximizing access to critical research.

## FLUORIDE EXPOSURE IN CERVIDS INHABITING AREAS ADJACENT TO ALUMINUM SMELTERS IN NORWAY. II. FLUOROSIS

Turid Vikøren and Gudbrand Stuve

Section for Wildlife Diseases, Central Veterinary Laboratory,  
P.O. Box 8156 Department, N-0033 Oslo, Norway

**ABSTRACT:** Mandibles from 1104 red deer (*Cervus elaphus*), 147 moose (*Alces alces*), and 453 roe deer (*Capreolus capreolus*), collected between 1990 and 1993 in the vicinity of seven Norwegian aluminum smelters, were examined for dental fluorotic and osteofluorotic lesions. The metacarpal or metatarsal bones from 214 of these cervids also were evaluated. Dental fluorotic lesions occurred in all three cervid species. Prevalence of dental fluorosis was generally low at the various locations, with the exception of Årdal, where 15% of the cervids examined were affected. Only sporadic cases of severe dental fluorotic lesions were diagnosed. All red deer yearlings (1.5 yr) with mandibular fluorine (F) levels exceeding 2,000 ppm F, had dental fluorosis. However, the lowest skeletal fluorine level found in a fluorotic animal of this age was 1,355 ppm F. Gross osteofluorosis occurred in only three cervids, all with mandibular fluorine residues >8,000 ppm F. Hence, generalized fluorosis was not a prominent feature in the material studied.

**Key words:** Fluorine, dental fluorosis, osteofluorosis, cervids, *Cervus elaphus*, *Alces alces*, *Capreolus capreolus*.

### INTRODUCTION

Chronic fluorine toxicosis, a condition caused by prolonged excessive intake of fluoride, has a gradual development and onset. The detrimental effects of fluoride on bone (osteofluorosis) and teeth (dental fluorosis) have been thoroughly described and documented in various species, including humans (Roholm, 1937), cattle (Shupe et al., 1963), sheep (Slagsvold, 1934), and wild ungulates (Shupe et al., 1984; Kierdorf et al., 1993). As the response to fluoride may be influenced by several factors, the amount sufficient to induce fluorotic lesions varies by individual (Shupe, 1980).

Osteofluorosis, also referred to as generalized fluorosis, is more serious than dental fluorosis. Osteofluorosis results from the ingestion of toxic amounts of fluoride over an extended period and may develop throughout the life of an animal (Shupe, 1980). Fluoride may induce periosteal hyperostosis, osteoporosis, osteosclerosis, osteophytosis or osteomalacia in various combinations (Shupe et al., 1963). Dental fluorosis is the result of excessive fluoride intake during periods of tooth formation and mineralization (Shupe, 1980), and is characterized by mottling (opaque

horizontal areas or striations), enamel discoloration, hypoplasia, pitting or erosion of enamel, and abnormal abrasion (Shupe et al., 1963). Changes usually are bilateral, and teeth that are formed and mineralized simultaneously have lesions of similar severity (Shupe, 1980; Shupe et al., 1987). Dental fluorotic lesions in bovine deciduous teeth have been reported by Krook and Maylin (1979) and Maylin et al. (1987). However, these findings are in contradiction to observations made by Suttie et al. (1985a) and Shupe et al. (1987).

Based on the dental fluorotic lesions reported for roe deer (*Capreolus capreolus*) (Kierdorf, 1988; Kierdorf et al., 1993; 1994), these animals are very sensitive bioindicators of industrial fluoride pollution. Moreover, Ellenberg et al. (1985) consider roe deer to fulfill the criteria required of a biomonitoring species. Mule deer (*Odocoileus hemionus hemionus*) (Kay et al., 1975), white-tailed deer (*Odocoileus virginianus*) (Karstad, 1967; Kay et al., 1975; Suttie et al., 1987), and black-tailed deer (*Odocoileus hemionus columbianus*) (Newman and Murphy, 1979) also are useful as indicators of industrially-emitted fluoride.

Our objective was to determine the

TABLE 1. The prevalence and severity of dental fluorosis in red deer, moose, and roe deer collected between 1990 and 1993 from seven Norwegian municipalities in which aluminum smelters were located.

Site <sup>a</sup>	Species	Number of mandibles examined	Number of mandibles with dental fluorosis	Dental fluorosis category <sup>b</sup>			
				3	4	5	6
Årdal	Red deer	101	18	11	5	2	0
	Moose	30	1	0	1	0	0
Sunndal	Red deer	406	4	4	0	0	0
	Roe deer	217	3	0	2	0	1
Kvinnherad	Red deer	397	3	0	2	1	0
Farsund	Roe deer	236	4	2	1	0	1
Total		1,704	33	17	11	3	2

<sup>a</sup> Moose from Vefsn ( $n = 117$ ), and red deer from Høyanger ( $n = 177$ ) and Karmøy ( $n = 23$ ) did not have dental fluorosis.

<sup>b</sup> Fluorotic lesions were classified in four categories: 3) slight to moderate, 4) marked, 5) severe, and 6) excessive effect as described in the text.

prevalence and severity of fluorosis in cervids living in the vicinity of Norwegian aluminum smelters. Mandibular fluorine levels of the cervids included in this study are presented separately (Vikøren et al., 1996). Depending on the local population densities of the various cervid species, either red deer (*Cervus elaphus*), moose (*Alces alces*), or roe deer were chosen as indicators.

#### MATERIALS AND METHODS

Mandibles of 1104 red deer, 147 moose, and 453 roe deer were obtained during the regular hunting seasons between 1990 and 1993, from seven Norwegian municipalities in which primary aluminum smelters are located; Årdal, Sunndal, Kvinnherad, Farsund, Vefsn, Høyanger, and Karmøy. Location and area of the municipalities, and extent of fluoride emissions from the smelters were given by Vikøren et al. (1996). Variable numbers of mandibles were collected from each location (Table 1). Additionally, metacarpal or metatarsal bones were collected from 119 red deer and 39 roe deer from Sunndal, from 42 red deer from Årdal, and from 14 roe deer from Farsund. Hunters provided data on location, date, estimated age, sex, general condition, and carcass weight for each animal.

Bone samples for fluorine (F) analyses were obtained from *pars molaris* on the right *corpus mandibulae*, and processed and analyzed as described by Vikøren et al. (1996). Results were expressed as parts per million (ppm) F in bone ash.

Ages of red deer ( $\leq 2.5$  yr), and moose and roe deer ( $\leq 1.5$  yr), were determined by tooth

replacement (Reimers, 1981). All other animals were aged by examination of annuli in incisor tooth cementum after decalcification and staining of tooth sections (Reimers and Nordby, 1968), performed at the Norwegian Institute for Nature Research.

The mandibular teeth were inspected for signs of dental fluorosis and classified according to the following categories: 1, normal tooth: smooth, translucent, glossy, white enamel, normal tooth shape and size; 2, questionable effect: may have enamel flecks, unilateral or bilateral cavities, no mottling, unable to determine exact cause; 3, slight to moderate effect: slight to definite mottling of enamel, may have various degrees of staining; 4, marked effect: generalized mottling, pitting of enamel, staining or signs of wear; 5, severe effect: cream colored and pitted or eroded enamel with definite wear, staining may be present; and 6, excessive effect: as Category 5, but with excessive wear. This classification was based on Shupe et al. (1963) with the following modifications. Incisors and cheek teeth both were classified by the same criteria. In our study, Category 3 encompassed both the categories of slight and moderate effect, as suggested by Shupe et al. (1963). Teeth with enamel pits were classified as Category 4. Both direct and translucent illumination of the incisors were employed to reveal small fluorotic changes. Each animal was given an overall dentition score based on the individual tooth scores.

Mandibles, metacarpal, and metatarsal bones were examined grossly for osteofluorotic changes. The two latter bones were sectioned transversely one-third from the proximal end for examination of the cortex.

#### RESULTS

The prevalence of dental fluorosis was highest in cervids from Årdal (15%), fol-

lowed by Farsund (2%), Sunndal (1%), and Kvinnherad (1%) (Table 1). No macroscopic signs of chronic fluorine toxicosis were seen in cervids from Vefsn, Høyanger, and Karmøy. Only sporadic cases of severe dental fluorosis were diagnosed; 52% of all cases were classified as slight to moderate (Category 3). Altogether, 125 cervids had questionable dental changes (Category 2) and in 21 (17%) of these, the mandibular fluorine level exceeded 2,000 ppm F.

Fluorotic lesions on deciduous teeth were not recorded. In affected cervids with permanent dentition, the main findings were different degrees of fluorotic lesions on several tooth pairs. The first molar ( $M_1$ ) very rarely was affected, although in three animals all teeth exhibited fluorosis.

Of the 25 red deer with dental fluorosis, 11 (44%) were yearlings (1.5 yr), all shot in Årdal. These had fluorotic lesions of Category 3 or 4 on the first incisors ( $I_1$ ), whereas the second incisors ( $I_2$ ) in all but one animal were scored as Category 2, 3 or 4. No fluorotic lesions were registered on  $M_1$ , whereas the second molar ( $M_2$ ) except in one yearling, were scored as Category 2 or 3. The lowest mandibular fluorine level registered in yearlings with dental fluorosis, was 1,355 ppm F. The animal in question had slight mottling on  $I_1$  (Category 3). All red deer yearlings with mandibular fluorine levels exceeding 2,000 ppm F had dental fluorosis of Category 3 or 4 (Fig. 1).

Dental fluorosis was not diagnosed in roe deer yearlings. Five (14%) of 36 roe deer yearlings had fluorine levels exceeding 1,000 ppm F, whereas only two (6%) roe deer exceeded 2,000 ppm F. One of the latter roe deer had dental changes of questionable effects (Category 2). The lowest fluorine level found in fluorotic roe deer, was 2,380 ppm F. This was seen in a 4.5-yr-old male with enamel pits and brown discoloration (Category 4) on the premolars and the third molar ( $M_3$ ).

In red deer, fluorotic incisors had definite to generalized mottling. Additionally,

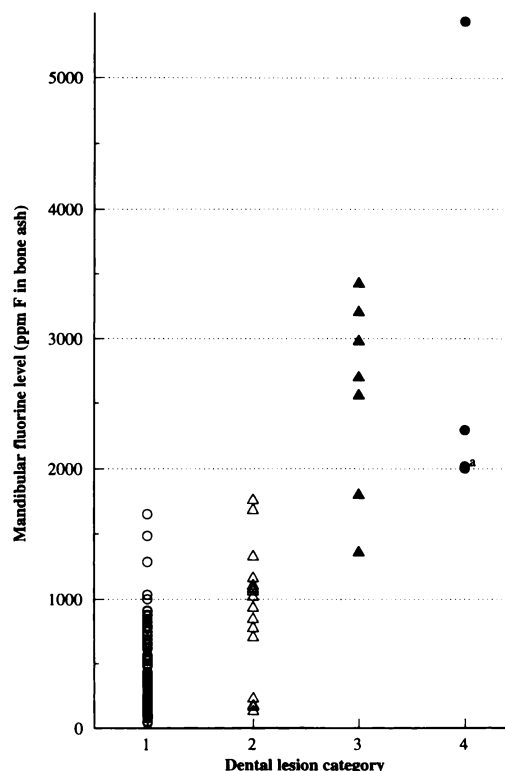
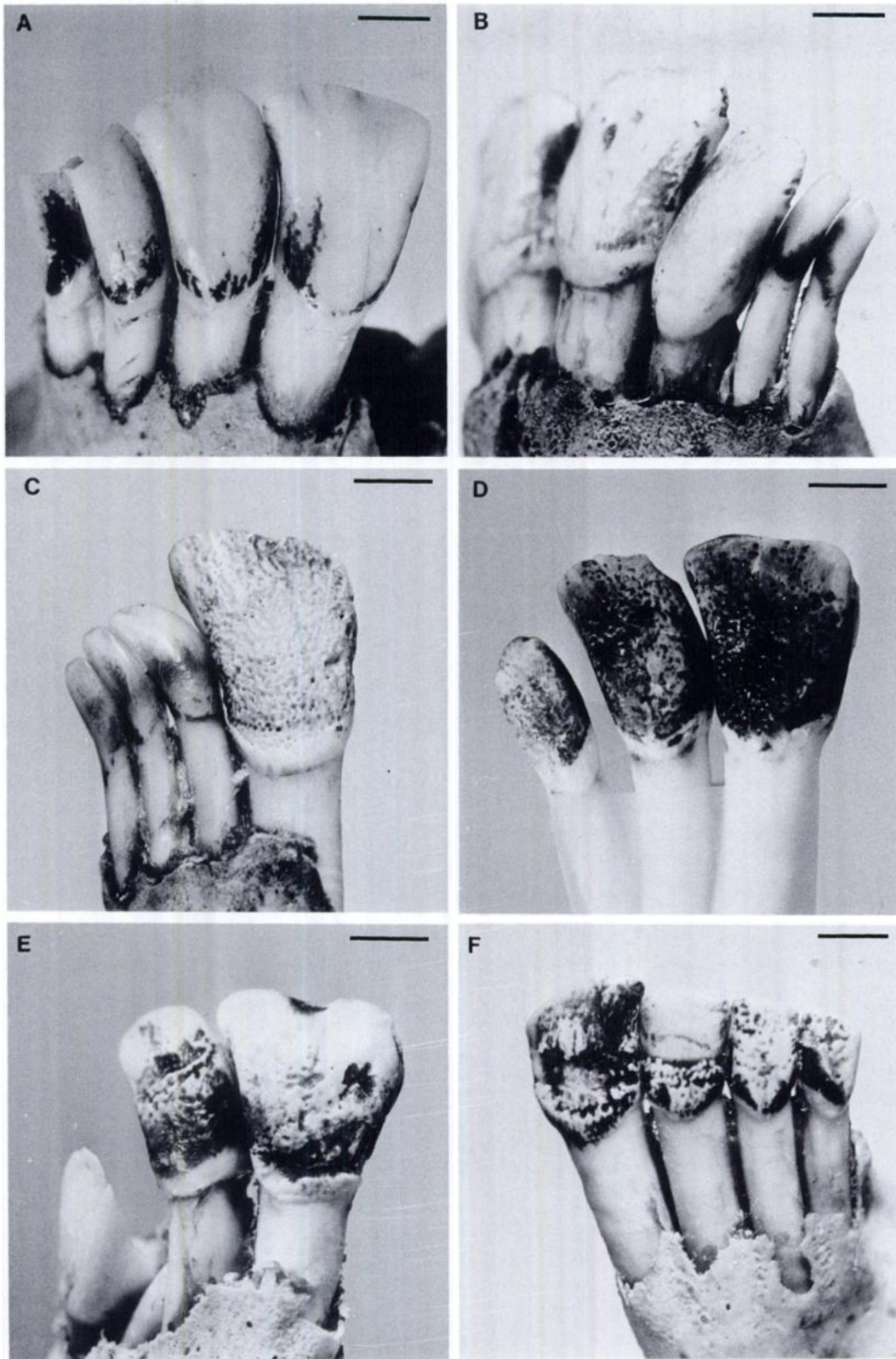


FIGURE 1. Mandibular fluorine (F) levels (ppm F in ashed bone) and dental lesion categories of 1.5-yr-old red deer collected in Årdal, Sunndal, Kvinnherad, Høyanger, and Karmøy municipalities. The following categories were registered: 1, normal teeth ( $n = 181$ ); 2, questionable effect, ( $n = 17$ ); 3, slight to moderate dental fluorosis ( $n = 7$ ); and 4, marked dental fluorosis ( $n = 4$ ). For<sup>a</sup>, these are two animals with the same category and similar mandibular fluorine levels.

enamel pits and grooves were seen in more severe cases (Fig. 2). Definite to severe uneven abrasion of fluorotic cheek teeth in combination with enamel pits or discoloration (Figs. 3 and 4), occurred in red deer older than 2.5 yr with mandibular fluorine levels  $>6,500$  ppm F. In yearlings, fluorotic lesions on recently erupted  $M_2$  were manifested as mottling, pitting, and occasionally slight brown discoloration of enamel (Fig. 4).

In fluorotic roe deer, enamel of affected cheek teeth was opaque with varying degrees of brownish discoloration and pitting of the surface (Fig. 5). In addition, uneven attrition and loss of enamel ridges were ev-



ident. Mottled and discolored enamel also was found on incisors.

Dental fluorosis occurred in one moose only, a 4.5-yr-old male from Årdal with 3400 ppm F in the mandible. The whole dentition except  $M_1$  was affected; dental lesions were similar to those seen in roe deer and red deer.

Gross osteofluorotic lesions were registered only in two red deer from Årdal and in one roe deer from Sunndal, with mandibular fluorine levels of 12,700 ppm F (11.5 yr), 8,500 (9.5 yr), and 8,700 (4.5 yr), respectively. The 11.5-yr-old female red deer had a single exostosis on the mandible, and ligament calcification was noted on the metacarpal bone. Unfortunately, the mandible of this animal had been cut between  $M_1$  and  $M_2$ , and additionally, several incisors were missing. The remaining teeth had pronounced uneven attrition and brown discoloration, except for the  $M_1$  which seemed unaffected. The second osteofluorotic red deer (9.5 yr) had small exostoses on the mandible, but no gross fluorotic lesions on the metacarpal bones or on the dentition. The affected roe deer (4.5 yr) had exostosis on the mandible and extensive dental fluorosis; the metacarpal and metatarsal bones were unavailable for examination.

### DISCUSSION

The local difference in prevalence of dental fluorosis corresponds well with the mandibular fluorine residues found in cer-

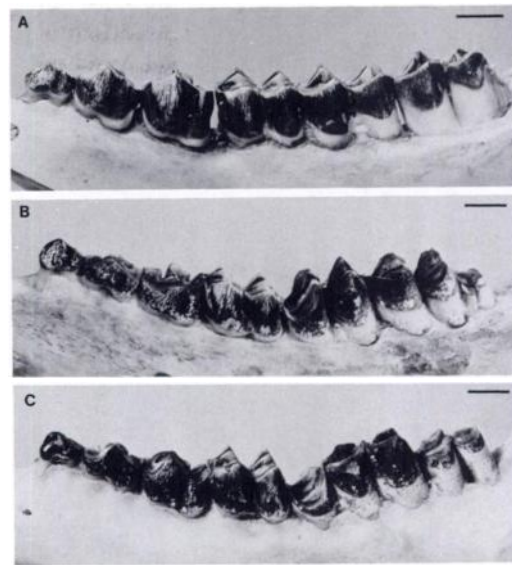


FIGURE 3. Left mandibular cheek teeth of red deer, bucco-occlusal view. A) Normal teeth (Category 1) of a 2.5-yr-old female. B) Fluorosed cheek teeth of a 6.5-yr-old female (H-122/92) with 8750 ppm F in the mandible (Category 4 = moderate effect). Increased wear on premolars, which also had enamel pits and brown discoloration. The first molar ( $M_1$ ) was normal. Uneven abrasion and pigmentation of  $M_2$  and  $M_3$ . Loss of enamel ridges of the affected cheek teeth. C) The same red deer as shown in Fig. 2F (H-218/90). The fluorotic lesions on the cheek teeth were similar to B, but the abrasions were more extensive, in particular on the cranial part of  $M_2$ . The lesions were classified as Category 5 (severe effect). Bars = 1 cm.

vids from the various municipalities (Vikøren et al., 1996). Fluorotic red deer were collected at various distances, as far as 30 km from the aluminum smelters,

←

FIGURE 2. Mandibular incisors ( $I_1$ - $I_2$ - $I_3$ -C) of red deer, buccal view. Details of the categories used to classify dental fluorotic lesions are given in the text. A) Normal incisors (categories: 1-1-1-1) of a 4.5-yr-old female. B) Dental fluorosis in a male yearling (H-314/92) with a mandibular load of 2550 ppm F, classified as 4-3-1-1. Extensive generalized mottling of  $I_1$  and  $I_2$ , and small enamel pits on the upper half of the crown of  $I_1$ . C) Dental fluorotic lesions in a female yearling (H-161/91) with 5440 ppm F, classified as 4-1-1-1. The whole crown of the permanent  $I_1$  had pitted enamel. Normal deciduous  $I_2$ -C. D) Fluorotic incisor teeth of a 3.5-yr-old female (H-335/91) with 6480 ppm F. The lesions were classified as 5-5-0-4. Brown discoloration and extensive enamel pitting involving large parts of the crowns. Definite wear of the buccal upper part of  $I_1$ . The third incisor ( $I_3$ ) was lost. E) Incisors of a female yearling (H-207/90) with 2,000 ppm F, having fluorotic lesions classified as 4-4-0-0. Enamel pits and grooves of uneven size and distribution were found on the permanent  $I_1$  and  $I_2$ . Permanent  $I_3$  and C had not erupted. F) Fluorotic incisor teeth of a 5.5-yr-old female (H-218/90) with 6820 ppm F, classified as 5-5-4-4. Extensive enamel hypoplasia of  $I_1$  and  $I_2$ , and scattered enamel pits on  $I_3$  and C. Definite wear of incisors. Bars = 5 mm.

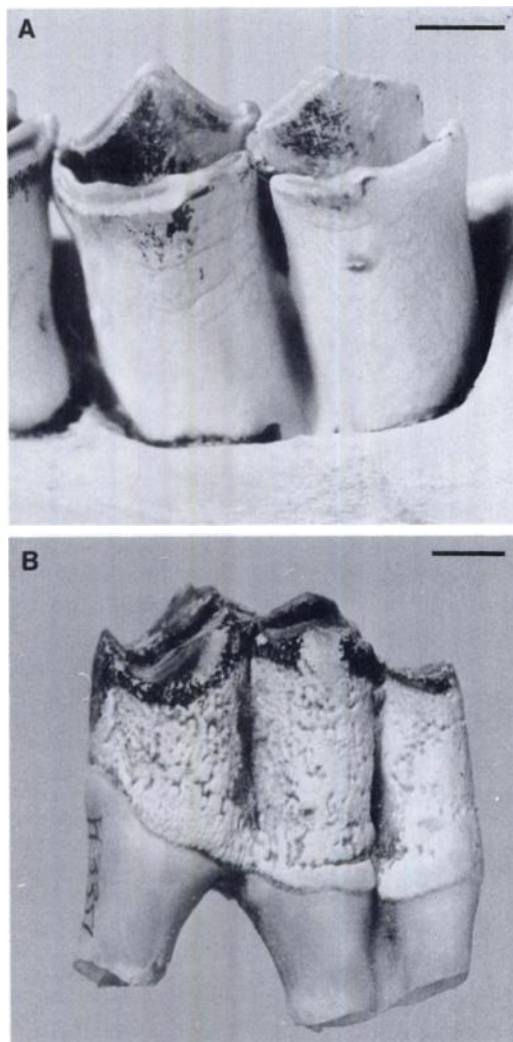


FIGURE 4. Higher magnification of fluorosed cheek teeth in red deer, bucco-occlusal view. A) The second molar ( $M_2$ ) of red deer yearling H-314/92, the incisors of which are shown in Fig. 2B. The enamel was mottled, seen as uneven horizontal striations. Fluorotic lesions of Category 3. B) The  $M_3$  of red deer H-335/91, whose incisors are shown in Fig. 2D. The  $M_3$  had extensive hypoplasia of enamel seen as scattered grooves and pits, and increased wear. The lesions were of Category 5. Bars = 5 mm.

whereas affected roe deer were collected within 5 km from the emission sources, except for one collected 16 km from the smelter in Sunndal. Roe deer are usually sedentary (Østbye and Bjørnsen, 1990), and thus likely to be heavily exposed to

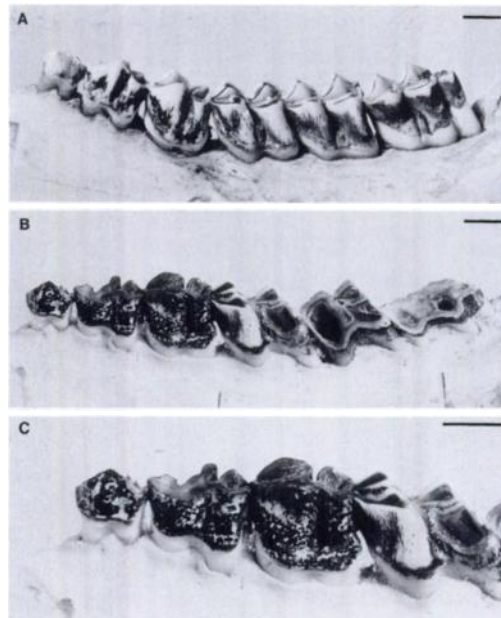


FIGURE 5. Left mandibular cheek teeth of roe deer, bucco-occlusal view. A) Normal teeth (Category 1) of a 2.5-yr-old roebuck with 300 ppm fluorine (F) in the mandible. B) Excessive fluorotic lesions on cheek teeth of a 2.5-yr-old roebuck (R-178/93) with a mandibular fluorine content of 7430 ppm F. The lesions were classified as Category 6 (excessive effect). There was severe pitting, brown discoloration, and definite wear of the premolars. Excessive abrasion of the second molar ( $M_2$ ) and  $M_3$ , with loss of enamel ridges and exposure of pulp cavities. Pronounced wear of caudal parts of  $M_1$ . C) Higher magnification of the second premolar to  $M_1$  shown in B). The enamel surface of the premolars exhibited numerous areas of hypoplasia, seen as pits and grooves. Bars = 5 mm.

fluoride if they inhabit a highly contaminated area. This may cause adverse effects as exemplified in our study, the most severe dental fluorosis being registered in two roe deer.

Our findings support previous observations in roe deer (Kierdorf, 1988; Kierdorf et al., 1993) and other wild ungulates (Shupe et al., 1984), and provide evidence for periodic variation in fluoride exposure of cervids during the period of teeth formation and mineralization. A number of factors, both environmental and animal-related, may cause intermittent fluoride exposure in free-ranging cervids living in in-

dustrially fluoride polluted areas (Kierdorf et al., 1993).

The sequence of tooth development and replacement varies between cervid species, and must be considered when comparing patterns of fluorotic lesions in various species. The permanent dentition is complete and fully erupted by the age of 13 to 14 mo in roe deer, 16 to 17 mo in moose, and 25 to 27 mo in red deer (Reimers, 1981; Kierdorf and Kierdorf, 1989). Thus, the period during which fluoride exposure may cause dental fluorosis is considerably longer in red deer than in roe deer and moose. This may partly explain the higher prevalence of dental fluorosis in red deer than in moose, as found in Årdal, since the dentition of moose is sensitive to fluoride over a shorter period. Moreover, the higher prevalence of fluorotic lesions on  $I_1$  in red deer than in roe deer may partly be due to the longer development period of  $I_1$  in red deer.

Based on our results, we believe that red deer are at risk of developing dental fluorotic lesions when they accumulate between 1,000 and 2,000 ppm F during the first 1.5 yr of life. This assumption seems to be in accordance with findings in white-tailed deer (Suttie et al., 1987). The only feeding experiment in cervids reported in the literature was performed on white-tailed deer by Suttie et al. (1985b). The animals were fed a commercial horse ration from the age of 5 mo; thus "the fluoride intake of the control deer was probably equivalent to about 10 ppm F of a soluble fluoride." The control deer accumulated about 1500 ppm F in the vertebrae during 1 yr of uniform feeding, and had no signs of dental fluorosis. In our study, however, corresponding mandibular fluorine levels were found in two red deer yearlings with dental fluorotic lesions. The induction of dental fluorosis in these two animals might have been caused by intermittent fluoride intake, since alternate ingestion of high and low doses of fluoride is more damaging than a constant intake (Suttie et al., 1972). Our results support

the notion that developing teeth are sensitive to fluoride.

In this study, we provide the first descriptions of dental fluorotic lesions in red deer. Grossly, these seem not to differ from those of other deer species. The gross fluorotic lesions found on roe deer cheek teeth were similar to those described in roe deer from Germany by Kierdorf (1988) and Kierdorf et al. (1993). In these two studies, it was concluded that fluorotic changes were predominant on the permanent premolars and  $M_3$ , whereas  $M_1$ , and to a lesser degree  $M_2$ , rarely were affected. This was attributed to several protective mechanisms during the formation of  $M_1$  and  $M_2$ , including a partial placental transfer barrier to fluoride, low fluoride content in milk, and rapid skeletal growth in the fetus and young fawn.

In our study, however,  $M_1$  was affected in two of seven cases of dental fluorosis in roe deer, having definite wear, especially in the caudal part of the tooth (Fig. 6). In both animals, all permanent mandibular cheek teeth were adversely affected. The protective mechanisms discussed in detail by Kierdorf (1988), and the fact that no fluorotic deciduous teeth were found in our material, do not exclude the possibility of  $M_1$  becoming affected by fluoride. In pigs (Richards et al., 1986) and sheep (Suckling et al., 1988), fluoride exposure in the tooth maturation phase only cause enamel fluorosis seen as enamel hypomineralization. Milhaud et al. (1992) demonstrated a marked post-secretory effect of fluoride on ovine enamel which then caused reduced hardness of enamel, thus lowering the tooth resistance to wear. In roe deer fawns, the crown formation of the mandibular  $M_1$  is completed at the age of 6 to 8 wk (Kierdorf and Kierdorf, 1989). During the first 3 to 4 wk, the fawn mainly suckles, and usually is stationary within an area of 1 to 2 ha. The habitat thereafter is gradually expanded (Østbye and Bjørnsen, 1990). If the habitat of fawns is severely contaminated, we believe the fawns are likely to ingest significant amounts of flu-

oride from the first mouthful of vegetation, and  $M_1$  may thus become affected by fluoride at a late stage of maturation.

Generalized fluorosis was not a prominent feature in our study. Only three cervids had moderate gross osteofluorotic lesions, all having high mandibular fluorine levels. In contrast, Newman and Murphy (1979) reported that black-tailed deer with metatarsal fluorine levels exceeding 2,000 ppm F (dry fat-free weight) had "chalky white and roughened periosteal surfaces as well as thickening of these bones." This figure is comparable to 2,900 ppm F on an ash weight basis (Suttie et al., 1987). Thus, a higher prevalence of generalized fluorosis than found in our study might be expected when taking the mandibular fluorine levels reported by Vikøren et al. (1996) into consideration. These conflicting results may reflect differences between species in the skeletal response to fluoride. Based on experimental studies, Suttie et al. (1985b) concluded that osteofluorotic lesions in white-tailed deer seemed less pronounced than in cattle on a similar feeding program, although the skeletal retention of fluoride appeared to be equal or slightly more rapid in white-tailed deer. Several red deer and roe deer in our study had high levels of fluorine without signs of gross osteofluorosis. Thus, we believe that the response to fluoride exposure in these species is similar to that in white-tailed deer.

All three cervid species studied had characteristic dental fluorosis and thus may be regarded as being sensitive indicators of fluoride exposure. While young cervids are best suited as indicators of recent fluoride exposure, dental fluorosis in older animals is evidence for fluoride exposure further back in time during the period of development of their permanent dentition.

#### ACKNOWLEDGMENTS

We thank hunters and local wildlife management authorities for their assistance in the collection of materials. Thanks are due to A. Stov-

ner for skillful preparation of specimens, and to the laboratory personnel at Hydro Aluminium in Årdal who performed the chemical analyses. We are grateful to Professor A. Frøslie for valuable advice during the study and for constructive criticism of the manuscript. Funding was provided by the Norwegian Research Council and the Norwegian aluminum producers; Hydro Aluminium a.s, Elkem Aluminium ANS, and Sør-Norge Aluminium A/S.

#### LITERATURE CITED

- ELLENBERG, H., J. DIETRICH, M. STOEPLER, AND H. W. NÜRNBERG. 1985. Environmental monitoring of heavy metals with birds as pollution integrating biomonitors. I. Introduction, definitions and practical examples for goshawk (*Accipiter gentilis*). In Heavy metals in the environment, D. T. Lekkas, (ed.). CER Consultants Ltd., Edinburgh, Scotland, pp. 724–726.
- KARSTAD, L. 1967. Fluorosis in deer (*Odocoileus virginianus*). Bulletin of the Wildlife Disease Association 3: 42–46.
- KAY, C. E., P. C. TOURANGEAU, AND C. C. GORDON. 1975. Industrial fluorosis in wild mule and whitetail deer from western Montana. Fluoride 8: 182–191.
- KIERDORF, H., AND U. KIERDORF. 1989. Studies of the development of dentition in the European roe deer (*Capreolus c. capreolus* L., 1758). Zoologische Jahrbücher Abteilung für Anatomie 119: 37–75.
- KIERDORF, U. 1988. Untersuchungen zum Nachweis immissionsbedingter chronischer Fluoridintoxikation beim Reh (*Capreolus capreolus* L.). Zeitschrift für Jagdwissenschaft 34: 192–204.
- KIERDORF, U., H. KIERDORF, AND O. FEJERSKOV. 1993. Fluoride-induced developmental changes in enamel and dentin of European roe deer (*Capreolus capreolus* L.) as a result of environmental pollution. Archives of Oral Biology 38: 1071–1081.
- , M. SCHULTZ, AND H. KIERDORF. 1994. Licht- und rasterelektronenmikroskopische Untersuchungen an Schmelzhypoplasien fluorotischer Rehzähne. Zeitschrift für Jagdwissenschaft 40: 175–184.
- KROOK, L., AND G. A. MAYLIN. 1979. Industrial fluoride pollution. Chronic fluoride poisoning in Cornwall Island cattle. The Cornell Veterinarian 69 (Supplement 8): 1–70.
- MAYLIN, G. A., R. H. ECKERLIN, AND L. KROOK. 1987. Fluoride intoxication in dairy calves. The Cornell Veterinarian 77: 84–98.
- MILHAUD, G. E., E. CHARLES, M.-L. LOUBIÈRE, M. KOLF-CLAUW, AND C. JOUBERT. 1992. Effects of fluoride on secretory and postsecretory phases of enamel formation in sheep molars. American Journal of Veterinary Research 53: 1241–1247.

- NEWMAN, J. R., AND J. J. MURPHY. 1979. Effects of industrial fluoride on black-tailed deer (preliminary report). *Fluoride* 12: 129–135.
- ØSTBYE, E. AND B. BJØRNSSEN. 1990. Radyret. In *Norges Dyr, Pattedyrene 2*, A. Semb-Johansson (ed.). J. W. Cappelens Forlag a. s., Oslo, Norway, pp. 128–147.
- REIMERS, E. 1981. *Storviltet*. A/S Landbruksforlaget, Oslo, Norway, 205 pp.
- , AND Ø. NORDBY. 1968. Relation between age and tooth cementum layers in Norwegian reindeer. *The Journal of Wildlife Management* 32: 957–961.
- RICHARDS, A., J. KRAGSTRUP, K. JOSEPHSEN, AND O. FEJERSKOV. 1986. Dental fluorosis developed in post-secretory enamel. *Journal of Dental Research* 65: 1406–1409.
- ROHOLM, K. 1937. Fluorine intoxication. A clinical-hygienic study. *Nyt Nordisk Forlag*, Copenhagen, Denmark, 364 pp.
- SHUPE, J. L., 1980. Clinicopathologic features of fluoride toxicosis in cattle. *Journal of Animal Science* 51: 746–758.
- , M. L. MINER, D. A. GREENWOOD, L. E. HARRIS, AND G. E. STODDARD. 1963. The effect of fluorine on dairy cattle. II. Clinical and pathologic effects. *American Journal of Veterinary Research* 24: 964–979.
- , A. E. OLSON, H. B. PETERSON, AND J. B. LOW. 1984. Fluoride toxicosis in wild ungulates. *Journal of the American Veterinary Medical Association* 185: 1295–1300.
- , P. V. CHRISTOFFERSON, A. E. OLSON, E. S. ALLRED, AND R. L. HURST. 1987. Relationship of cheek tooth abrasion to fluoride-induced permanent incisor lesions in livestock. *American Journal of Veterinary Research* 48: 1498–1503.
- SLAGSVOLD, L. 1934. Fluorforgiftning. *Norsk Veterinærtidsskrift* 46: 2–16, 61–68.
- SUCKLING, G., D. C. THURLEY, AND D. G. A. NELSON. 1988. The macroscopic and scanning electron-microscopic appearance and microhardness of the enamel, and the related histological changes in the enamel organ of erupting sheep incisors resulting from a prolonged low daily dose of fluoride. *Archives of Oral Biology* 33: 361–373.
- SUTTIE, J. W., J. R. CARLSON, AND C. E. FALTIN. 1972. Effects of alternating periods of high- and low-fluoride ingestion on dairy cattle. *Journal of Dairy Science* 55: 790–804.
- , A. B. CLAY, AND T. R. SHEARER. 1985a. Dental fluorosis in bovine temporary teeth. *American Journal of Veterinary Research* 46: 404–408.
- , R. J. HAMILTON, A. C. CLAY, M. L. TOBIN, AND W. G. MOORE. 1985b. Effects of fluoride ingestion on white-tailed deer (*Odocoileus virginianus*). *Journal of Wildlife Diseases* 21: 283–288.
- , R. DICKIE, A. B. CLAY, P. NIELSEN, W. E. MAHAN, D. P. BAUMANN, AND R. J. HAMILTON. 1987. Effects of fluoride emissions from a modern primary aluminum smelter on a local population of white-tailed deer (*Odocoileus virginianus*). *Journal of Wildlife Diseases* 23: 135–143.
- VIKØREN, T., G. STUVE, AND A. FRØSLIE. 1996. Fluoride exposure in cervids inhabiting areas adjacent to aluminum smelters in Norway. I. Residue levels. *Journal of Wildlife Diseases* 32: 169–180.

*Received for publication 16 February 1995.*