



## **Pyogranulomatous peritonitis associated with *Nocardia* sp.-like organisms in a raccoon (*Procyon lotor*)**

Authors: Hamir, Amir N., and Rupprecht, Charles E.

Source: Journal of Wildlife Diseases, 32(2) : 373-375

Published By: Wildlife Disease Association

URL: <https://doi.org/10.7589/0090-3558-32.2.373>

---

BioOne Complete ([complete.BioOne.org](https://complete.BioOne.org)) is a full-text database of 200 subscribed and open-access titles in the biological, ecological, and environmental sciences published by nonprofit societies, associations, museums, institutions, and presses.

Your use of this PDF, the BioOne Complete website, and all posted and associated content indicates your acceptance of BioOne's Terms of Use, available at [www.bioone.org/terms-of-use](https://www.bioone.org/terms-of-use).

Usage of BioOne Complete content is strictly limited to personal, educational, and non - commercial use. Commercial inquiries or rights and permissions requests should be directed to the individual publisher as copyright holder.

---

BioOne sees sustainable scholarly publishing as an inherently collaborative enterprise connecting authors, nonprofit publishers, academic institutions, research libraries, and research funders in the common goal of maximizing access to critical research.

## Pyogranulomatous peritonitis associated with *Nocardia* sp.-like organisms in a raccoon (*Procyon lotor*)

Amir N. Hamir,<sup>1,3</sup> and Charles E. Rupprecht<sup>2,4</sup> <sup>1</sup>Department of Pathobiology, School of Veterinary Medicine, University of Pennsylvania, New Bolton Center, Kennett Square, Pennsylvania 19348, USA; <sup>2</sup>Department of Microbiology & Immunology, Center for Neurovirology, Thomas Jefferson University, Philadelphia, Pennsylvania 19107, USA; <sup>3</sup>Present address: Veterinary Diagnostic Laboratory, Oregon State University, Corvallis, Oregon 97331 USA <sup>4</sup>Present address: Centers for Disease Control and Prevention, 1600 Clifton Road, Atlanta, Georgia 30333, USA.

**ABSTRACT:** During 1992 raccoons (*Procyon lotor*) were live-trapped in northeastern Pennsylvania (USA). In one of these animals a localized pyogranulomatous peritonitis was seen. Grossly a large mass with a central area of liquefactive necrosis was present in the anterior abdomen. Microscopically the lesion contained multiple colonies of filamentous organisms with histomorphologic and histochemical characteristics resembling *Nocardia* sp. This appears to be the first report of *Nocardia* infection in the raccoon.

**Key words:** Granulomatous peritonitis, *Nocardia* sp., raccoon, *Procyon lotor*.

*Nocardia* spp. are aerobic, Gram-positive, partially acid-fast, filamentous organisms (Gordon, 1980) which incite a granulomatous reaction in host animals. In domestic animals the organisms can produce either localized or generalized lesions. To our knowledge lesions caused by *Nocardia* sp. have not been documented previously in the raccoon (*Procyon lotor*). We report here a large localized granulomatous lesion in the peritoneal cavity of a raccoon. The gross, microscopic and histochemical findings were compatible with an infection by a *Nocardia* sp.-like organism.

During the course of experimental development and subsequent field evaluation of an oral vaccinia-rabies glycoprotein recombinant virus vaccine (Rupprecht et al., 1986, 1992), wild raccoons were live-trapped (Tomahawk #207 traps, Tomahawk Live Trap Company, Tomahawk, Wisconsin, USA) in the field and transported to the laboratory where they were held prior to experimental assignment. Raccoons were held in stainless steel squeeze cages and were provided food and water ad libitum.

In July 1992, an adult male raccoon was

obtained from State Gamelands No. 13 in northeastern Pennsylvania, USA (76°30'N, 41°20'W). After 1 wk of laboratory confinement the raccoon was anorectic and lethargic. When the animal did not improve in a few days, it was euthanized by intravenous administration of sodium pentobarbitol (Euthanasia-6 Solution, Vet Labs Limited, Lenexa, Kansas, USA) and necropsied.

The carcass was in a fair nutritional state. Gross lesions were confined to the peritoneal cavity which contained a moderate amount of cloudy, straw-colored fluid. A large (85 × 100 × 120 mm), firm mass with the omentum tightly attached to its surface was adhering to the mesentery in the pyloric region of the greater curvature of the stomach. The stomach was empty. The mass contained a central oblong cavity, approximately 15 × 25 mm., filled with white, flakey fluid (Fig. 1).

The entire peritoneal mass together with representative tissues of heart, lung, liver, gall bladder, kidney, pancreas, spleen, skin, stomach, intestines, mesenteric lymph node, eye, salivary gland, urinary bladder, trachea, thyroids, esophagus, aorta, adrenal glands, testicle, and brain were fixed in neutral buffered formalin, embedded in paraffin, sectioned at 5 µm and stained with hematoxylin and eosin. Selected tissue sections of the peritoneal mass were also stained with Brown and Brenn, Gomori's methenamine silver, Ziehl-Neelsen acid-fast, and Kinyoun's acid-fast stains (Luna, 1968).

On microscopic examination, the mass had an extensive pyogranulomatous reaction with many variably-sized amphophilic

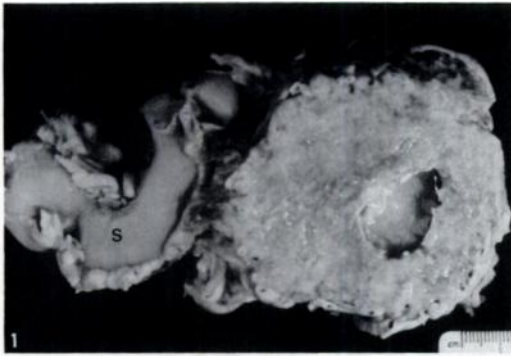


FIGURE 1. Cut section of a large granuloma from peritoneal cavity of a raccoon. The lesion is located near the pyloric region of the stomach (S). Note the central area of cavitation which contained necrotic debris.

bacterial colonies with a characteristic Splendore-Hoeppli (immune complex) reaction around them (Fig. 2). The bacterial colonies were surrounded by a thick zone of tightly packed macrophages and neutrophils. These foci were separated from each other by loose fibrovascular connective tissue where many epithelioid macrophages and a lesser number of neutrophils were present. Brown and Brenn-stained preparations contained tightly packed Gram-positive, slender filamentous organisms within Gram-negative amorphous material. On the silver stain the individual slender filamentous nature of the organisms was more obvious and in some areas, the organisms were seen to be branching (Fig. 3). In Ziehl-Neelsen acid-fast preparations the organisms were not stained, but in Kinyoun's acid-fast stain, we observed partially positive organisms.

Other microscopic lesions in this raccoon included a few mineralized blood vessels in the meninges of the brain; cross-sections of a few nematodes resembling *Capillaria* sp. in the mucosa of urinary bladder; a large number of flukes resembling *Euretrema* sp. in the pancreatic ducts; many protozoa resembling *Sarcocystis* sp. in striated muscles (myocardium, masseter muscle, esophagus, diaphragm); and moderate numbers of nematode lar-

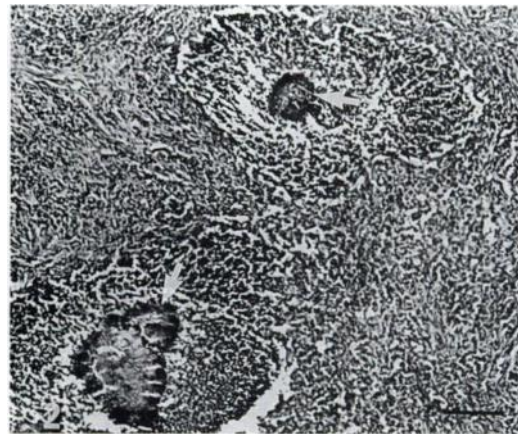


FIGURE 2. Peritoneal granuloma showing multiple bacterial colonies (arrows) surrounded by extensive inflammatory cellular infiltrate. H&E stain. Bar = 100  $\mu$ m.

vae resembling *Trichinella* sp. in the tongue, masseter, and the extra-orbital muscles. All these were considered to be incidental lesions of free-ranging raccoons.

Based on the gross and microscopic lesions a diagnosis of a locally extensive pyo-granulomatous peritonitis was made in this raccoon. With histochemical stains, we observed a slender, filamentous, Gram-positive and partially acid-fast organism within the lesion. Unfortunately fresh tissue from this case was not available for microbiolog-

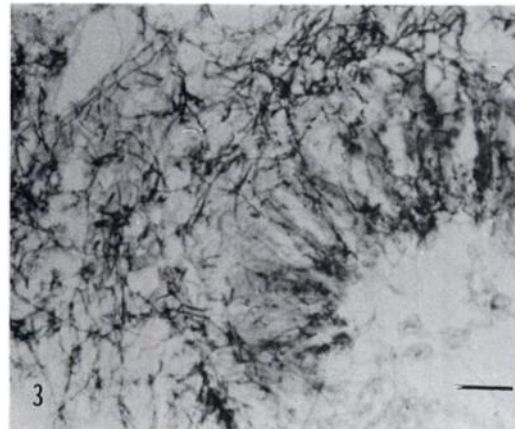


FIGURE 3. Higher magnification of granuloma showing slender filamentous organisms. Gomori's methenamine silver stain. Bar = 50  $\mu$ m.

ical cultures and, therefore, a definitive etiologic diagnosis could not be established. The tinctorial characteristics of the histochemical stains are compatible with *Nocardia* sp. which are classified as actinomycetes whose hyphae rarely exceed 1  $\mu$ m in diameter (Gordon, 1980).

Infections by *Nocardia* spp. have been recorded in humans. In domestic animals the infection has most commonly been described in dogs (Jubb, 1993). It has also been reported in cats, cattle, goats, horses, pigs, birds (Marino and Jaggy, 1993), marine mammals (Sweeney et al., 1976) and in non-human primates (Liebenberg and Giddens, 1985; Jonas and Wyand, 1966). Both generalized and localized forms of the disease (nocardiosis) has been reported in animals (Marino and Jaggy, 1993). In the presently described case the infection was localized in the peritoneum. Similar pyogranulomatous lesions can be seen in the peritoneum of dogs and cats with nocardiosis (Jubb, 1993).

Since the gross pathologic findings of nocardiosis are not pathognomonic, and the granulomas can resemble the lesions of tuberculosis, it is essential to differentiate these lesions by histochemical or other diagnostic tests (Liebenberg and Giddens, 1985).

*Nocardia* spp. are normal soil inhabitants that survive on decaying vegetation (Rippon, 1988). Presumably, infection of animals occurs when the organisms are inhaled or ingested (Liebenberg and Giddens, 1985). Immunocompromised hosts may play a role in nocardiosis (Marino and Jaggy, 1993), but this was not histomorphologically evident in our raccoon. A primary intestinal focus of infection can occur in damaged intestinal mucosae and the infection may extend into the peritoneum to produce extensive granulomatous inflammation (Attleberger, 1980). However, we did not observe an enteric granulomatous

lesion and the peritoneal mass was not attached to the intestine.

This study was supported in part by a grant from the Commonwealth of Pennsylvania, Department of Agriculture. The technical expertise of B. Lehmann and S. Hindmann is greatly appreciated.

#### LITERATURE CITED

- ATTLEBERGER, M. H. 1980. Subcutaneous and opportunistic mycoses, the deep mycoses and the actinomycetes. In *Current veterinary therapy VII*. R. K. Kirk (ed.). Saunders, Philadelphia, Pennsylvania, 486 pp.
- GORDON, M. A. 1980. Aerobic pathogenic *Actinomycetaceae*. In *Manual of clinical microbiology*. E. H. Lennette (ed.). American Society for Microbiology, Washington, D.C., pp. 180–194.
- JONAS, A. M., AND D. S. WYAND. 1966. Pulmonary nocardiosis in the rhesus monkey. *Veterinary Pathology* 3: 599–600.
- JUBB, K. V. F. 1993. The peritoneum and retroperitoneum. In *Pathology of domestic animals*, Vol. 2, 4th ed., K. V. F. Jubb, P. C. Kennedy, and N. Palmer (eds.). Academic Press, Inc., San Diego, California, pp. 425–445.
- LIEBERBERG, S. P., AND W. E. GIDDENS. 1985. Disseminated nocardiosis in three macaque monkeys. *Laboratory Animal Science* 35: 162–166.
- LUNA, L. G. 1968. *Manual of histologic staining methods of the Armed Forces Institute of Pathology*. 3rd. ed. McGraw-Hill Book Company, New York, New York, 258 pp.
- MARINO, D. J., AND A. JAGGY. 1993. Nocardiosis. A literature review with selected case reports in two dogs. *Journal of Veterinary Internal Medicine* 7: 4–11.
- RUPPRECHT, C. E., T. J. WIKTOR, D. H. JOHNSTON, A. N. HAMIR, B. DIETZSCHOLD, W. H. WUNNER, L. T. GLICKMAN, AND H. KOPROWSKI. 1986. Oral immunization and protection of raccoons (*Procyon lotor*) with a vaccinia-rabies glycoprotein recombinant virus vaccine. *Proceedings of the National Academy of Sciences, USA* 83: 7947–7950.
- , C. A. HANLON, A. N. HAMIR, AND H. KOPROWSKI. 1992. Oral wildlife rabies vaccination: Development of a recombinant virus vaccine. *Transactions of the North American Wildlife and Natural Resources Conference* 57: 439–452.
- SWEENEY, J. C., G. MIGAKI, P. M. VAINIK, AND R. H. CONKLIN. 1976. Systemic mycoses in marine mammals. *Journal of the American Veterinary Medical Association* 169: 946–948.

*Received for publication 23 June 1995.*