

Serodiagnosis of Toxoplasmosis in a Common Wombat

Authors: Skerratt, Lee F., Phelan, Jim, McFarlane, Roe, and Speare, Rick

Source: Journal of Wildlife Diseases, 33(2) : 346-351

Published By: Wildlife Disease Association

URL: <https://doi.org/10.7589/0090-3558-33.2.346>

BioOne Complete (complete.BioOne.org) is a full-text database of 200 subscribed and open-access titles in the biological, ecological, and environmental sciences published by nonprofit societies, associations, museums, institutions, and presses.

Your use of this PDF, the BioOne Complete website, and all posted and associated content indicates your acceptance of BioOne's Terms of Use, available at www.bioone.org/terms-of-use.

Usage of BioOne Complete content is strictly limited to personal, educational, and non - commercial use. Commercial inquiries or rights and permissions requests should be directed to the individual publisher as copyright holder.

BioOne sees sustainable scholarly publishing as an inherently collaborative enterprise connecting authors, nonprofit publishers, academic institutions, research libraries, and research funders in the common goal of maximizing access to critical research.

Serodiagnosis of Toxoplasmosis in a Common Wombat

Lee F. Skerratt,^{1,3} Jim Phelan,² Roe McFarlane,² and Rick Speare,^{1,1} Department of Public Health and Tropical Medicine, James Cook University, Townsville, Queensland, 4811, Australia; ² Healesville Sanctuary, P.O. Box 248 Healesville Victoria, 3777, Australia; ³ Author for correspondence and reprints

ABSTRACT: An 8-yr-old captive, female common wombat (*Vombatus ursinus*) from Victoria, Australia was euthanased after an illness of 36 days manifested by lethargy, inappetance and terminal coma with respiratory failure. Toxoplasmosis was diagnosed during life by the *Toxoplasma* direct agglutination test (DAT) which showed a positive initial titre of 1:1,024 at 22 days after onset of illness and a four fold rise in titre to 1:4,098 2 wk later, just prior to death. The *Toxoplasma* modified agglutination test (MAT) remained negative over this time period. The serological diagnosis was confirmed by histological diagnosis of granulomatous encephalitis, focal myocarditis, interstitial pneumonia and severe adrenal cortical necrosis and the presence of tachyzoites of *Toxoplasma gondii* in large numbers within the focal necrotic lesions in the brain, myocardium and adrenal cortices. The serological response in the wombat differed from that of the typical eutherian which exhibits a reaction in both the DAT and MAT within 2 wk of infection with *T. gondii*. An incidental finding was calcification in the media of the ascending aorta and proximal parts of the major arteries.

Key words: *Toxoplasma gondii*, toxoplasmosis, serology, direct agglutination test, modified agglutination test, marsupial, wombat, *Vombatus ursinus*, pathology.

Toxoplasma gondii is a coccidian parasite prevalent worldwide. The cat is the definitive host with man and other warm-blooded animals serving as intermediate hosts. Many animals are infected with the parasite but do not develop overt disease. Herbivores become infected after ingesting plant material contaminated with cat feces containing *T. gondii* oocysts. Marsupials and new world monkeys are the most susceptible animals for developing the clinical disease toxoplasmosis (Dubey and Beattie, 1988). The serological response of Australian macropodidae to *T. gondii* has been studied using ELISA, DAT and MAT (Johnson et al., 1988, 1989; Reddacliff et al., 1993a, b; Lynch et al., 1993), and all three tests appear to have a role in the

diagnosis of infection. The serological response of wombats to *T. gondii* has not been studied. Lesions of toxoplasmosis have been reported from two common wombats (*Vombatus ursinus*) (Canfield et al., 1990).

The serological response together with the pathology in marsupials which do not die of toxoplasmosis within 2 wk of being infected is poorly documented. Johnson et al. (1989) describe the serological response in three eastern grey kangaroos (*Macropus giganteus*). Reddacliff et al. (1993a, b) describe the serology and pathology in two asymptomatic Tammar wallabies (*Macropus eugenii*). However, these wallabies had been dosed with 100,000 oöcysts of *Hammondia hammondi* 42 days prior to challenge with oöcysts of *T. gondii*.

This paper reports the serological diagnosis, using the *Toxoplasma* DAT, of toxoplasmosis in a common wombat based on an initial positive titre of reaction and a four fold rise in titre over a 2 wk period. The diagnosis of toxoplasmosis was confirmed on histological examination of tissues.

An 8-yr-old captive, female, common wombat (*V. ursinus*) at Healesville Sanctuary, Victoria, Australia was euthanased on 10 May 1994 after an illness of 36 days. The wombat had been captured as a sub-adult from Badger Creek (37°40'S, 145°31'E) in 1987. The illness was manifested by lethargy, moderate unresponsiveness and anorexia. In the 36 days between the onset of signs of illness and euthanasia, the wombat's weight decreased from 26.0 to 21.5 kg, its lethargy increased and it responded less to external stimuli. The wombat exhibited a respiratory rate that fluctuated between 40 and a 100 breaths per min in the 17 days prior to death and a

heart rate that steadily increased from 60 to 150 beats per min in the 12 days prior to death. Radiographs taken 22 days after the onset of signs of illness, revealed an alveolar lung pattern and a 7 cm diameter opaque mass in the anterior part of the mediastinum. On the penultimate day of the illness the wombat was slightly ataxic on its hindlegs, became comatose on the next day and was euthanased.

Serum taken on the 26 April 1994, 22 days after the onset of signs of illness, gave a titre of reaction of 1:1,024 in the *Toxoplasma* DAT, there was no reaction in the *Toxoplasma* MAT. (Johnson et al., 1989 lists the for methods of these tests). Serum taken just prior to euthanasia reacted at a titre of 1:4,096 in the DAT. It did not react in the MAT. In eutherians, the DAT measures *T. gondii* specific parasite antibody of all classes apart from IgM (Johnson et al., 1989). Since the wombat serum did not react in the MAT, the DAT presumably measured IgM antibodies, and these had risen four fold over the 2 wk. Treatment with Clindamycin hydrochloride (150 mg capsules) (Antirobe, Upjohn, Rydalmere, NSW, Australia) at 150 mg twice daily was commenced two days prior to euthanasia, but resulted in no clinical response.

At necropsy body condition was very poor. Some subcutaneous fat was present; lungs were dark red and congested; the myocardium was streaked; the aortic arch, brachial arteries and ascending aorta were thickened, calcified and dilated; the kidneys had white streaks in their cortices; and the adrenals had hemorrhagic capsules and cortices. No abnormalities were detected grossly in liver, spleen, gut, bladder and brain. Tissues were fixed in 10% formalin and embedded in paraffin; 6 μ m thick sections were cut and stained with hematoxylin and eosin. In the grey and white matter of the cerebrum, on histological examination, multiple granulomata composed predominantly of histiocytes with a slight lymphocytic component were found (Fig. 1). Some larger granulomas contained necrotic small blood vessels.

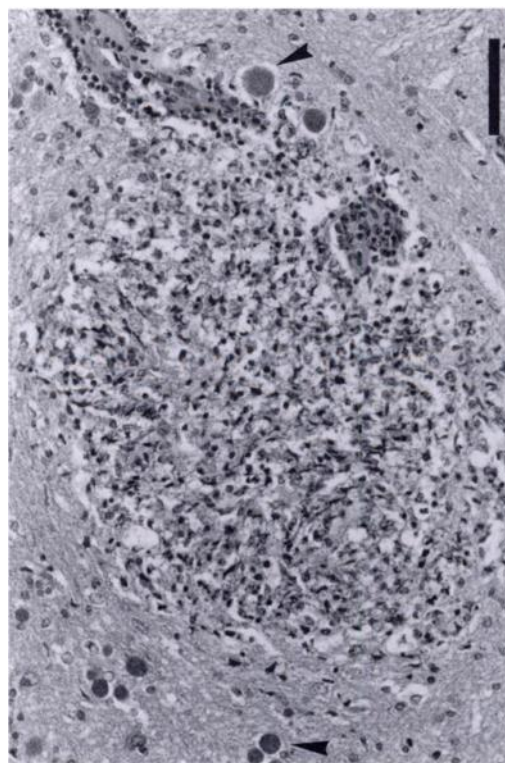


FIGURE 1. Granuloma in the brain of a common wombat (*Vombatus ursinus*) with tissue cysts of *Toxoplasma gondii* (arrows). H&E. Bar = 100 μ m.

Scattered tissue cysts with thin walls (<0.5 mm) typical of *T. gondii* (Canfield, 1990) were seen surrounding these lesions and scattered throughout the brain. Multifocal areas of necrosis containing pyknotic cells, some undergoing karyorrhexis also occurred within the grey and white matter. Numerous tachyzoites were seen individually and in groups within and surrounding these necrotic areas. Many *T. gondii* tissue cysts surrounded the necrotic lesions. Perivascular lymphocytic cuffs were seen occasionally. Cerebellum and brain stem showed similar lesions although the cerebellum was relatively unaffected.

The lung showed severe subterminal alveolar oedema with moderate multifocal inflammation predominantly histiocytic. Moderate numbers of macrophages occurred in alveolar spaces. *Toxoplasma gondii* tissue cysts were occasionally seen. The myocardium contained moderately severe

multifocal interstitial mononuclear inflammation with occasional necrosis and dystrophic calcification. Groups of tachyzoites were sometimes seen within and surrounding these lesions and scattered throughout the myocardium. Extensive areas of the adrenal cortices were hemorrhagic and necrotic with frequent pyknosis and karyorrhexis. Inflammatory cells and many groups of tachyzoites occurred within these areas of necrosis. Severe, diffuse granulomatous inflammation was present within the adrenal medulla.

Skeletal muscle contained a moderate number of small mononuclear inflammatory foci, often with calcified material in their center, and a few scattered *T. gondii* tissue cysts; *T. gondii* organisms were not seen within or near these inflammatory foci. The muscle layer of the small intestine was diffusely necrotic with pyknosis and karyorrhexis of cells. Moderate numbers of inflammatory cells and groups of tachyzoites were scattered within the muscle layer. Small degenerating nematodes measuring (55 to 88 μm \bar{x} = 70, n = 8) in diameter with morphology typical of *Strongyloides spearei* (Skerratt, 1995) occurred in the mucosa. The stomach muscle layer had moderate multifocal inflammation, composed predominantly of eosinophils and macrophages. A few tissue cysts were seen scattered throughout the muscle layer. Moderate multifocal necrosis, inflammation and a few groups of tachyzoites occurred in the muscle layer of the bladder. The liver had small, granulomatous multifocal areas of inflammation. Brown pigment was frequently seen within hepatocytes and macrophages. Mild, multifocal granulomatous inflammation was seen in a sympathetic ganglion. Mesenteric lymph nodes and the spleen showed evidence of lymphoid hyperplasia and some of the germinal centres in the spleen were mildly necrotic.

A moderate proportion of renal cortical tubules were necrotic and contained large calcific deposits. Some tubules had undergone recent necrosis and the debris in the

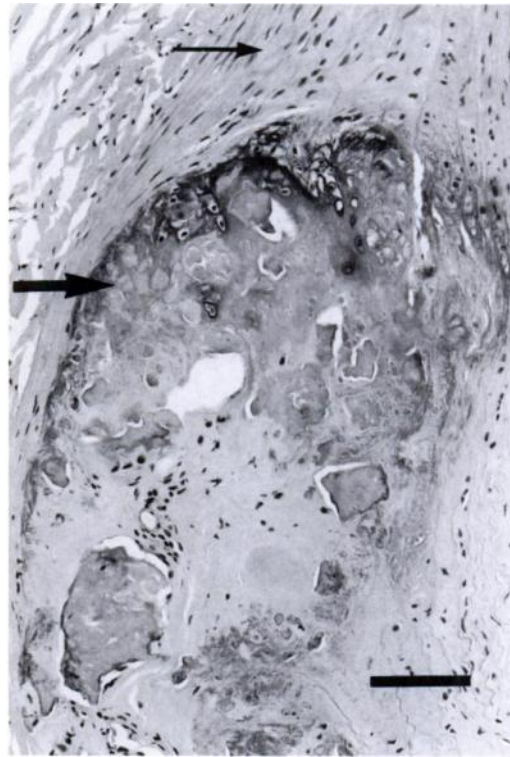


FIGURE 2. Calcification in the media of the brachial artery (thick arrow) of a common wombat (*Vombatus ursinus*). Section of normal artery (thin arrow). Arterial lumen on the right. H&E. Bar = 100 μm .

tubular lumen appeared to be mineralizing. Occasional *T. gondii* tissue cysts were seen, one within a calcific deposit. The brachial artery showed widespread calcification with a chondroid appearance in some areas of its media. The adjacent intima and adventitia were hyperplastic, and the tissue immediately surrounding the calcific deposits was often necrotic and structurally disrupted (Fig. 2). The footpad was normal.

Hematological and biochemical values for the wombat 11 and 22 days after the onset of signs of illness were within or just outside the ranges reported by Presidente (1982). Prior to euthanasia the serum calcium level was 1.30 nmol/L, slightly lower than the range 1.68 to 3.28 nmol/L for normal wombats (Presidente, 1982) and the serum phosphate level of 4.69 nmol/L was slightly higher than the range of 0.84

to 2.55 nmole/L (Presidente, 1982). Other hematological and biochemical values were within the ranges reported by Presidente (1982). The serum level of 25 hydroxyvitamin D was 5 nmol/L just prior to euthanasia. In comparison 52 captive and wild wombats had levels between 0 and 25 nmol/L (Booth, 1994).

The lesions reported in this case are consistent with toxoplasmosis. Canfield et al. (1990) reported that the pathology associated with toxoplasmosis in marsupials was extremely variable. The lesions in this case were within the spectrum described by these authors except for the granulomata in the neural tissues. These have not been reported in marsupials. The usual neurological lesion reported in marsupials is necrosis of neural tissue associated with tachyzoites (Canfield et al., 1990).

Obendorf and Munday (1983) reported pulmonary edema in two Tasmanian pademelons (*Thylogale billardierii*) which died from toxoplasmosis. They suspected that the pulmonary oedema was due to the severe non-suppurative myocarditis. It is possible that the myocarditis in this case impaired cardiac function and contributed to the pulmonary edema. Pulmonary edema also has been reported in Tammar wallabies (*Macropus eugenii*) which died of acute toxoplasmosis and had minimal myocardial lesions (Reddacliff et al., 1993a).

The failure of this wombat to respond to external stimuli and its ataxia on the day before euthanasia may have been clinical signs of the neurological pathology. The lethargy and inappetance exhibited by this animal are not unusual in cases of toxoplasmosis (Canfield et al., 1990).

The wombat did not have a positive reaction in the MAT to *T. gondii* at the time of its death, but it did have a positive reaction to *T. gondii* in the DAT having risen four fold from a titre of 1:1,024 2 wk previously. In comparison a eutherian would normally have had a positive reaction in the MAT and the DAT to a *T. gondii* infection of more than 2 wk duration. Cattle, previously unexposed to *T. gondii*, reacted

at significant titres in the MAT within 15 days of being orally infected with *T. gondii* oocysts (Dubey et al., 1985a). Cattle, goats and sheep, previously unexposed to *T. gondii*, seroconverted in the MAT at a dilution of 1:1,024 within 4 wk of being orally infected with *T. gondii* oocysts (Dubey et al., 1985a, b, 1987).

In this case the marked inflammation in the brain, muscle and heart together with the necrotic lesions and tissue cysts in organs are consistent with a chronic infection in macropodidae (Reddacliff et al., 1993a; Lynch et al., 1993). If this is the case and the wombat did not react in the MAT despite being chronically infected with *T. gondii*, then the immunological response in this wombat towards *T. gondii* infection is markedly different to the immunological response of a eutherian.

Johnson et al. (1989) also report a delayed reaction in the MAT to *T. gondii* infection in three eastern grey kangaroos (*Macropus giganteus*). A reaction was not produced until 20 days after infection. The reaction in the DAT was also delayed with significant reactions occurring 10 days after infection. In Johnson et al. (1989) titres of reaction in the MAT were low with only one animal having a reaction of 1:1,024 by day 50 after infection. Therefore, the results for DAT and MAT for *T. gondii* need to be interpreted with caution when these tests are used in marsupials. The presence of a significant DAT and a negative or low MAT in marsupials does not necessarily mean the infection is very recent.

The thickened, calcified and dilated major vessels, which formed the opaque mass seen radiographically in the mediastinum, may have contributed to the pulmonary oedema. Focal calcific deposits also occurred in the renal cortical tubules. Presidente (1982) reported similar lesions in a common wombat with suspected hypervitaminosis D. Presidente (1982) suggested that the wombat had received excessive vitamin D supplementation. Booth (1994) also suggests hypervitaminosis D as a possible cause of metastatic calcification in

wombats. A study by Fowler and Fraser reported in Booth (1994) which found much lower levels of 25 hydroxyvitamin D and its transport protein in three nocturnal marsupial species compared to eutherians, suggested that 25 hydroxyvitamin D requirements were lower in nocturnal marsupials and therefore they were more susceptible to toxicity. It is possible that this wombat received high levels of vitamin D in its diet in the form of dog food early in its life and from being exposed to long periods of sunlight during its life.

The level of 25 hydroxyvitamin D in the wombat on the 10 May 1994, just prior to its euthanasia, was within the range reported by Booth (1994). This wombat had been kept in a darkened enclosure for the last 30 days of its illness, and also was inappetent in this time. Therefore, the level of 25 hydroxyvitamin D could have been affected by low production and low intake. The half life of 25 hydroxyvitamin in wombats is unknown. In addition the calcification of the renal tubules appeared to be an active process based on tubules appearing histologically to have undergone recent necrosis and mineralisation of debris. This suggests another cause other than hypervitaminosis D for the renal lesions.

Chronic interstitial nephritis has been suggested as a cause of metastatic calcification due to inadequate renal control of calcium and phosphorus levels (see Booth, 1994). Renal function was adequate 14 and 25 days before the wombat's death based on calcium, phosphorus and urea levels being within or just outside the ranges of Presidente (1982). However, abnormal levels of calcium and phosphorus were recorded just before the wombat was euthanased. Therefore, during the 2 wk period prior to the wombat's death, renal function may have been inadequate and calcium and phosphorus levels may have been abnormal, resulting in calcification of renal tubules due to secondary hyperparathyroidism. Alternatively, the calcification in the renal tubules may have been dys-

trophic and the recent necrosis of the tubules could have been due to the *T. gondii* infection.

Medial sclerosis of the aorta has been reported in wild elephants experiencing stress from their environment (Sikes, 1969). Medial sclerosis of the aorta has also been reported in captive and wild marsupials (Fiennes, 1982). Stress may have been a factor in calcification of the major arteries in this wombat.

The staff at Healesville Sanctuary, Dorvitch Pathology, Mt. Pleasant Laboratories in Tasmania, R. Kalnins at the Austin Hospital in Victoria and W. J. Hartley at Taronga Zoo in New South Wales are acknowledged for their work on this wombat. B. L. Munday is thanked for providing advice and assistance with the writing of the manuscript.

LITERATURE CITED

- BOOTH, R. 1994. Monotremes, wombats and bandicoots. University of Sydney, Post Graduate Committee in Veterinary Science Proceedings. *Wildlife* 233: 405-414.
- CANFIELD, P. J., W. J. HARTLEY, AND J. P. DUBEY. 1990. Lesions of toxoplasmosis in Australian marsupials. *Journal of Comparative Pathology* 103: 159-166.
- DUBEY, J. P., G. DESMONTS, C. McDONALD, AND K. W. WALLS. 1985a. Serological evaluation of cattle inoculated with *Toxoplasma gondii*: Comparison of Sabin-Feldman dye test and other agglutination tests. *American Journal of Veterinary Research* 46: 1085-1088.
- , ———, F. ANTUNES, AND C. McDONALD. 1985b. Serologic diagnosis of toxoplasmosis in experimentally infected pregnant goats and transplacentally infected kids. *American Journal of Veterinary Research* 46: 1137-1140.
- , H. P. A. HUGHES, H. S. LILLEHOJ, H. R. GAMBLE, AND B. L. MUNDAY. 1987. Placental transfer of specific antibodies during ovine congenital toxoplasmosis. *American Journal of Veterinary Research* 48: 474-476.
- , AND C. P. BEATTIE. 1988. *Toxoplasmosis of Animals and Man*. CRC Press, Inc., Boca Ron, Florida, 220 pp.
- FIENNES, R. N. T. W. 1982. Stress and diseases of the cardiovascular system. *In* Noninfectious diseases of wildlife, G. L. Hoff and J. W. Davis (eds.). Iowa State University Press, Ames, Iowa, pp. 58-73.
- JOHNSON, A. M., H. ROBERTS, AND B. L. MUNDAY.

1988. Prevalence of *Toxoplasma gondii* antibody in wild macropods. *Australian Veterinary Journal* 65: 199–201.
- , ———, P. STATHAM, AND B. L. MUNDAY. 1989. Serodiagnosis of acute toxoplasmosis in macropods. *Veterinary Parasitology* 34: 25–33.
- LYNCH, M. J., D. L. OBENDORF, P. STATHAM, AND G. L. REDDAKLIFF. 1993. An evaluation of a live *Toxoplasma gondii* vaccine in Tammar wallabies (*Macropus eugenii*). *Australian Veterinary Journal* 70: 352–353.
- OBENDORF, D. L. AND B. L. MUNDAY. 1983. Toxoplasmosis in wild Tasmanian wallabies. *Australian Veterinary Journal* 60: 62.
- PRESIDENTE, P. J. A. 1982. Common wombat *Vombatus ursinus*: maintenance in captivity, blood values, infectious and parasitic diseases. In *The management of Australian mammals in captivity: Proceedings of the Scientific Meeting of the Australian Mammal Society, The Zoological Board of Victoria, Melbourne, Australia*, pp. 133–143.
- REDDACLIFF, G. L., W. J. HARTLEY, J. P. DUBEY, AND D. W. COOPER. 1993a. Pathology of experimentally-induced, acute toxoplasmosis in macropods. *Australian Veterinary Journal* 70: 4–6.
- , S. J. PARKER, J. P. DUBEY, P. J. NICHOLLS, A. M. JOHNSON, AND D. W. COOPER. 1993b. An attempt to prevent acute toxoplasmosis in macropods by vaccination with *Hammondia hammondi*. *Australian Veterinary Journal* 70: 33–35.
- SIKES, S. K. 1969. Habitat and cardiovascular disease: Observations made on elephants, *Loxodonta africana*, and other free-living animals, in East Africa. *Transactions of the Zoological Society of London* 32: 1–103.
- SKERRATT, L. F. 1995. *Strongyloides spearei* n.sp. (Nematoda: Strongyloididae) from the common wombat *Vombatus ursinus* (Marsupialia: Vombatidae). *Systematic Parasitology* 32: 81–89.

Received for publication 11 July 1996.