

GASTRIC SPIRAL BACTERIA AND INTRAMUSCULAR SARCOCYSTS IN AFRICAN LIONS FROM NAMIBIA

Authors: Kinsel, Michael J., Briggs, Michael B., Venzke, Kallie, Forge, Olivia, and Murnane, Robert D.

Source: Journal of Wildlife Diseases, 34(2) : 317-324

Published By: Wildlife Disease Association

URL: <https://doi.org/10.7589/0090-3558-34.2.317>

BioOne Complete (complete.BioOne.org) is a full-text database of 200 subscribed and open-access titles in the biological, ecological, and environmental sciences published by nonprofit societies, associations, museums, institutions, and presses.

Your use of this PDF, the BioOne Complete website, and all posted and associated content indicates your acceptance of BioOne's Terms of Use, available at www.bioone.org/terms-of-use.

Usage of BioOne Complete content is strictly limited to personal, educational, and non - commercial use. Commercial inquiries or rights and permissions requests should be directed to the individual publisher as copyright holder.

BioOne sees sustainable scholarly publishing as an inherently collaborative enterprise connecting authors, nonprofit publishers, academic institutions, research libraries, and research funders in the common goal of maximizing access to critical research.

GASTRIC SPIRAL BACTERIA AND INTRAMUSCULAR SARCOCYSTS IN AFRICAN LIONS FROM NAMIBIA

Michael J. Kinsel,¹ Michael B. Briggs,² Kallie Venzke,³ Olivia Forge,³ and Robert D. Murnane¹

¹ Zoological Pathology Program, University of Illinois College of Veterinary Medicine, Loyola University Medical Center, 2160 South First Avenue, Maywood, Illinois 60153, USA

² Chicago Zoological Society Brookfield Zoo, 3300 Golf Road, Brookfield, Illinois 60513, USA

³ Etosha Ecological Institute, Ministry of Environment and Tourism, Okaukuejo, Republic of Namibia

ABSTRACT: Six juvenile male, one adult male, and three adult female African lions (*Panthera leo*) from Etosha National Park, Republic of Namibia were presented for necropsy. Two of four adults and one of six juveniles had moderate numbers of gastric spiral bacteria. Additionally, four of four adults had sarcocysts. All juveniles had enteric *Sarcocystis* sp. oocysts, but no sarcocysts. The gastric spiral bacteria were located extracellularly in fundic and pyloric glands, and also apparently intracellularly within parietal cells in the fundic region. The organisms were 4 to 8 μm long, 0.63 μm wide, with a periodicity of 0.60 μm . The bacteria had blunted ends with multiple flagella. No periplasmic fibrils were observed. The histologic and ultrastructural characteristics of the bacteria were considered most consistent with species in the genus *Helicobacter* or incompletely identified *Helicobacter*-like organisms. Gastric inflammation did not differ significantly between infected and uninfected individuals. The bacteria may be commensals, or an opportunistic pathogen. The sarcocysts were observed in hindlimb skeletal muscle of four individuals, with one individual also containing a single sarcocyst within glossal musculature. All observed cysts were mature, and were contained within individual myocytes. The cyst wall consisted of a 44 to 66 nm, granular, electron dense parasitophorous membrane with subjacent, 0.8 to 1.3 μm thick, granular and fibrillar ground substance which also extended into the cyst interior as thin septa. The membrane was folded and lined irregularly spaced, 0.8 to 1.3 μm tall villi centrally containing ground substance. The membrane was continuous in the villar projections, but divided into discrete aggregations of the electron dense material between the villi. Bradyzoites within the interior of the cyst were 3 by 12 μm . The sarcocysts were determined to be *Sarcocystis felis* based on the characteristic ultrastructural appearance of the cyst wall.

Key words: African lion, gastric spiral bacteria, *Helicobacter* sp./*Helicobacter*-like organism, *Panthera leo*, *Sarcocystis felis*, sarcocysts.

INTRODUCTION

Gastric spiral bacteria of the genus *Helicobacter* and incompletely identified *Helicobacter*-like organisms (HLO) are Gram negative, tightly coiled, 4 to 10 μm long organisms with bipolar flagella. They have been described in many host species, including man, non-human primates, ferrets (*Mustela putorius*), pigs (*Suis scrofa*), domestic cats (*Felis domesticus*), cheetahs (*Acinonyx jubatus*), a cougar (*Felis concolor*) (Lee et al., 1988; Lee and O'Rourke, 1993; Eaton et al., 1993a; Hill et al., 1997), and various species of small felids (M. J. Kinsel, unpublished data). Most HLO are assumed to be closely related to the type species from man alternately known as *Gastrospirillum hominus* or *Helicobacter heilmanii* (Solnick et al., 1993). Phylogenetic characterization of two human de-

rived organisms indicated they were closely related to *Helicobacter felis* (Solnick et al., 1993), and presumably HLO observed in animals also are related to *Helicobacter* sp. Definitive identification of HLO is hampered by their general failure to grow in vitro, although recent data suggest that in vitro culture is possible if optimal conditions are met (Hanninen et al., 1996). Other procedures which may prove useful for identifying *Helicobacter* spp. or HLO in biopsy or necropsy samples include rapid urease tests, and various molecular biology techniques including in situ hybridization, and the polymerase chain reaction (PCR) (Van den Berg et al., 1989; Valentine et al., 1991; Megraud, 1996).

Both *Helicobacter* spp. and HLO have been observed in domestic and captive felids with gastric inflammation (Eaton et al., 1993a; Geyer et al., 1993; Lee and

O'Rourke 1993; Hermanns et al., 1995; Hill et al., 1997), and positive correlations between gastric spiral bacterial infection and gastritis have been reported (Eaton et al., 1993a, b; Hermanns et al., 1995; Happonen et al., 1996). Additionally, the capacity of related organisms, particularly *Helicobacter pylori* in humans, to incite clinically significant gastric pathology ranging from gastritis to gastric neoplasia is well documented (Dubois, 1995). However, definitive association of gastritis in felids with HLO remains tenuous as controlled pathogenesis studies are lacking, and HLO can be present without gastritis.

To date, study of gastric spiral bacteria has been restricted to domestic, laboratory, and captive species. The incidence and health implications of gastric spiral bacterial infection in free-ranging animal populations remains unknown. However, a widespread distribution similar to that observed in domestic and captive species would seem likely.

Conversely, *Sarcocystis* spp. are a group of Apicomplexan parasites whose worldwide distribution and ability to induce clinically significant disease in domestic, captive, and wild animals are well documented (Fowler, 1986; Dubey et al., 1989; Hullard, 1993). These organisms have a complex life cycle involving sexual reproduction in the intestinal tract of a definitive host, and asexual reproduction culminating in sarcocysts in intermediate hosts. Usually the intermediate host is a prey species, typically a bird or herbivore, while definitive hosts are generally carnivores. However, carnivores can occasionally act as intermediate hosts in the sarcocystis life cycle (Dubey et al., 1989). Presumably the definitive host in this scenario would be a species that at least intermittently engages in scavenging behavior, although no determinations have been made (Greiner et al., 1989). Sarcocysts consistent with, or identified as, *Sarcocystis felis* have been observed in domestic cats (Kirkpatrick et al., 1986; Everitt et al., 1987), cheetahs (Briggs et al., 1993), bob-

cats (*Felis rufus*) (Anderson et al., 1992; Dubey et al., 1992), cougars and Florida panthers (*Felis concolor coryi*) (Greiner et al., 1989), and one African lion (*Panthera leo*) (Dubey and Bwangamoi, 1994). The definitive host for this species has not been determined.

The present study used descriptive methods to document the presence of gastric spiral bacteria and sarcocysts in free-ranging lions from Etosha National Park, Republic of Namibia. Ancillary procedures, such as bacterial culture, rapid urease tests, fecal floatations, and molecular biology methods were not performed due to constraints of field conditions.

MATERIALS AND METHODS

Six 1-yr-old male, one 4-yr-old male, one 7-yr-old female, and two 14-yr-old female African lions from Etosha National Park, Republic of Namibia (19°25'S, 15°45'E) were presented for postmortem examination. Field necropsy procedures were performed 12 to 18 hr postmortem.

Routine, representative samples of all organ systems were collected for histopathology. Tissues were fixed in 10% neutral buffered formalin, processed routinely, embedded in paraffin, sectioned at 5 μ m, and stained with hematoxylin and eosin (H&E). Sections of stomach were also prepared with a modified Steiner silver impregnation (Churukian and Garvey, 1990).

Samples for transmission electron microscopy were identified from H&E slides and removed from paraffin blocks. Tissues were deparaffinized, post-fixed in osmium tetroxide, and embedded in epoxy (Lx112, Ladd Research Industries, Inc., Burlington, Vermont, USA). Thick sections for light microscopy were cut at 0.5 μ m and stained with toluidine blue and basic fuchsin (Hoffmann et al., 1983). Thin sections were cut at 90 nm, stained with lead citrate and uranyl acetate, and examined with a Hitachi H-600 transmission electron microscope (Hitachi, Ltd., Tokyo, Japan) operated at 75 KV.

In the following discussion measured values of organisms and structures are followed by the mean and standard deviation in parentheses.

RESULTS

At necropsy, all carcasses were moderately autolyzed. Gross lesions were limited to gunshot trauma and macroscopic evi-

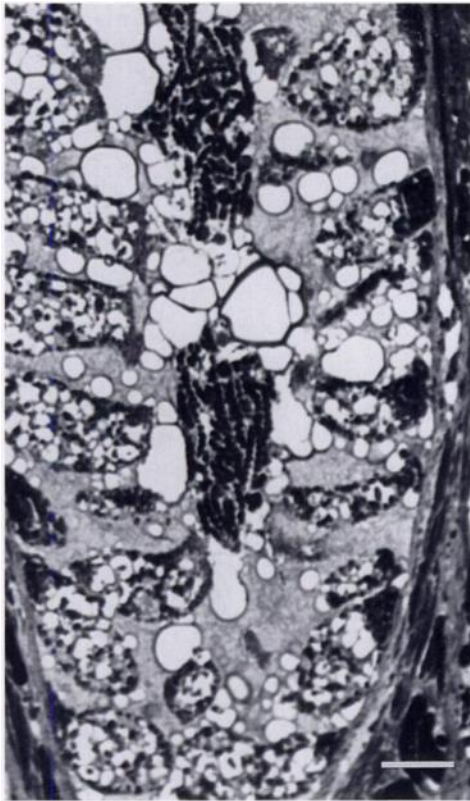


FIGURE 1. Semi-thin plastic section of pyloric stomach of juvenile male African lion showing single crypt with numerous gastric bacteria resembling *Helicobacter* sp./*Helicobacter*-like organisms within lumen. Toluidine blue and basic fuschin. Bar = 8 μ m.

dence of clinically insignificant enteric parasitism.

Histologic sections of pyloric and fundic stomach showed rare to moderate numbers of spiral bacteria in the gastric mucosa of two of four adult lions (one male, one female), and one of six juvenile lions. Gastric tissue was not available for evaluation in one juvenile. The bacteria were 4 to 8 μ m long (5.6, 1.1) and tightly coiled (Fig. 1). In adult lions, the fundus contained small to moderate numbers of organisms apparently within parietal cells and extracellularly in apical aspects of the gastric glands. The pyloric region contained only rare extracellular bacteria in the apical aspects of the gastric glands and in surface debris. Gastric inflammation in both the fundic and pyloric regions con-

sisted of mild to occasionally moderate, multifocal accumulations of lymphocytes and plasma cells in the deep lamina propria. The female also had minimal, diffuse, eosinophil infiltrate in the deep lamina propria, and the male had few, moderate to markedly reactive lymphoid follicles in the pyloric region. Similar inflammation was observed in uninfected adults.

In the juvenile lion, bacteria were most prominent in the pyloric region, and were observed extracellularly in the crypts and mid-zonal aspects of the gastric glands. In the fundus bacteria were rarely observed extracellularly in the apical aspects of the gastric glands and also apparently intracellularly within parietal cells. Gastric inflammation in this individual was limited to occasional, mild to moderate, mid-zonal lymphoplasmacytic aggregations in the pylorus, and few, mildly hyperplastic lymphoid follicles in the fundic region. Uninfected juveniles had similar gastric inflammation.

Ultrastructural evaluation of affected pyloric stomach revealed numerous extracellular spiral bacteria. The bacteria were 0.53 to 0.73 μ m (0.63, 0.05) wide, with a periodicity of 0.50 to 0.67 μ m (0.59, 0.06), with blunted ends, and multiple polar flagella. Periplasmic fibrils were not observed (Fig. 2).

Hematoxylin and eosin sections of hind-limb skeletal muscle in four of four adult lions contained rare to moderate numbers of cysts consistent with *Sarcocystis* sp. One female had a single cyst in glossal musculature. The sarcocysts were 40 by 70 μ m to 50 by 260 μ m, round to ellipsoid, and were located within individual myofibers (Fig. 3). There was no inflammatory reaction associated with these sarcocysts, although one individual did have rare necrotic myocytes with minimal to mild mononuclear inflammation distant to observed sarcocysts. Interestingly, none of the juvenile lions had sarcocysts, but all had large numbers of *Sarcocystis* sp. oocysts within small intestinal lamina propria macrophages. Identification of the oocysts to species was not possible.

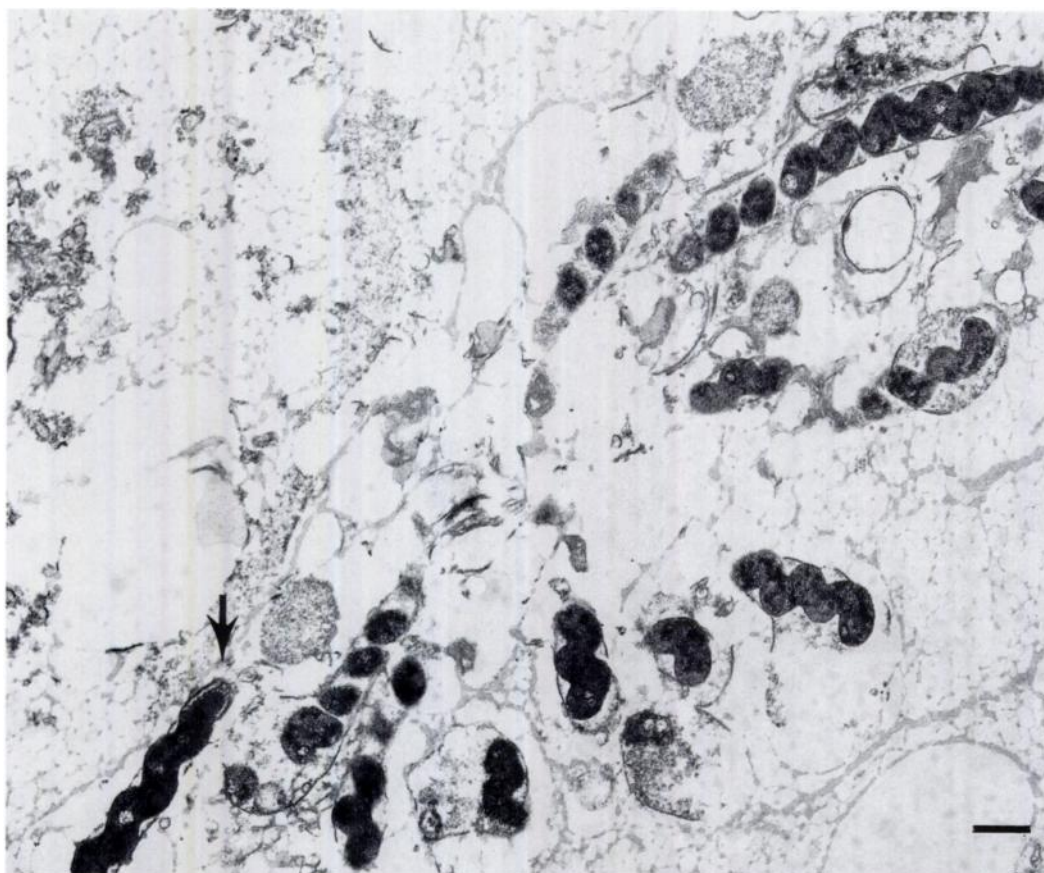


FIGURE 2. Transmission electron micrograph of *Helicobacter* sp./*Helicobacter*-like organism from pyloric stomach of an African lion. The bacteria are tightly coiled, approximately $0.60\ \mu\text{m}$ wide, with a periodicity of $0.60\ \mu\text{m}$, and blunt ended (arrow). Uranyl acetate and lead citrate. Bar = $1\ \mu\text{m}$.

Ultrastructurally, the sarcocysts were mature with a well developed cyst wall (Fig. 4). The cyst wall consisted of a parasitophorous vacuolar membrane with subjacent ground substance. The membrane was comprised of electron dense, granular material 44 to $66\ \text{nm}$ ($56, 11$) thick folded into 0.8 to $1.3\ \mu\text{m}$ ($1.1, 0.2$) tall, irregularly spaced villar projections. The membrane was continuous in the villar projections, but was divided into discrete aggregations of the granular material between the villi. Underlying the membrane was a 0.9 to $2.0\ \mu\text{m}$ ($1.3, 0.4$) thick layer of ground substance comprised of finely granular and fibrillar material which also occupied the central aspect of the villous projections and occasionally extended deep into the

interior of the cyst as thin septa. The cyst wall occasionally had small invaginations at the origins of the septa. The cyst contained numerous, approximately 3 by $12\ \mu\text{m}$ bradyzoites but no merozoites. The ultrastructural appearance of the sarcocysts was consistent with that of *S. felis* (Dubey et al., 1992).

DISCUSSION

Gastric spiral bacteria have been observed in many species including domestic cats and captive felids (Lee et al., 1988; Eaton et al., 1993a; Lee and O'Rourke, 1993; Hill et al., 1997), but the presence or incidence of this class of organism in wild animal populations has not been re-

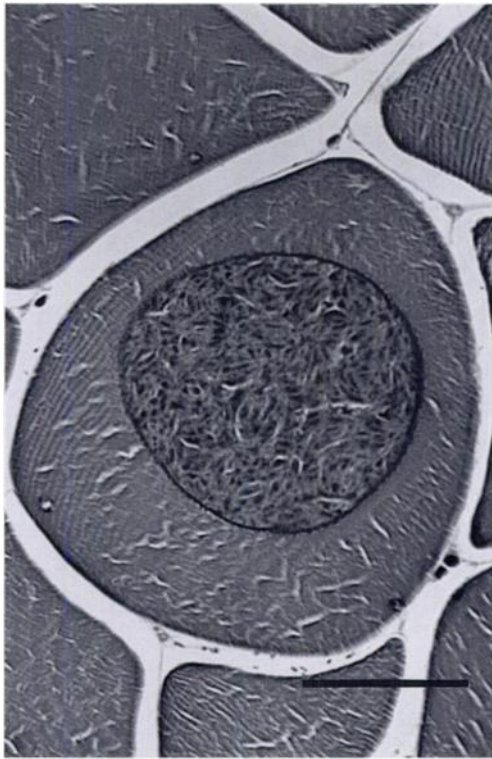


FIGURE 3. *Sarcocystis felis* sarcocyst within an individual myocyte of an African lion. H&E. Bar = 40 μ m.

ported. This is the first report of gastric spiral bacteria in a free-ranging species.

Gastric spiral bacteria have been associated with gastritis in felids, with both *Helicobacter* spp. and HLO implicated (Eaton et al., 1993a, b; Hermanns et al., 1995; Happonen et al., 1996). Mixed *Helicobacter* sp. and HLO infections also have been observed in felids with gastritis (Eaton et al., 1993a; Happonen et al., 1996). However, positive correlations between gastritis and HLO or *Helicobacter* sp. infection are observed only variably in felids (Eaton, et al., 1993a, b; Geyer et al., 1993; Hermanns et al., 1995), and confusion about what level of gastric inflammation constitutes gastritis in felids also complicates interpretation (Happonen et al., 1996). Further association between HLO obtained from felids and their ability to induce gastritis is limited to passage of the organisms into laboratory animals, with re-

sultant gastritis (Eaton et al., 1995). Thus the role of HLO in the development of gastritis in felids remains unclear.

In the lions in this report, gastric spiral bacteria were observed in 3 of 10 individuals, one juvenile, and two adults. All lions examined had similar gastric inflammation regardless of the presence or absence of spiral bacteria. The spiral bacteria may have a commensal relationship with the lion, or may be an opportunistic pathogen. Commensal or opportunistic pathogenic associations between HLO and host species has been suggested previously (Fox and Lee, 1989). Alternatively, the spiral organisms may cause gastritis in only a limited number of infected individuals, which has been observed in other species (Doolley, 1993; Lee and O'Rourke, 1993; Dubois, 1995).

The gastric spiral bacteria in this report are considered morphologically compatible with HLO. Organism length, tight coiling, polar flagellar tufts, and lack of periplasmic fibrils are consistent with previous reports of HLO morphology. Additionally, an affinity for parietal cells has also been reported for HLO (Dubois et al., 1991; Lee and O'Rourke, 1993), and spiral bacteria were occasionally observed apparently within parietal cells in the affected lions.

The possibility of a greater prevalence of infection in this group of lions does exist, as other testing procedures often used for the detection and identification of gastric *Helicobacter* spp. or HLO in support of histologic findings were not utilized in this study. Rapid urease tests, bacterial culture, and PCR can be used to elucidate on the presence of gastric spiral bacteria even in the face of negative histology due to patchy distribution or low numbers of bacteria. Urease tests and bacterial culture were impractical given field conditions, and PCR is not widely available (Jenkins and Bassett, 1997). Additionally, histology remains a highly sensitive test with adequate sample size, and is the only method by which gastritis can be diagnosed (Jenkins and Bassett, 1997).

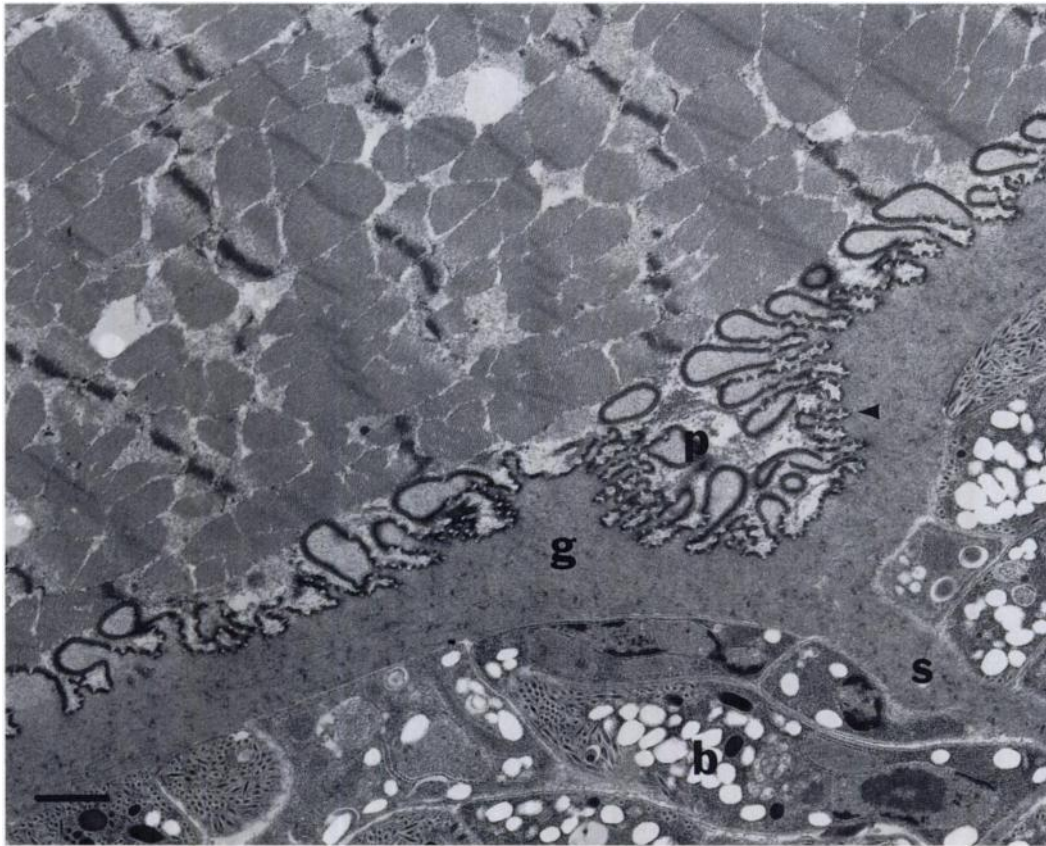


FIGURE 4. Ultrastructural architecture of *Sarcocystis felis* cyst wall from an African lion. Parasitophorous membrane (p) is folded into irregularly spaced villi and consists of discrete aggregates of the electron dense material between villi (arrowhead). Ground substance (g) extends into cyst interior as septa (s). Bradyzoites (b) are present in the cyst interior. Uranyl acetate and lead citrate. Bar = 1 μ m.

Sarcocysts have been previously described in a variety of felids including one African lion (Dubey and Bwangamoi, 1994). Immunosuppression with abnormal or aberrant infection was initially suggested as a cause for sarcocysts in felids (Kirkpatrick et al., 1986; Edwards et al., 1988) but it is now thought that some *Sarcocystis* sp. use carnivores as intermediate hosts in the course of their normal life cycle. The life cycle and transmission of most of these *Sarcocystis* sp. have yet to be determined; however, scavenger species are assumed to be the definitive hosts (Greiner et al., 1989). *Sarcocystis felis* is thought to be one of the species utilizing carnivore intermediate hosts.

Some *Sarcocystis* spp. can be identified

with relative certainty based on ultrastructural characteristics of the cyst wall, including *S. felis* (Dubey et al., 1992). Previous reports where sarcocysts in felids have been described ultrastructurally are all consistent with *S. felis*, which suggests a worldwide distribution. The sarcocysts observed in the lions in this report also were consistent with *S. felis* as determined by ultrastructural architecture of the cysts. Sarcocysts from a springbok (*Antidorcas marsupialis*), a common prey species of the lions in Etosha, were ultrastructurally distinct from the lion sarcocysts (M. J. Kinsel, unpublished data). All lions had markedly reactive lymphoid tissue, suggesting normal immune function, and aberrant migration of a *Sarcocystis* sp. secondary to

immunosuppression was considered unlikely. The *S. felis* sarcocysts were observed in all adult lions, but not in juveniles, implying infection is acquired in maturity, and is widespread in the adult population. Additionally, sarcocysts distinct from *S. felis* have been observed in domestic dogs (*Canis familiaris*), African wild dogs (*Lycaon pictus*), and black-backed jackals (*Canis mesomelas*) in areas of Africa where they have been found also in lions (Bwangamoi et al., 1993; Wesemeier et al., 1995). This may imply that utilization of carnivores as intermediate hosts by *Sarcocystis* spp. is more prevalent than previously suspected.

In summary, gastric spiral bacteria consistent with HLO were observed in 30% of lions examined. To the authors' knowledge this is the first report of gastric spiral bacteria in a free-ranging wild species. No correlation between HLO infection and gastric inflammation could be made. Additionally, sarcocysts consistent with *S. felis* were observed in 40% of the lions examined and 100% of the adults. These findings suggest infection is strongly associated with maturity and common in the adult population. This is the second report of *S. felis* in African lions.

ACKNOWLEDGMENTS

The authors acknowledge the excellent technical assistance of the histopathology and electron microscopy sections of the University of Illinois Laboratories of Veterinary Diagnostic Medicine, and the Ministry of Environment and Tourism, Republic of Namibia. Partial funding for this project was obtained from the Chicago Zoological Society and the University of Illinois College of Veterinary Medicine.

LITERATURE CITED

- ANDERSON, A. J., E. C. GREINER, C. T. ATKINSON, AND M. E. ROELKE. 1992. Sarcocysts in the Florida bobcat (*Felis rufus floridanus*). *Journal of Wildlife Diseases* 28: 116–120.
- BRIGGS, M. B., C. W. LEATHERS, AND W. J. FOREYT. 1993. *Sarcocystis felis* in captive cheetahs (*Acinonyx jubatus*). *Journal of the Helminthological Society of Washington* 60: 277–279.
- BWANGAMOI, O., T. A. NGATIA, AND J. D. RICHARDSON. 1993. Sarcocystis-like organisms in musculature of a domestic dog (*Canis familiaris*) and wild dogs (*Lycaon pictus*) in Kenya. *Veterinary Parasitology* 49: 201–205.
- CHURUKIAN, C. J., AND W. GARVEY. 1990. Microwave Steiner method for spirochetes and bacteria. *Journal of Histotechnology* 13: 45–47.
- DOOLEY, C. P. 1993. Background and historical considerations of *Helicobacter pylori*. In *Gastroenterology clinics of North America, Helicobacter pylori* Infection, Vol. 22, No. 1, C. P. Dooley, and H. Cohen (eds.). W.B. Saunders Co., Philadelphia, Pennsylvania, pp. 1–4.
- DUBEY, J. P., A. N. HAMIR, C. E. KIRKPATRICK, K. S. TODD, JR., AND C. E. RUPPRECHT. 1992. *Sarcocystis felis* sp. n. (Protozoa: Sarcocystidae) from the bobcat (*Felis rufus*). *Journal of the Helminthological Society of Washington* 59: 227–229.
- , C. A. SPEER, AND R. FAYER. 1989. *Sarcocystosis of Animals and Man*. CRC Press, Boca Raton, Florida, 215 pp.
- , AND O. BWANGAMOI. 1994. *Sarcocystis felis* (Protozoa: Sarcocystidae) from the African lion (*Panthera leo*). *Journal of the Helminthological Society of Washington* 61: 113–114.
- DUBOIS, A. 1995. Spiral bacteria in the human stomach: The gastric Helicobacters. *Emerging Infectious Diseases* 1: 79–85.
- , A. TARNAWSKI, D. G. NEWELL, N. FIALA, W. DABROS, J. STACHURA, H. KRIVAN, AND L. M. HEMAN-ACKAH. 1991. Gastric injury and invasion of parietal cells by spiral bacteria in rhesus monkeys. *Gastroenterology* 100: 884–891.
- EATON, K. A., M. J. RADIN, L. KRAMER, R. WACK, R. SHERDING, S. KRAKOWKA, J. G. FOX, AND D. R. MORGAN. 1993a. Epizootic gastritis associated with gastric spiral bacilli in cheetahs (*Acinonyx jubatus*). *Veterinary Pathology* 30: 55–63.
- , ———, AND S. KRAKOWKA. 1993b. Animal models of bacterial gastritis: the role of host, bacterial species and duration of infection on severity of gastritis. *International Journal of Medical Microbiology, Virology, Parasitology and Infectious Diseases* 280: 28–37.
- , ———, AND ———. 1995. An animal model of gastric ulcer due to bacterial gastritis in mice. *Veterinary Pathology* 32: 489–497.
- EDWARDS, J. F., M. D. FICKEN, P. J. LUTTGEM, AND M. S. FREY. 1988. Disseminated sarcocystosis in a cat with lymphosarcoma. *Journal of the American Veterinary Medical Association* 193: 831–832.
- EVERITT, J. I., E. J. BASGALL, S. B. HOOSER, AND K. S. TODD, JR. 1987. *Sarcocystis* sp. in the striated muscle of domestic cats, *Felis catus*. *Proceedings of the Helminthological Society of Washington* 54: 279–281.
- FOWLER, M. E. (ed.). 1986. *Zoo and Wildlife Medicine*. W.B. Saunders Company, Philadelphia, Pennsylvania, 1127 pp.

- FOX, J. G., AND A. LEE. 1989. Gastric *Campylobacter*-like organisms: Their role in gastric disease of laboratory animals. *Laboratory Animal Science* 39: 543–553.
- GEYER, C., F. COLBATZKY, J. LECHNER, AND W. HERMANNNS. 1993. Occurrence of spiral-shaped bacteria in gastric biopsies of dogs and cats. *Veterinary Record* 133: 18–19.
- GREINER, E. C., M. E. ROELKE, C. T. ATKINSON, J. P. DUBEY, AND S. D. WRIGHT. 1989. *Sarcocystis* sp. in muscles of free-ranging Florida panthers and cougars (*Felis concolor*). *Journal of Wildlife Diseases* 25: 623–628.
- HANNINEN, M.-L., I. HAPPONEN, S. SAARI, AND K. JALAVA. 1996. Culture and characteristics of *Helicobacter bizzozeronii*, a new *Helicobacter* sp. *International Journal of Systematic Bacteriology* 46: 160–166.
- HAPPONEN, I., S. SAARI, L. CASTREN, O. TYNI, M.-L. HANNINEN, AND E. WESTERMARCK. 1996. Occurrence and topographical mapping of gastric *Helicobacter*-like organisms and their association with histological changes in apparently healthy dogs and cats. *Journal of Veterinary Medicine* 43: 305–315.
- HERMANNNS, W., K. KREGEL, W. BREUER, AND J. LECHNER. 1995. *Helicobacter*-like organisms: Histopathological examination of gastric biopsies from dogs and cats. *Journal of Comparative Pathology* 112: 307–318.
- HILL, J. E., S. S. KHANOLKAR, AND C. T. K.-H. STADTLANDER. 1997. Gastric ulcer associated with *Helicobacter*-like organism in a cougar (*Felis concolor*). *Veterinary Pathology* 34: 50–51.
- HOFFMANN, E. O., T. R. FLORES, J. COOVER, AND H. B. GARRETT. 1983. Polychrome stains for high resolution light microscopy. *Laboratory Medicine* 14: 779–781.
- HULLAND, T. J. 1993. Muscle and Tendon. In *The Pathology of Domestic Animals*, 4th Edition. K. V. F. Jubb, P. C. Kennedy, and N. Palmer (eds.). Academic Press, Inc. San Diego, California, pp. 183–265.
- JENKINS, C. C., AND J. R. BASSETT. 1997. *Helicobacter* infection. *Compendium on Continuing Education for the Practicing Veterinarian* 19: 267–279.
- KIRKPATRICK, C. E., J. P. DUBEY, M. H. GOLDSCHMIDT, J. E. SAIK, AND J. A. SCHMIDTZ. 1986. *Sarcocystis* sp. in muscles of domestic cats. *Veterinary Pathology* 23: 88–90.
- LEE, A., S. L. HAZELL, J. O'ROURKE, AND S. KOU-PRACH. 1988. Isolation of spiral-shaped bacterium from the cat stomach. *Infection and Immunity* 56: 2843–2850.
- , AND J. O'ROURKE. 1993. Gastric bacteria other than *Helicobacter pylori*. In *Gastroenterology Clinics of North America, Helicobacter pylori* Infection. Vol. 22, No. 1, C. P. Dooley, and H. Cohen (eds.). W.B. Saunders Co., Philadelphia, Pennsylvania, pp. 21–42.
- MEGRAUD, F. 1996. Advantages and disadvantages of current diagnostic tests for the detection of *Helicobacter pylori*. *Scandinavian Journal of Gastroenterology* 31: 57–62.
- SOLNICK, J. V., J. O'ROURKE, A. LEE, B. J. PASTER, F. E. DEWHIRST, AND L. S. TOMPKINS. 1993. An uncultured gastric spiral organism is a newly identified *Helicobacter* in humans. *Journal of Infectious Disease* 168: 379–385.
- VALENTINE, J. L., R. R. ARTHUR, H. L. T. MOBLEY, AND J. D. DICK. 1991. Detection of *Helicobacter pylori* by using the polymerase chain reaction. *Journal of Clinical Microbiology* 29: 689–695.
- VAN DEN BERG, F. M., H. ZIJLMANS, W. LANGENBERG, E. RAUWS, AND M. SCHIPPER. 1989. Detection of *Campylobacter pylori* in stomach tissue by DNA in situ hybridisation. *Journal of Clinical Pathology* 42: 995–1000.
- WESEMEIER, H.-H., K. ODENING, G. WALTER, AND I. BOCKHARDT. 1995. The black-backed jackal (*Carnivora: Canidae*) in Namibia as intermediate host of two *Sarcocystis* species (Protozoa: Sarcocystidae). *Parasite* 2: 391–394.

Received for publication 2 May 1997