

Ectromelia in Morelet's Crocodile from Belize

Authors: Rainwater, Thomas R., McMurry, Scott T., and Platt, Steven G.

Source: Journal of Wildlife Diseases, 35(1) : 125-129

Published By: Wildlife Disease Association

URL: <https://doi.org/10.7589/0090-3558-35.1.125>

BioOne Complete (complete.BioOne.org) is a full-text database of 200 subscribed and open-access titles in the biological, ecological, and environmental sciences published by nonprofit societies, associations, museums, institutions, and presses.

Your use of this PDF, the BioOne Complete website, and all posted and associated content indicates your acceptance of BioOne's Terms of Use, available at www.bioone.org/terms-of-use.

Usage of BioOne Complete content is strictly limited to personal, educational, and non - commercial use. Commercial inquiries or rights and permissions requests should be directed to the individual publisher as copyright holder.

BioOne sees sustainable scholarly publishing as an inherently collaborative enterprise connecting authors, nonprofit publishers, academic institutions, research libraries, and research funders in the common goal of maximizing access to critical research.

Ectromelia in Morelet's Crocodile from Belize

Thomas R. Rainwater,¹ Scott T. McMurry,^{1,3} and Steven G. Platt^{2,1} The Institute of Environmental and Human Health (TIEHH), Department of Biological Sciences, Texas Tech University, 1207 Gilbert Drive, Lubbock, Texas 79416, USA; ² Wildlife Conservation Society, Lamanai Field Research Center, P.O. Box 63, Orange Walk, Belize; ³ Corresponding author (e-mail: smcmurry@ttu.edu)

ABSTRACT: Two Morelet's crocodiles (*Crocodylus moreletii*) captured on 21 March 1997 and 20 April 1998 in the New River system, Belize exhibited ectromelia of one forelimb. External and radiograph examination appears to indicate limb agenesis of unknown etiology, as there is no apparent scarring or skeletal trauma. These two individuals represent the only cases of missing limbs from 642 individuals captured in this study and to our knowledge, the first reported cases in Morelet's crocodile. Several factors including age and diet of the reproducing female, extremes in nest conditions (egg incubation temperature and humidity), and exposure to environmental contaminants can cause developmental abnormalities in crocodilians and may have contributed to the condition observed in these animals. Survival rates for hatchling crocodilians are generally low, and embryonic malformations such as ectromelia may constitute an added disadvantage to survival. However, both individuals examined in this study were vigorous and appeared in good condition.

Key words: Case report, *Crocodylus moreletii*, developmental anomaly, ectromelia, limb agenesis, Morelet's crocodile, traumatic amputation.

Developmental abnormalities in crocodilians have been observed and reported for many years (Ferguson, 1985). Congenital malformations have been found in both wild (Giles, 1948) and captive (Foggin, 1987; Elsey et al., 1994) crocodilians, and some defects have been induced experimentally (Ferguson, 1985). A thorough review of developmental abnormalities in crocodilians up to the mid-1980's with documented cases of central nervous system, craniofacial, skeletal, visceral, and pigment defects is provided by Ferguson (1985). Limb deformities such as supernumerary (extra) limbs, polydactyly (extra digits), ectrodactyly (absent or partially absent digits), or syndactyly (fused digits) have been observed in multiple species (Ferguson, 1985). However, to our knowl-

edge, ectromelia (hypoplasia of the long bones of the limb) has not been reported in crocodilians. We report missing limbs resulting from apparent cases of agenesis in two Morelet's crocodiles (*Crocodylus moreletii*) from different clutches and hatching years captured in Belize.

Morelet's crocodile is a freshwater crocodilian ranging through the Atlantic and Caribbean lowlands of Mexico, Guatemala, and Belize (Thorbjarnarson, 1992). It is currently listed as endangered by the World Conservation Union, International Union for the Conservation of Nature and Natural Resources (IUCN), and is listed on Appendix I of the Convention on International Trade in Endangered Species of Flora and Fauna (CITES) (Groombridge, 1987).

Two crocodiles missing a single forelimb were observed in 642 individual captures, an incidence rate of 0.3%. No other possible malformations were observed in any of the animals. A juvenile crocodile (total length [TL] = 37.0 cm, snout-vent length [SVL] = 18.1 cm, mass = 114 g) was captured on 21 March 1997 in the New River (17°47'N, 88°38'W) of northcentral Belize. On 20 April 1998, a subadult female (TL = 103.7 cm, SVL = 58.0 cm, mass = 3.6 kg) was captured in the New River Lagoon (17°36'N, 88°41'W), approximately 20 km south of the juvenile. Upon capture, we observed the absence of the right and left forelimb of the juvenile and subadult crocodiles, respectively (Figs. 1, 2). Radiographs were made of the animals and they were marked and released at the site of capture. Examination of the radiographs revealed the absence of the entire forelimb including the scapula and procoracoid (Figs. 3, 4), and no discernable superficial scarring or disfigurement sugges-

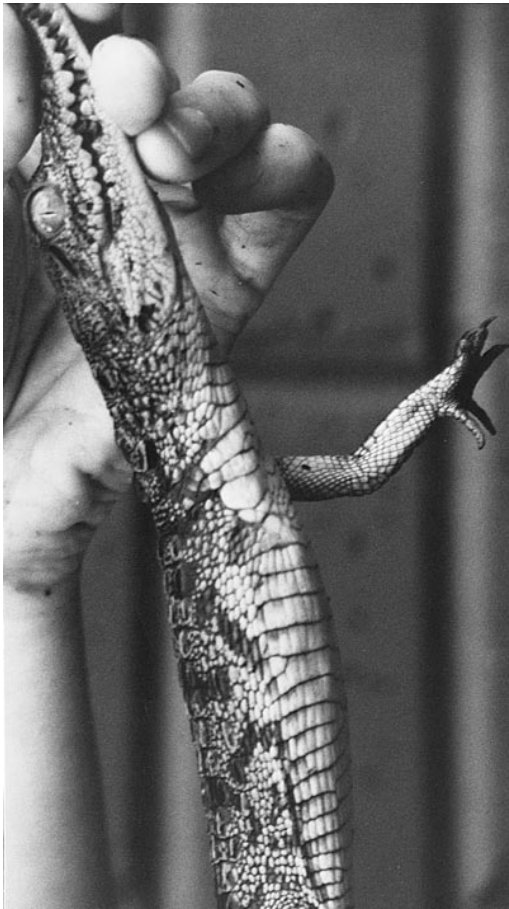

FIGURE 1. Juvenile Morelet's crocodile from Belize missing the right forelimb.

tive of limb loss due to trauma (e.g., bite wound; Figs. 1, 2).

We suspect the missing limbs are a result of agenesis, although we cannot be certain. Congenital limb deformities have been noted in crocodylians (Ferguson, 1985), marine turtles (Miller, 1985), and various amphibian species (Worthington, 1974; Sessions and Ruth, 1990; Ouellet et al., 1997). However, we are unaware of any previous descriptions of ectromelia in crocodylians. We have observed several crocodiles with scars on the head, torso, and limbs as well as missing part of the tail, and in all cases, scars were obvious as disfigurements of the skin and abnormal pigmentation.

Several causes of congenital defects in

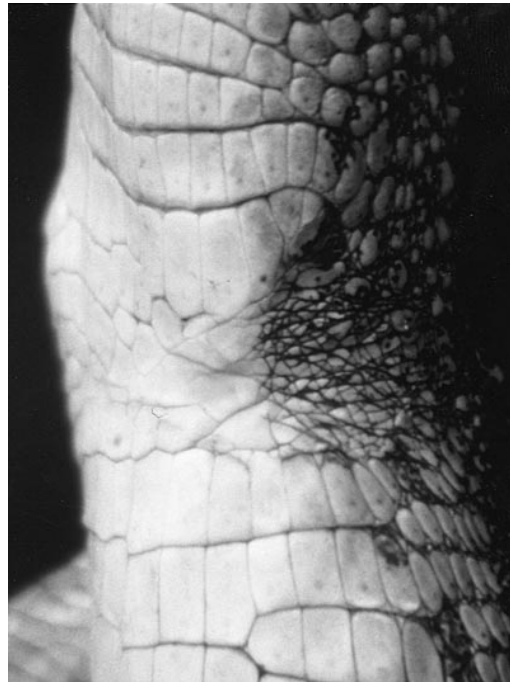


FIGURE 2. Detailed view of a subadult Morelet's crocodile from Belize missing the left forelimb.

crocodylians have been suggested that could contribute to ectromelia. Developmental abnormalities in hatchlings may be related to the age of the reproducing female (Ferguson, 1985). In American alligators (*Alligator mississippiensis*), the incidence of malformed embryos is higher in clutches produced by females ≤ 15 yr and ≥ 30 yr, than those between 15- and 30-yr-old (Ferguson, 1985). Possible causal factors include reduced ovulation in young and old females, immaturity of ova, slight asynchrony between the timing of ovulation and copulation in young females, lower numbers and quality of sperm in males near the end of the breeding season (when young females mate), and poor quality of ova released by old females (Ferguson, 1985). Diet of the reproducing female also may affect normal development of the embryo. Female American alligators fed a diet rich in fish have been shown to produce more deformed young than females fed a diet rich in red meat due to a lack of essential vitamins and trace elements in

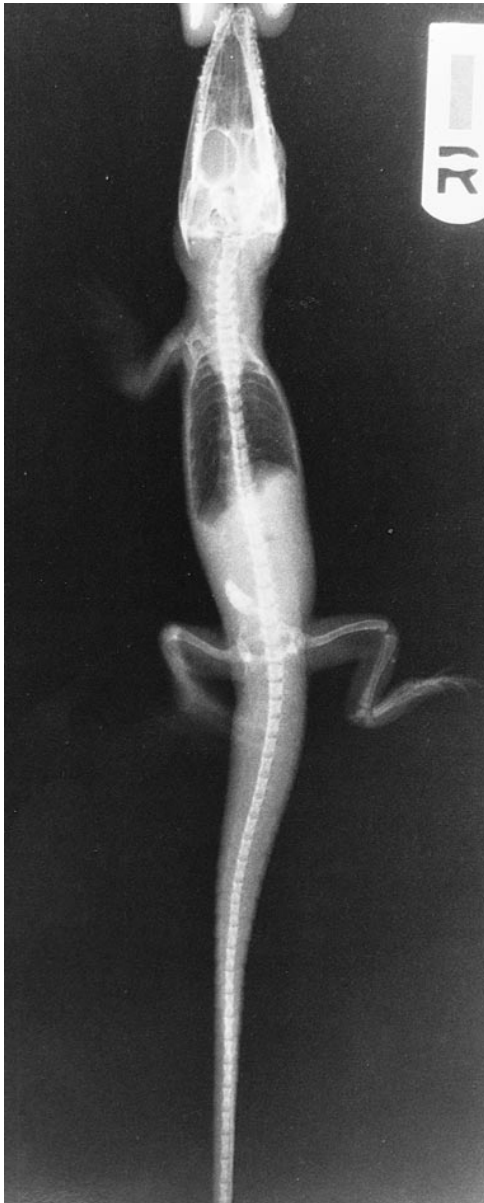

FIGURE 3. Radiograph of juvenile Morelet's crocodile from Belize (ventral view). Note absence of the right forelimb including the scapula and procoracoid.

the fish diet (Ferguson, 1989). Other possibilities include extreme temperatures and humidity in nests during incubation (Ferguson, 1985) and exposure to environmental contaminants, particularly pesticides (Guillette et al., 1994).

Survival among Morelet's crocodile hatchlings is generally low (11%) (Platt,

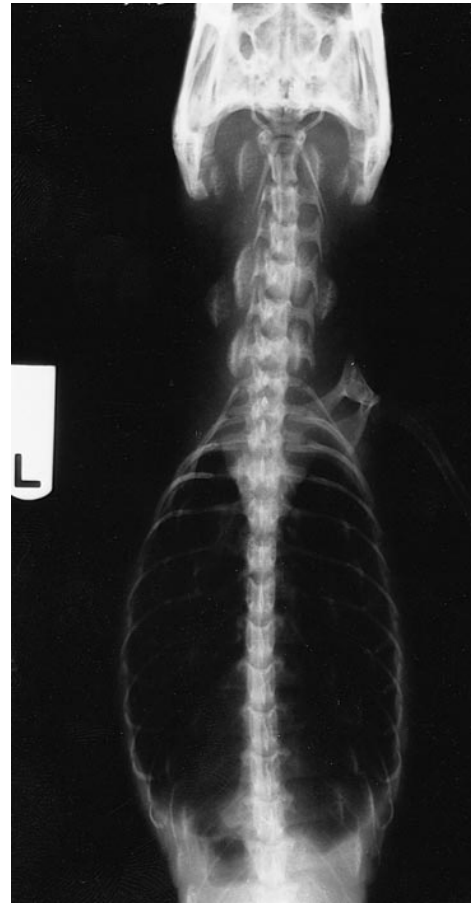

FIGURE 4. Radiograph of subadult Morelet's crocodile from Belize (dorsal view). Note absence of the left forelimb including the scapula and procoracoid.

1996), and the absence of one or more limbs would likely handicap survival by impairing locomotion and the ability to capture prey or avoid predators (Sessions and Ruth, 1990; Ouellet et al., 1997). Both individuals in this study were strong, vigorous, and appeared to be in good condition. The juvenile did however exhibit a greater "light shyness" or wariness (Webb and Messel, 1979) than other juveniles captured, swimming toward cover immediately after being illuminated by the spotlight and approached by the boat. Most juveniles remain still and are easily captured on the first attempt, whereas this crocodile was captured after six attempts in five

nights. We assume the juvenile was the same crocodile missed on previous attempts due to its size and consistent presence in the same location, and because no concurrent observations of other crocodiles were made in the area during the sampling period. Jones (1965) and Webb and Messel (1979) observed that hunting and surveying may induce wariness in crocodilians, thereby increasing the difficulty in recapturing individuals. However, the juvenile crocodile in this study exhibited an escape behavior several times before its first capture. Both crocodiles were recaptured at least once on subsequent nights and found to be vigorous and in good condition.

Mean (\pm SE) hatching date of Morelet's crocodile in northern Belize is September 14 ± 11 days, and mean hatchling size is 26.7 ± 1.3 cm (TL), 12.9 ± 0.5 cm (SVL) at 50.2 ± 5.0 g ($n = 84$) (Platt, 1996). Based on these data, the juvenile crocodile was determined to be a member of the 1996 cohort and approximately 7 to 8 mo of age at the time of capture. Due to the low survival rates of juvenile Morelet's crocodiles (Platt, 1996), it is interesting that either crocodile was able to survive for this length of time given their disadvantage. Both animals appeared healthy and capable of securing food. Stomach contents of the juvenile crocodile were sampled within 24 hr of capture and contained 1 g (wet weight) of various invertebrate parts.

Missing limbs have been previously reported in crocodilians, but to our knowledge only as the result of injury. Saltwater crocodiles (*Crocodylus porosus*) (Webb and Messel, 1977) and Johnston's crocodile (*C. johnstoni*) (Webb and Manolis, 1983) have both been found with absent or partially absent limbs attributed to amputation at rates comparable to that observed in this study (approximately 0.3 to 0.4%). Crocodilians acquire injuries when attacking prey, when attacked by predators, when encountering sharp inanimate objects, and when involved in social con-

flicts with conspecifics (Webb and Messel, 1977; Webb and Manolis, 1983). We observed no individuals missing any part of their limb other than the two reported animals. Given that both individuals in this study showed near identical cases of limb loss with complete absence of all limb bones and no apparent scarring, we believe that these crocodiles exhibited congenital defects.

The authors wish to thank M. and M. Howells of Lamanai Outpost Lodge, Orange Walk, Belize, for accommodations and logistical support during this study. We also thank D. Tanzella, M. Tomola, and J. Williams for clinically evaluating radiographs of the crocodiles. R. Arevalo, T. Crabtree, L. Gonzales, D. Green, M. Mulligan, and J. Torres are thanked for assistance in the field. Support for this project was provided by the Lamanai Field Research Center, Indian Church, Belize and U.S. EPA (Grant No. R826310 to STM). Support for SGP was provided by Wildlife Conservation Society.

LITERATURE CITED

- ELSEY, R. M., T. JOANEN, AND L. MCNEASE. 1994. Ectopia cordis in hatchling *Alligator mississippiensis*. *Herpetological Review* 25: 114–115.
- FERGUSON, M. W. J. 1985. Reproductive biology and embryology of the crocodilians. *In* *Biology of the reptilia*, C. Gans, F. Billet, and P. F. A. Maderson (eds.). John Wiley and Sons, New York, New York, pp. 451–460.
- . 1989. Birth defects in American alligators. *In* *Crocodiles and alligators*, C. A. Ross and S. Garnett (eds.). Facts on File, Inc., New York, New York, p. 98.
- FOGGIN, C. M. 1987. Diseases and disease control on crocodile farms in Zimbabwe. *In* *Wildlife management: Crocodiles and alligators*, G. J. W. Webb, S. C. Manolis, and P. J. Whitehead (eds.). Surrey Beatty and Sons Pty. Ltd., Sydney, Australia, pp. 351–362.
- GILES, L. W. 1948. Polydactylism in an alligator. *Copeia* 214.
- GROOMBRIDGE, B. 1987. The distribution and status of world crocodilians. *In* *Wildlife management: Crocodiles and alligators*. G. J. W. Webb, S. C. Manolis, and P. J. Whitehead (eds.). Surrey Beatty and Sons Pty. Limited, Sydney, Australia, pp. 9–21.
- GUILLETTE, L. J. JR., T. S. GROSS, G. R. MASSON, J.

- M. MATTER, H. F. PERCIVAL, AND A. R. WOODWARD. 1994. Developmental abnormalities of the gonad and abnormal sex hormone concentrations in juvenile alligators from contaminated and control lakes in Florida. *Environmental Health Perspectives* 102: 680–688.
- JONES, F. K. 1965. Techniques and methods used to capture and tag alligators in Florida. *Proceedings of the Annual Conference of the Southeastern Association of Game and Fish Commissions* 19: 98–101.
- MILLER, J. D. 1985. Embryology of marine turtles. *In* *Biology of the reptilia*. C. Gans, F. Billet, and P. F. A. Maderson (eds.). John Wiley and Sons, New York, New York, pp. 269–328.
- OUELLET, M., J. BONIN, J. RODRIGUE, J. DESGRANGES, AND S. LAIR. 1997. Hindlimb deformities (ectromelia, ectrodactyly) in free-living anurans from agricultural habitats. *Journal of Wildlife Diseases* 33: 95–104.
- PLATT, S. G. 1996. The ecology and status of Morelet's crocodile in Belize. Ph.D. Dissertation, Clemson University, Clemson, South Carolina, 187 pp.
- SESSIONS, S. K., AND S. B. RUTH. 1990. Explanation for naturally occurring supernumerary limbs in amphibians. *Journal of Experimental Zoology* 254: 38–47.
- THORBJARNARSON, J. B. 1992. Crocodiles: An action plan for their conservation. H. Messel, F. W. King, and J. P. Ross (eds.). International Union for the Conservation of Nature and Natural Resources (IUCN)/Species Survival Commission (SSC) Crocodile Specialist Group Publication, Gland, Switzerland, 136 pp.
- WEBB, G. J. W., AND C. S. MANOLIS. 1983. *Crocodylus johnstoni* in the McKinlay River area, N.T. V. Abnormalities and injuries. *Australian Wildlife Research* 10: 407–420.
- , AND H. MESSEL. 1977. Abnormalities and injuries in the estuarine crocodile, *Crocodylus porosus*. *Australian Wildlife Research* 4: 311–319.
- , AND ———. 1979. Wariness in *Crocodylus porosus* (Reptilia: Crocodylidae). *Australian Wildlife Research* 6: 227–234.
- WORTHINGTON, R. D. 1974. High incidence of anomalies in a natural population of spotted salamanders, *Ambystoma maculatum*. *Herpetologica* 30: 216–220.

Received for publication 10 March 1998.