

Toxic Nephrosis in Moose in Norway

Authors: Vikøren, Turid, Handeland, Kjell, Stuve, Gudbrand, and Bratberg, Bjørn

Source: Journal of Wildlife Diseases, 35(1) : 130-133

Published By: Wildlife Disease Association

URL: <https://doi.org/10.7589/0090-3558-35.1.130>

BioOne Complete (complete.BioOne.org) is a full-text database of 200 subscribed and open-access titles in the biological, ecological, and environmental sciences published by nonprofit societies, associations, museums, institutions, and presses.

Your use of this PDF, the BioOne Complete website, and all posted and associated content indicates your acceptance of BioOne's Terms of Use, available at www.bioone.org/terms-of-use.

Usage of BioOne Complete content is strictly limited to personal, educational, and non - commercial use. Commercial inquiries or rights and permissions requests should be directed to the individual publisher as copyright holder.

BioOne sees sustainable scholarly publishing as an inherently collaborative enterprise connecting authors, nonprofit publishers, academic institutions, research libraries, and research funders in the common goal of maximizing access to critical research.

Toxic Nephrosis in Moose in Norway

Turid Vikøren,^{1,3} Kjell Handeland,¹ Gudbrand Stuve,¹ and Bjørn Bratberg,^{2,1} Section for Wildlife Diseases, National Veterinary Institute, P.O. Box 8156 Department, N-0033 Oslo, Norway; ² Section for Pathology, National Veterinary Institute, P.O. Box 8156 Department, N-0033 Oslo, Norway; ³ Corresponding author (e-mail: turid.vikoren@vetinst.no).

ABSTRACT: During the summers 1995/96, toxic nephrosis was diagnosed in nine free-living moose (*Alces alces*) from Aust-Agder County in southern Norway. Histopathological kidney lesions included tubular degeneration and necrosis, tubular regeneration, and interstitial fibrosis. The disease was probably caused by ingestion of the toxic plants, bog asphodel (*Narthecium ossifragum*) or oak (*Quercus* spp.).

Key words: *Alces alces*, moose, *Narthecium ossifragum*, nephrotoxicosis, plant toxins, *Quercus* spp., tannins, toxic nephrosis.

Nephrosis caused by various nephrotoxic compounds, is well described in domestic ruminants (Maxie, 1993), whereas little is known about the occurrence in wild ruminants including cervids. During many years of routine diagnostic work at the National Veterinary Institute (Oslo, Norway) nephrosis has been diagnosed occasionally in moose (*Alces alces*), but the cause has not been elucidated. Herein, we report a cluster of toxic nephrosis cases in moose from Aust-Agder County, southern Norway in 1995 and 1996, and discuss a possible cause of the disease.

The cases consist of nine moose found dead or killed in a moribund state during the periods 11 to 27 June 1995/96 ($n = 7$), 8 August 1995 ($n = 1$), and 6 September 1995 ($n = 1$). Five of these were adult females, two were juvenile males, one was a female calf, and the sex and age of one moose was unknown. The animals originated from the following municipalities in Aust-Agder County (Norway): Vegårshei (58°45'N, 08°50'E) ($n = 3$), Froland (58°30'N, 08°42'E) ($n = 1$), Risør (58°40'N, 09°10'E) ($n = 1$), Gjerstad (58°53'N, 09°02'E) ($n = 1$), Grimstad (58°21'N, 08°35'E) ($n = 1$), Arendal (58°27'N, 08°45'E) ($n = 1$), and Åmli (58°42'N, 08°30'E) ($n = 1$).

Field necropsy and sampling of fresh

and formalin-fixed organ specimens for laboratory examination were conducted by local veterinarians. The organs sampled in all cases comprised the kidneys and the liver, and variably included the head and specimens of the lungs, heart, intestine, spleen, and bones. In the laboratory, fresh organs were examined grossly and selected samples were fixed in 10% buffered formalin. Laboratory and field fixed specimens were embedded in paraffin, sectioned at 5 μ m, and stained with hematoxylin and eosin (H&E) for histological examination (Culling et al., 1985). In addition, kidney sections were stained with van Gieson (Culling et al., 1985) and periodic acid-Schiff (Bancroft and Stevens, 1990). Samples of liver and kidney from five moose were digested in a mixture of nitric and perchloric acid, and the cadmium (Cd) and lead (Pb) contents were determined by flame atomic absorption spectroscopy (Frøslie et al., 1986).

The main gross finding was pale kidneys, and some animals also had slightly swollen kidneys. One moose had marked edema in the lungs, the intestinal mesentery, and subcutaneously in the head. Five animals were emaciated.

Histopathological examination of the kidneys revealed tubular epithelial cell degeneration and necrosis (Fig. 1), occasionally with dystrophic calcifications, and eosinophilic material in the tubular lumina. Also, epithelial regeneration, tubular dilation, interstitial fibroblast proliferation, and a moderate focal mononuclear cells infiltration were found to a variable extent (Fig. 2). In the two moose, upon which necropsies were performed in late summer, a marked peritubular and periglomerular fibrosis was evident. No specific extra-renal lesions were found histopatholog-

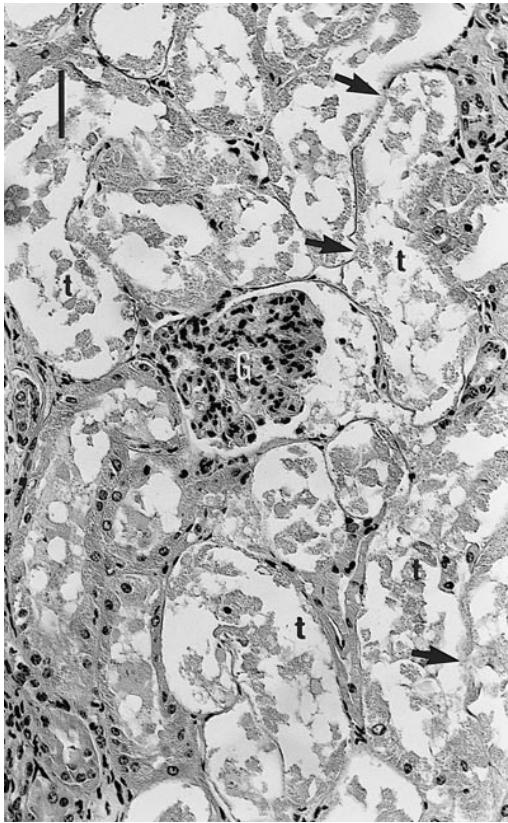


FIGURE 1. Kidney (Glomerulus = G) of a female moose calf with extensive tubular necrosis (t), focal collapse and loss of the tubular basal laminae (arrows). H&E. Bar = 50 μ m.

ically except extensive pulmonary edema in one animal.

All five animals that were analyzed had Pb concentrations below the detection level (<0.5 μ g/g wet weight (WW)). The range of Cd concentration was from <0.1 to 1.9 μ g/g WW in the kidneys and from <0.1 to 2.0 μ g/g WW in the liver.

We conclude that the seven moose upon which necropsies were performed in June 1995-96 had severe acute to subacute nephrosis, whereas the two animals examined in late summer 1995 had severe subacute to chronic renal damage. The renal lesions were extensive in all nine animals and probably lethal.

Of the numerous nephrotoxic compounds described (Maxie, 1993), only a

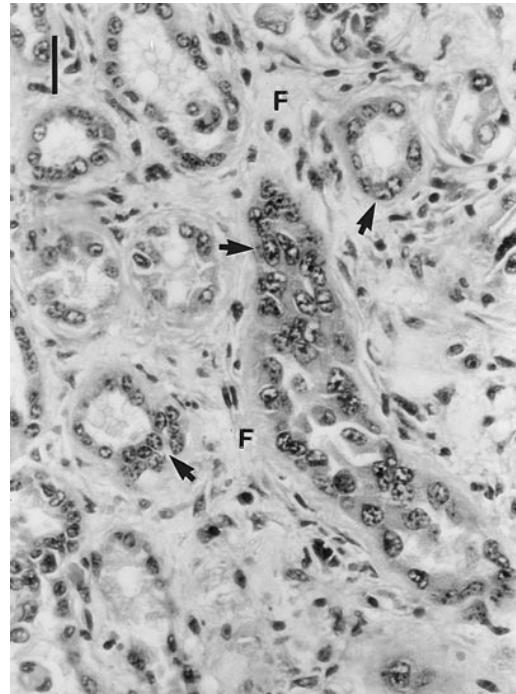


FIGURE 2. Kidney of an adult female moose showing regeneration of tubular epithelium (arrows) and peritubular fibrosis (F). H&E. Bar = 25 μ m.

few are of relevance for free-living moose in Norway. These include heavy metals like Cd and Pb as well as some toxic plants. In the five animals analyzed, Pb was not found and the Cd concentrations were far below nephrotoxic levels (Elinder et al., 1981). Thus, we propose that the renal damage in moose in our study was caused by ingestion of nephrotoxic plants.

The moose population in the two southernmost counties of Norway, Aust- and Vest-Agder, has increased dramatically during the last decades, and has an estimated average population density during winter of 2 to 3 animals/km² (Stuve et al., 1996). As a consequence, there has been an excessive pressure on food resources, and carcass weights and reproduction rates have declined. The most preferred browse has been heavily utilized, forcing moose to feed on other plants, including potentially nephrotoxic ones.

Radiotelemetric studies of the summer browsing of moose in Aust-Agder have

shown that 17 to 33 different plant species are ingested in the period May to August (Danielsen and Olsen, 1994; Damli and Roer, 1995; Bjerga, 1996). Of these plants oak (*Quercus* spp.), bog asphodel (*Narthecium ossifragum*), and field sorrel (*Rumex acetosella*) are reported to be nephrotoxic to domestic ruminants (Humphreys, 1988; Malone et al., 1992; Maxie, 1993; Flåøyen et al., 1995a, b, c). However, the nephrotoxicity of field sorrel is associated with oxalate precipitation in the renal tubules (Maxie, 1993), a finding that did not occur in our material. Therefore, we consider ingestion of oak or bog asphodel the most probable cause of nephrosis in our study. The moose in Aust-Agder commonly ingest large quantities of oak (Danielsen and Olsen, 1994; Damli and Roer, 1995), and some animals also eat large amounts of bog asphodel (Bjerga, 1996). Oak is browsed throughout the year and bog asphodel is eaten from mid-June throughout the rest of the summer (Bjerga, 1996).

Tannins are the potential nephrotoxic substances in acorns, leaves, and buds of oak (Humphreys, 1988). Robbins et al. (1987) conclude that browsing ruminants seem less susceptible to tannin toxicity than do cows and sheep. Kumar and Vaithyanathan (1990) suggest that animals which regularly consume tannin-rich feeds, might have developed a defense mechanism against dietary tannins. Robbins et al. (1987) have found that mule deer (*Odocoileus hemionus*) secrete proline-rich proteins in saliva which constitute the first line of defense against ingested tannins by binding them. However, observed deleterious effects imply that this defense is not capable of handling high quantities of dietary tannins (Kumar and Vaithyanathan, 1990). Acorn poisoning was diagnosed in a fallow deer (*Cervus dama*) that had consumed large amounts of fresh oak acorns (Veal, 1979). We conclude that ingestion of large amounts of fresh oak leaves which are available in early summer, cannot be excluded as a pos-

sible cause of toxic nephrosis in the moose in our study.

Bog asphodel was the probable cause of a large outbreak of nephrotoxicosis in grazing cattle affecting 85 herds along the coast of southern and western Norway in 1992 (Flåøyen et al., 1995c). A similar outbreak was reported in a cattle herd in Northern Ireland in 1989 (Malone et al., 1992). Experimental studies have confirmed nephrotoxic effect of bog asphodel in both cattle (Malone et al., 1992; Flåøyen et al., 1995b), sheep (Flåøyen et al., 1995a), and goats (Flåøyen et al., 1997). The kidney lesions described in these studies were similar to those found by us in moose. In our material, most cases of nephrotoxicosis appeared during the second half of June, when moose have been known to start browsing on bog asphodel in Aust-Agder (Bjerga, 1996). Thus, we suspect bog asphodel is the most probable cause of the nephrosis in these moose. The two animals examined in late summer 1995, showing tubular necrosis accompanied by marked fibrosis, possibly represent cases of gradual renal failure following severe sublethal exposure earlier in the summer, or repeated exposure throughout a longer period of time. The lack of cases with acute nephrosis later in summer, when bog asphodel seems to be an important part of the diet for some individual moose (Bjerga, 1996), could be due to induced tolerance for *N. ossifragum* nephrotoxin. Flåøyen et al. (1995a) found that lambs fed sublethal amounts of bog asphodel for 10 days seemed to develop a tolerance for the toxin. Experimental studies will be performed to clarify whether bog asphodel and oak are nephrotoxic to moose.

We thank the local veterinarians E. Blakstad, F. Jansen, I. Nilsen, E. Ulven, and M. Aartun, who conducted the field necropsies and sampled the material for laboratory examination. Thanks are also due to local wildlife management authorities for their assistance.

LITERATURE CITED

- BANCROFT, J. D., AND A. STEVENS. 1990. Theory and practice of histological techniques, 3rd Edition. Churchill Livingstone, Edinburgh, UK, 726 pp.
- BJERGA, M. 1996. Feeding ecology of moose (*Alces alces*) along an altitudinal gradient in Aust-Agder. M.S. Thesis. University of Oslo, Oslo, Norway, 40 pp. [In Norwegian]
- CULLING, C. F. A., R. T. ALLISON, AND W. T. BARR. 1985. Cellular Pathology Technique, 4th Edition. Butterworth & Co. Ltd., London, UK, 642 pp.
- DAMLI, K. G. S., AND O. A. ROER. 1995. Summer browsing and choice of habitat of moose in Aust-Agder. M.S. Thesis. Agricultural University of Norway, Ås, Norway, 55 pp. [In Norwegian]
- DANIELSEN, I., AND M. OLSEN. 1994. The summer forage of moose in Aust-Agder. M. Sc. Thesis, Agricultural University of Norway, Ås, Norway, 51 pp. [In Norwegian]
- ELINDER, C.-G., L. JØNSSON, M. PISCATOR, AND B. RAHNSTER. 1981. Histopathological changes in relation to cadmium concentration in horse kidneys. *Environmental Research* 26: 1–21.
- FLÅØYEN, A., B. BRATBERG, AND H. GRØNSTØL. 1995a. Nephrotoxicity in lambs apparently caused by experimental feeding with *Nartheicum ossifragum*. *Veterinary Research Communications* 19: 75–79.
- , ———, A. FRØSLIE, AND H. GRØNSTØL. 1995b. Nephrotoxicity and hepatotoxicity in calves apparently caused by experimental feeding with *Nartheicum ossifragum*. *Veterinary Research Communications* 19: 63–73.
- , ———, ———, ———, W. LANGSETH, P. G. MANTLE, AND A. VON KROGH. 1997. Nephrotoxicity in goats caused by dosing with a water extract from the stems of *Nartheicum ossifragum* plants. *Veterinary Research Communications* 21: 499–506.
- , M. BINDE, B. BRATBERG, B. DJØNNE, M. FJØLSTAD, H. GRØNSTØL, H. HASSAN, P. G. MANTLE, T. LANDSVERK, J. SCHÖNHEIT, AND M. H. TØNNESEN. 1995c. Nephrotoxicity of *Nartheicum ossifragum* in cattle in Norway. *Veterinary Record* 137: 259–263.
- FRØSLIE, A., A. HAUGEN, G. HOLT, AND G. NORHEIM. 1986. Levels of cadmium in liver and kidneys from Norwegian cervides. *Bulletin of Environmental Contamination and Toxicology* 37: 453–460.
- HUMPHREYS, D. J. 1988. *Veterinary Toxicology*, 3rd ed., Baillière Tindall, London, UK, 356 pp.
- KUMAR, R., AND S. VAITHIYANATHAN. 1990. Occurrence, nutritional significance and effect on animal productivity of tannins in tree leaves. *Animal Feed Science and Technology* 30: 21–38.
- MALONE, F. E., S. KENNEDY, G. A. C. REILLY, AND F. M. WOODS. 1992. Bog asphodel (*Nartheicum ossifragum*) poisoning in cattle. *Veterinary Record* 131: 100–103.
- MAXIE, M. G. 1993. Nephrotoxic tubular necrosis. *In* Pathology of domestic animals, Vol. 2, 4th Edition, K. V. F. Jubb, P. C. Kennedy, and N. Palmer (eds.). Academic Press Inc., San Diego, California, pp. 489–495.
- ROBBINS, C. T., S. MOLE, A. E. HAGERMAN, AND T. A. HANLEY. 1987. Role of tannins in defending plants against ruminants: Reduction in dry matter digestion? *Ecology* 68: 1606–1615.
- STUVE, G., H. SKAGEMO, B. YTREHUS, AND T. SIVERTSEN. 1996. Osteoporosis in moose (*Alces alces*) in Agder, Norway. Occurrence, manifestation and etiology. *In* Chemical data as a basis of geomedical investigations, J. Låg (ed.). The Norwegian Academy of Science and Letters, Oslo, Norway, pp. 137–144.
- VEAL, V. 1979. Acorn poisoning in fallow deer. *Deer* 4: 417–418.

Received for publication 11 February 1998.