

## **Disseminated Granulomas Associated with Nematode Larvae in a Shortfin Mako Shark**

Authors: Borucinska, Joanna D., and Heger, Katherine

Source: Journal of Wildlife Diseases, 35(1) : 98-100

Published By: Wildlife Disease Association

URL: <https://doi.org/10.7589/0090-3558-35.1.98>

---

BioOne Complete ([complete.BioOne.org](https://complete.BioOne.org)) is a full-text database of 200 subscribed and open-access titles in the biological, ecological, and environmental sciences published by nonprofit societies, associations, museums, institutions, and presses.

Your use of this PDF, the BioOne Complete website, and all posted and associated content indicates your acceptance of BioOne's Terms of Use, available at [www.bioone.org/terms-of-use](https://www.bioone.org/terms-of-use).

Usage of BioOne Complete content is strictly limited to personal, educational, and non - commercial use. Commercial inquiries or rights and permissions requests should be directed to the individual publisher as copyright holder.

---

BioOne sees sustainable scholarly publishing as an inherently collaborative enterprise connecting authors, nonprofit publishers, academic institutions, research libraries, and research funders in the common goal of maximizing access to critical research.

## Disseminated Granulomas Associated with Nematode Larvae in a Shortfin Mako Shark

Joanna D. Borucinska<sup>1,2</sup> and Katherine Heger,<sup>1,1</sup> Department of Biology, University of Hartford, West Hartford, Connecticut, USA; <sup>2</sup> Corresponding Author (e-mail: borucinsk@uhanax.hartford.edu).

**ABSTRACT:** A shortfin mako shark (*Isurus oxyrinchus*) caught in 1996 by sportfishermen in Long Island (New York, USA) had many granulomas containing larval nematodes. Granulomas were present in the myocardium, spleen, pancreas, stomach, spiral intestine, hematopoietic tissue within the anterior kidney, and in the branchial septum and primary lamellae of the gills. Epicardial hyperplasia and granulomatous myocarditis were associated with the larvae. Although identification of the larvae was impossible due to lack of distinct morphological features, they resembled dracunculoid larvae previously reported from sharks.

**Key words:** Case report, dracunculoid like, elasmobranch, *Isurus oxyrinchus*, nematode larvae, parasitic granulomas, shortfin mako shark.

There are few reports of pathology associated with parasitic infections of elasmobranch fishes, although wild sharks are often parasitized (Credille et al., 1993). This report describes pathology associated with parasitic nematode larvae found in tissues of a shortfin mako shark (*Isurus oxyrinchus*) caught in the northern Western Atlantic (41°38'N, 72°00'W) off Long Island (New York, USA) in the summer 1996. The shark was a 72 kg adult male with a fork length of 220.5 cm.

At necropsy multifocal, white, irregular, slightly raised, 0.5 × 0.5 to 1.0 × 1.5 cm, plaques on the epicardium, and multifocal epidermal erosions mostly around the caudal keel associated with the attachment of female *Dinemoura latifolia* (Copepoda) were found. Samples from the heart, gastrointestinal tract, liver, spleen, kidneys, pancreas, hematopoietic tissue, gills, and reproductive organs were fixed in 10% buffered formalin for histological processing. The tissues were embedded in paraffin, sectioned at 4 to 5 μm, and stained with hematoxylin and eosin.

Microscopically the white plaques were

formed by epicardial proliferation with hypertrophic, tall columnar mesothelium overlaying loose connective tissue composed of fine to coarse, amphophilic fibers embedded in a myxoid stroma with occasional stellate or fusiform fibroblasts. Some of these areas were associated with focally diffuse granulomatous myocarditis and parasitic granulomas within the adjacent myocardial corticalis (Fig. 1). The granulomatous inflammation consisted of amorphous eosinophilic debris mixed with lymphocytes, heterophils, and fibroblasts. Although caterpillar or Anitschkow cells, which in mammals are associated with regenerative attempts after myocardial fiber injury (Robinson and Maxie, 1993), were present in the surrounding myocardium, the myocardial fibers appeared normal. Caterpillar cells appear to be a common component of normal myocardium in sharks (Caira et al., 1997).

Parasitic granulomas were present both in the corticalis and spongiosa of the myocardium, with up to four granulomas per low power field in some areas. The granulomas were each centered around cross-sections of a larval nematode, that was 45 to 50 μm in diameter, had a thin (1 μm) cuticle, and two primordial internal organs—one formed by a cluster of round to polygonal eosinophilic cells (digestive tract) and the other seen as clusters of encapsulated basophilic granules (most likely reproductive organs) (Chitwood and Lichtenfels, 1973) (Fig. 2). Each larva was coiled within a 100 × 150 μm space that occasionally contained a small amount of basophilic granular material and was surrounded by a pseudocapsule of flattened cells, probably of host origin. The walls of the granulomas were composed predominantly of fibroblasts arranged in a whirling

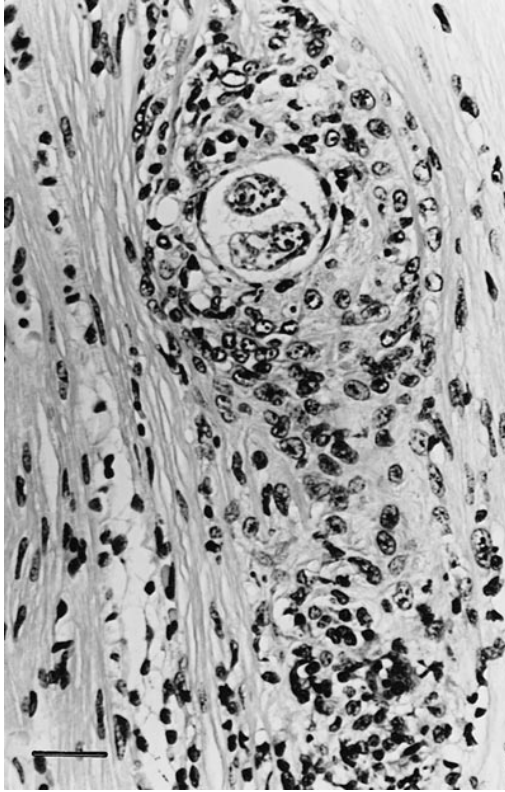


FIGURE 1. Granulomatous myocarditis associated with a parasitic granuloma within the subepicardial corticalis in a mako shark. H&E. Bar = 50  $\mu$ m.

pattern around the pseudocapsules; in addition lymphocytes, histiocytes and rarely heterophils were present. The myocardium also contained round, well delineated, 100  $\times$  200  $\mu$ m, mineralized foci; these were not associated with blood vessels, and represented foci of dystrophic calcification. We do not know if these represent late sequelae to the parasitic granulomas.

Granulomas similar to those in the heart were present within the spleen, hematopoietic tissue in the anterior kidney, pancreas, lamina propria of the stomach, muscularis of the spiral intestine, and primary lamellae, corpus spongiosum and branchial septum of the gills. None of the larvae appeared to be lodged within vasculature, but in some locations, such as the corpus spongiosum within the gills, the granulomatous reaction could have been superimposed on small blood vessels.

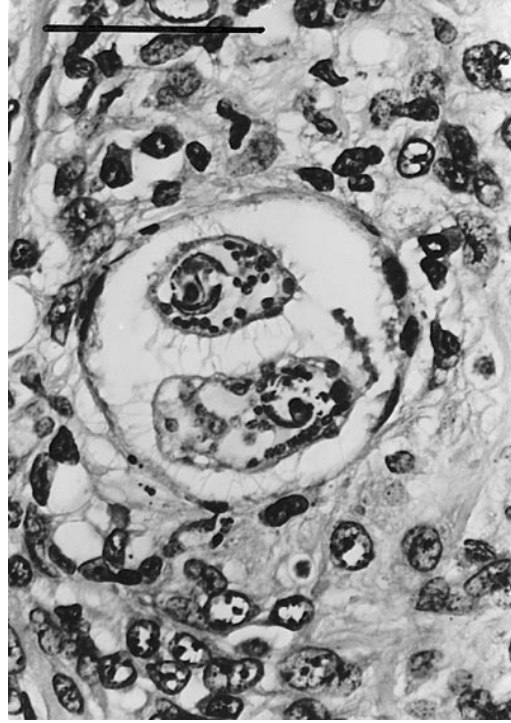


FIGURE 2. Higher magnification of the nematode larva within myocardial corticalis in a mako shark. H&E. Bar = 115  $\mu$ m.

Although morphologically similar, the nematode larva in this shark are larger than nematodes resembling *Phlyctainophora* sp. from an intrauterine nodule in a sandbar shark (*Carcharhinus plumbeus*) (Benz et al., 1987), and Philometrid larvae in granulomas within ovaries of black-tip sharks (*Carcharhinus limbatus*) (Rosa-Molinar et al., 1983). The larvae were similar in size and morphology to larvae classified as belonging to the Superfamily Dracunculoidea that were associated with meningitis and an endocardial nodule in nurse sharks (*Ginglymostoma cirratum*) (Credille et al., 1993). It is possible that the larvae reported here represent a dracunculoid nematode, although the paucity of distinct morphological features makes their classification impossible.

It is unknown if the mako shark was an aberrant intermediate host for these larvae or if it also harbored the adult nematode which was missed during the necropsy.

Adult dracunculoid nematodes have been described from tissue fluids (Moravec and Little, 1988), the subcutis (Mudry and Dailey, 1969; Cheung, 1993), and epidermal and mucosal lesions (Adamson et al., 1987) in sharks, and fragments of an adult dracunculoid nematode were found in the heart of a nurse shark (Adamson and Cairn, 1991).

We did not examine the muscles from the mako shark. Because the mako shark is of high culinary value and fished for commercially, it would be interesting to find out if larvae occur in muscle.

Only a controlled experimental infection could adequately evaluate the clinical effect of the granulomatous myocarditis in this shark. Thus the influence of this parasitic infection on the mortality and morbidity in wild sharks remains uncertain.

We thank the fishermen, organizers, and sponsors of shark fishing tournaments held on Long Island who allowed us to examine and sample their catch, J. G. Casey and N. E. Kohler for facilitating our presence at these tournaments, G. Benz for identification of the cutaneous copepod, and H. Van Kruiningen for his critical review of the manuscript. This study was supported by the grant number 203560 from the Hartford Consortium for Higher Education and by the Coffin Grant (number 203561), from the University of Hartford.

#### LITERATURE CITED

- ADAMSON, M. L., G. B. DEETS, AND G. W. BENZ. 1987. Description of male and redescription of female *Phlyctainophora squali* Mudry and Dailey, 1969 (Nematoda; Dracunculoidea) from elasmobranchs. *Canadian Journal of Zoology* 65: 3006–3010.
- , AND J. N. CAIRA. 1991. *Lockenloia sanguinis* (Nematoda, Dracunculoidea) from the heart of a nurse shark (*Ginglymostoma cirratum*) in Florida. *The Journal of Parasitology* 77: 663–665.
- BENZ, G. W., H. L. PRATT JR., AND M. L. ADAMSON. 1987. Larval philometrid nematodes (Philometridae) from the uterus of a sandbar shark, *Carcharhinus plumbeus*. *Proceedings of the Helminthological Society of Washington* 54: 154–155.
- CAIRA, J. N., G. W. BENZ, J. D. BORUCINSKA, AND N. KOHLER. 1997. Pugnose eels, *Simenchelys parasiticus* (Synaphobranchidae) from the heart of a shortfin mako, *Isurus oxyrinchus* (Lamnidae). *Environmental Biology of Fishes* 49: 139–144.
- CHEUNG, P. 1993. Parasitic diseases of elasmobranchs. In *Fish medicine*, M. K. Stoskopf, (ed.). W. B. Saunders Company, Philadelphia, Pennsylvania, pp. 782–807.
- CHITWOOD, M., AND J. R. LICHTENFELS. 1973. Identification of parasitic metazoa in tissue sections. *Animal Parasitology Institute, Agricultural Research Service, U.S. Department of Agriculture, Beltsville, Maryland*, 112 pp.
- CREDILLE, K. M., L. K. JOHNSON, AND R. REIMSCHUESSEL. 1993. Parasitic meningoencephalitis in nurse sharks (*Ginglymostoma cirratum*). *Journal of Wildlife Diseases* 29: 502–506.
- MORAVEC, F., AND M. D. LITTLE. 1988. *Granulinema* gen. n. A new dracunculoid genus with two new species (*G. carcharini* sp. n. and *G. simile* sp. n.) from the bull shark, *Carcharhinus leucas* (Valenciennes), from Louisiana, USA. *Folia Parasitologica (Praga)* 35: 113–120.
- MUDRY, D. R., AND M. D. DAILEY. 1969. *Phlyctainophora squali* sp. nov. (Nematoda, Philometridae) from the spiny dogfish, *Squalis acanthias*. *Proceedings of the Helminthological Society of Washington* 36: 280–284.
- ROBINSON, W. F., AND M. G. MAXIE. 1993. The cardiovascular system. In *Pathology of domestic animals*. Vol. 3, K. V. F. Jubb, P. C. Kennedy, and N. Palmer (eds.). Academic Press, New York, New York, pp. 1–45.
- ROSA-MOLINAR, E., C. S. WILLIAMS, AND J. R. LICHTENFELS. 1983. Larval nematodes (Philometridae) in granulomas in ovaries of black-tip sharks, *Carcharhinus limbatus* (Valenciennes). *Journal of Wildlife Diseases* 19: 275–277.

Received for publication 13 May 1998.