



Notoedric Mange in Western Gray Squirrels from Washington

Authors: Cornish, Todd E., Linders, Mary J., Little, Susan E., and Vander Haegen, W. Matthew

Source: Journal of Wildlife Diseases, 37(3) : 630-633

Published By: Wildlife Disease Association

URL: <https://doi.org/10.7589/0090-3558-37.3.630>

BioOne Complete (complete.BioOne.org) is a full-text database of 200 subscribed and open-access titles in the biological, ecological, and environmental sciences published by nonprofit societies, associations, museums, institutions, and presses.

Your use of this PDF, the BioOne Complete website, and all posted and associated content indicates your acceptance of BioOne's Terms of Use, available at www.bioone.org/terms-of-use.

Usage of BioOne Complete content is strictly limited to personal, educational, and non - commercial use. Commercial inquiries or rights and permissions requests should be directed to the individual publisher as copyright holder.

BioOne sees sustainable scholarly publishing as an inherently collaborative enterprise connecting authors, nonprofit publishers, academic institutions, research libraries, and research funders in the common goal of maximizing access to critical research.

Notoedric Mange in Western Gray Squirrels from Washington

Todd E. Cornish,^{1,5,6} Mary J. Linders,² Susan E. Little,³ and W. Matthew Vander Haegen⁴ ¹ Southeastern Cooperative Wildlife Disease Study, College of Veterinary Medicine, The University of Georgia, Athens, Georgia 30602, USA; ² University of Washington, Wildlife Science Group, Box 352100, Seattle, Washington 98195-2100, USA; ³ Department of Medical Microbiology and Parasitology, College of Veterinary Medicine, The University of Georgia, Athens, Georgia 30602, USA; ⁴ Washington Department of Fish and Wildlife, 600 Capitol Way North, Olympia, Washington 98501, USA; ⁵ Present address: Department of Veterinary Sciences, Wyoming State Veterinary Laboratory, University of Wyoming, 1174 Snowy Range Road, Laramie, Wyoming 82070, USA; ⁶ Corresponding author (e-mail: tcornish@uwyo.edu).

ABSTRACT: From February 1998 to July 1999, 65 western gray squirrels (*Sciurus griseus griseus*) were trapped at three sites in Klickitat County, Washington (USA) as part of a home range and habitat use study. No squirrels (0/9) with mange lesions were identified in the initial trapping session (February and March 1998). During all subsequent trapping sessions (August 1998 through July 1999), squirrels with lesions consistent with notoedric mange, caused by the mite *Notoedres centrifera (douglasi)*, were captured or recaptured at all three study sites. The diagnosis was confirmed by histopathology and examination of mites obtained from skin scrapings from two affected squirrels. Of the 56 squirrels captured from August 1998 to July 1999, 33 (59%) had characteristic mange lesions, and 14 (42%) affected squirrels died directly of mange or of secondary complications of mange. Only four breeding females of 22 radio-collared animals (males and females) in the study population were known to have survived the mange outbreak (12 died, 6 missing). Factors potentially contributing to this mange outbreak include a mast crop failure in the fall of 1998 and transmission of mites from animal to animal during trapping and processing sessions.

Key words: *Notoedres centrifera (douglasi)*, notoedric mange, *Sciurus griseus griseus*, western gray squirrel.

Notoedric mange, caused by the mite *Notoedres centrifera (douglasi)* (Lavoipierre, 1964; Klompen, 1992), has been described in several squirrel species in the United States including the western gray squirrel (*Sciurus griseus griseus*) (Bryant, 1921), the eastern gray squirrel (*Sciurus carolinensis*) (Carlson et al., 1982), and the fox squirrel (*Sciurus niger*) (Kazacos et al., 1983). Although most cases of notoedric mange in squirrels have been limited to isolated events affecting individuals or small groups of animals, one significant

epizootic associated with considerable morbidity and mortality has been reported. In the Eldorado National Forest in California an outbreak of notoedric mange nearly decimated a local population of western gray squirrels in 1921, with numerous dead squirrels found at bases of trees and in streams. Death was attributed largely to emaciation caused by mange lesions around the eyes interfering with vision and normal foraging behaviors (Bryant, 1921, 1926). This report describes a similar outbreak of notoedric mange in a population of western gray squirrels from Washington.

Western gray squirrels were trapped for a home range and habitat use study in three different areas within Klickitat County, Washington (45°50'N, 121°00'W) from February 1998 to July 1999. Tomahawk live traps (number 204, Tomahawk Live Trap Co., Tomahawk, Wisconsin, USA) were used and animals ≥ 675 g were anesthetized with isoflurane using an inhalation cone, examined, ear tagged in both ears (size 1005-1 tags, National Band and Tag Co., Newport, Kentucky, USA), and fitted with radio collars (model RI-2Csp or SI-2C, Holohil Systems, Ltd., Carp, Ontario, Canada). During the initial trapping period (February and March 1998) 0/9 squirrels captured at one site demonstrated mange lesions. Beginning in August 1998 and continuing through July 1999 squirrels from all three trapping sites were captured or recaptured having lesions consistent with notoedric mange. After the initial trapping session, 56 squirrels were captured and of this total 33 (59%) had lesions consistent with mange. Of the

33 affected squirrels, seven were eventually found dead and presumed to have died from mange, and seven carcasses or partial remains with necropsy evidence of predation were found. In the predation cases it was assumed that mange contributed to increased susceptibility, based upon repeated field observations of abnormal flight behavior, decreased activity, incoordination, and emaciation associated with advancing mange lesions. Two additional squirrels that were never trapped or handled also were found dead with severe mange lesions during the trapping and telemetry sessions (one drowned, one found dead at the base of a tree). Of 22 radio-collared squirrels (males and females) in the initial study group, only four breeding females were known to have survived the mange outbreak. Radio-collared males appeared to be affected with mange more commonly over the entire course of the study, with 14/18 (78%) displaying lesions consistent with mange versus 9/22 (41%) collared females.

Two squirrels (one male, one female) with typical lesions suggestive of notoedric mange were submitted to the Southeastern Cooperative Wildlife Disease Study (College of Veterinary Medicine, The University of Georgia, Athens, Georgia, USA) for examination. Both squirrels had been found dead at the bases of trees during the trapping sessions, and both squirrels had been captured and ear tagged before death. Both animals were mature adults, and each was nearly emaciated with patchy to extensive alopecia affecting the ears, head, dorsal trunk, and tail (Fig. 1). Alopecic areas of skin were thickened, corrugated, and often were covered by adherent tan crusts. In one squirrel, the ears adjacent to the ear tags were most severely affected, whereas the distribution of lesions was more widespread in the second squirrel. Representative samples of skin were fixed in 10% neutral buffered formalin, embedded in paraffin, sectioned at 3–4 μm , stained with hematoxylin and eosin, and examined by light microscopy. Mi-

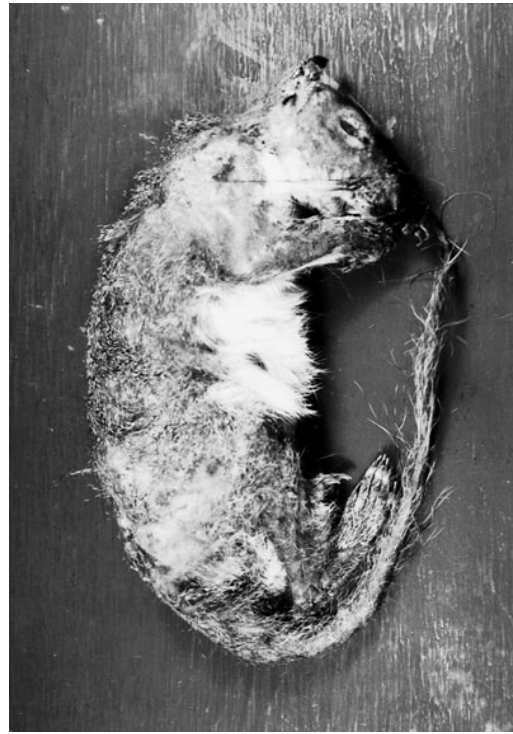

FIGURE 1. Representative case of notoedric mange in a western gray squirrel, with patchy alopecia of the ears, head, trunk, and tail.

croscopic lesions consisted of extensive epidermal hyperplasia (acanthosis) with both orthokeratotic and parakeratotic hyperkeratosis. There were multifocal erosions and ulcers in affected epidermis with extensive serocellular crusting, together with numerous intracorneal and intraepidermal tunnels containing sections of mites (Fig. 2). In the dermis of both squirrels there were light perivascular and interstitial infiltrates of neutrophils, lymphocytes, plasma cells, and macrophages with multifocal regions of dermal fibrosis. Skin scrapings revealed numerous adult mites (females 186–250 μm \times 122–181 μm ; males 128–142 μm \times 98–118 μm), eggs (128–142 μm in length), and mite feces. The mites were identified as *Notoedres centrifera (douglasi)* according to the descriptions of Lavoipierre (1964) and Klompen (1992). Representative specimens were deposited in the U.S. National Parasite Collection (Beltsville, Maryland,

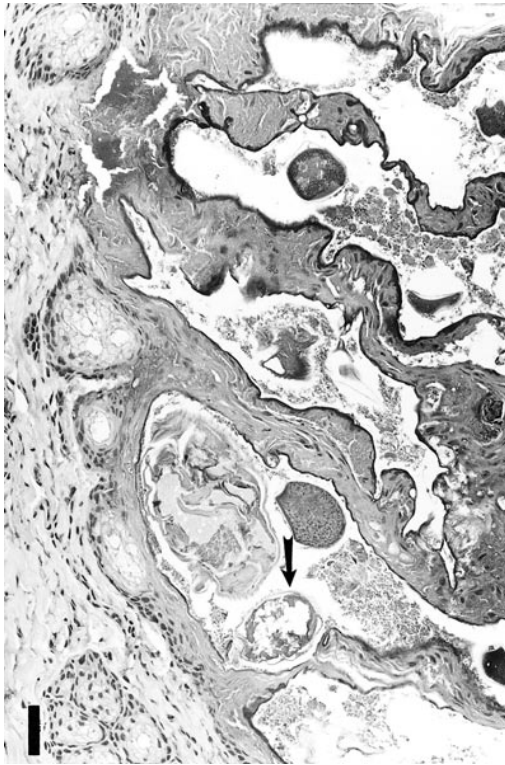


FIGURE 2. Section of skin from a western gray squirrel with notoedric mange demonstrating mites within tunnels in the epidermis (arrow). H&E. Bar = 100 μ m.

USA; Accession number 089192.00). The cause of death for both squirrels was emaciation.

This outbreak of notoedric mange appears to have significantly impacted the local western gray squirrel population within the study sites in Klickitat County (M. J. Linders, unpubl. data). The western gray squirrel is listed as threatened in Washington (Washington Department of Fish and Wildlife, 1999) and generally reproduces at a much lower rate than the related eastern gray squirrel, making the loss of a large part of a local population a significant event. The cause of this outbreak remains unknown, but several factors may have played contributory roles. The first factor was a mast crop failure in the fall of 1998 (M. J. Linders, unpubl. data). Poor nutritional status and stress appear capable of increasing the severity of mange in squir-

rels and other animals (Lavoipierre, 1964; Carlson et al., 1982); mast crop failure and limitations of other essential resources (such as suitable habitat) also could facilitate transmission of mites from animal to animal by increasing dispersal, emigration, and contact between hosts (Valenzuela et al., 2000). A second factor potentially involved in this mange outbreak was the trapping and processing of the squirrels. *Notoedres* spp. mites are transmitted from animal to animal by direct contact and potentially by contact with recently contaminated bedding and fomites on equipment or in the environment. Whether transmission or development of clinical diseases was facilitated in these trapped squirrels by ear tagging or trapping equipment is unknown. Mange lesions were observed in several squirrels that had never been trapped or handled, and similar lesions were observed in several squirrels at initial capture (prior to handling and ear tagging). Efforts to prevent subsequent transmission during trapping, handling, and ear tagging were implemented after this outbreak of mange began, including cleaning trapping and tagging equipment between squirrels, use of disposable gloves, use of disposable paper filters in anesthesia masks, and other precautions. Similar protocols are encouraged for other investigators in the future whenever squirrels are captured and handled.

An important question that remains unanswered is whether *Notoedres* mites are endemic in this squirrel population (and other affected populations), with disease cycling at periodic intervals, or are introduced by immigrating squirrels or other sources. A similar outbreak of notoedric mange was observed in another rodent species, the white-footed mouse (*Peromyscus leucopus*), on Nantucket Island (Massachusetts, USA) in 1995, after 10 years of trapping without detecting mange lesions. The author of this report speculated that such infestations may exist in small, easy to miss, circumscribed foci and that variations in host and parasite populations may

lead to periodic intensification of cycles of transmission and development of disease (Telford, 1998).

This work was supported by funding from the Washington Department of Fish and Wildlife, the U.S. Fish and Wildlife Service, the Washington Department of Natural Resources, Champion Pacific Timberlands Incorporated, and through sponsorship from the fish and wildlife agencies of Alabama, Arkansas, Florida, Georgia, Kansas, Kentucky, Louisiana, Maryland, Mississippi, Missouri, North Carolina, Puerto Rico, South Carolina, Tennessee, Virginia, and West Virginia. Funds were provided by the Federal Aid to Wildlife Restoration Act (50 Stat. 917) and through Grant Agreement 1445-GT09-96-0002, U.S. Geological Survey, U.S. Department of the Interior.

LITERATURE CITED

- BRYANT, H. C. 1921. Tree squirrels infested with scabies. *California Fish and Game* 7: 128.
- . 1926. Gray squirrel disease still exists. *California Fish and Game* 11: 205–206.
- CARLSON, B. L., D. P. ROHER, AND S. W. NIELSEN. 1982. Notoedric mange in gray squirrels (*Sciurus carolinensis*). *Journal of Wildlife Diseases* 18: 347–348.
- KAZACOS, E. A., K. R. KAZACOS, AND H. A. DEMAREE, JR. 1983. Notoedric mange in two fox squirrels. *Journal of the American Veterinary Medical Association* 11: 1281–1282.
- KLOMPEN, J. S. H. 1992. Phylogenetic relationships in the family Sarcoptidae (Acari: Astigmata). *Miscellaneous Publications, Number 180, Museum of Zoology, University of Michigan, Ann Arbor, Michigan*, 159 pp.
- LAVOPIERRE, M. M. J. 1964. Mange mites of the genus *Notoedres* (Acari: Sarcoptidae) with descriptions of two new species and remarks on notoedric mange in the squirrel and the vole. *Journal of Medical Entomology* 1: 5–17.
- TELFORD, S. R., III. 1998. Focal epidemic of sarcoptid (Acarina: Sarcoptidae) mite infestation in an insular population of white-footed mice. *Journal of Medical Entomology* 35: 538–542.
- VALENZUELA, D., G. CEBALLOS, AND A. GARCIA. 2000. Mange epizootic in white-nosed coatis in western Mexico. *Journal of Wildlife Diseases* 36: 56–63.
- WASHINGTON DEPARTMENT OF FISH AND WILDLIFE. 1999. Priority habitats and species (PHS) list and species of concern (SOC) list. Washington Department of Fish and Wildlife, Olympia, Washington, 31 pp.

Received for publication 11 August 2000.