



## **Microscopic Evidence of Adenoviral Infection in a Muskrat in Illinois**

Authors: Webb, Dale M., and Woods, Leslie W.

Source: Journal of Wildlife Diseases, 37(3) : 643-645

Published By: Wildlife Disease Association

URL: <https://doi.org/10.7589/0090-3558-37.3.643>

---

BioOne Complete ([complete.BioOne.org](https://complete.BioOne.org)) is a full-text database of 200 subscribed and open-access titles in the biological, ecological, and environmental sciences published by nonprofit societies, associations, museums, institutions, and presses.

Your use of this PDF, the BioOne Complete website, and all posted and associated content indicates your acceptance of BioOne's Terms of Use, available at [www.bioone.org/terms-of-use](https://www.bioone.org/terms-of-use).

Usage of BioOne Complete content is strictly limited to personal, educational, and non - commercial use. Commercial inquiries or rights and permissions requests should be directed to the individual publisher as copyright holder.

---

BioOne sees sustainable scholarly publishing as an inherently collaborative enterprise connecting authors, nonprofit publishers, academic institutions, research libraries, and research funders in the common goal of maximizing access to critical research.

## Microscopic Evidence of Adenoviral Infection in a Muskrat in Illinois

Dale M. Webb<sup>2,3</sup> and Leslie W. Woods,<sup>1</sup> <sup>1</sup> California Animal Health and Food Safety Laboratory System, School of Veterinary Medicine, University of California, Davis, Davis, California 95616, USA; <sup>2</sup> Galesburg Animal Disease Laboratory, Illinois Department of Agriculture, 2100 South Lake Storey Road, Galesburg, Illinois 61401, USA; <sup>3</sup> Corresponding author (e-mail: dmwebb@gallatinriver.net).

**ABSTRACT:** A wild muskrat (*Ondatra zibethicus*) found moribund in Illinois (USA) had minimal meningitis and pleuritis, probably of bacterial origin. There were large, basophilic, intranuclear inclusion bodies within scattered enterocytes. The inclusions were microscopically typical of those produced by adenoviruses, and ultrastructurally were intranuclear paracrystalline arrays of virus particles with characteristics of adenoviruses. The significance of the adenovirus infection in this muskrat is unknown.

**Key words:** Adenovirus, electron microscopy, muskrat, *Ondatra zibethicus*, viral inclusion bodies.

In October, 1999, a muskrat (*Ondatra zibethicus*) was found alive, but obviously ill, by a trapper in the Johnson-Sauk Trail State Park (41°19'N, 89°53'W) of the Alba township (Henry County, Illinois, USA). The animal subsequently died, was frozen, submitted to the Illinois Department of Natural Resources (Springfield, Illinois, USA) and, in turn, submitted to the Animal Disease Laboratory (Galesburg, Illinois, USA) for necropsy. No other animals were found dead or ill near the area, nor was there evidence of associated environmental problems (water pollution, fish kills, etc.).

The animal was allowed to thaw and was then necropsied. It was thin. The lungs and heart were dark red. Fine strands of fibrin were evident on the capsular surface of the liver.

Bacteria (*Staphylococcus* sp.) were isolated from the lung and pooled liver, kidney, and spleen. Special bacteriologic procedures for *Listeria monocytogenes* (Sneath, 1986) and *Francisella tularensis* (Murray, 1995) failed to demonstrate those organisms. Cysts of *Giardia* sp. were demonstrated in intestinal contents by immunofluorescence (Merifluor Cryptosporidium/Giardia, Meridian Diagnostics, Inc., Cincinnati, Ohio, USA).

Brain, heart, lung, liver, kidney, small intestine, trachea, esophagus, thyroid gland, and skeletal muscle were fixed in 10% neutral-buffered formalin and processed and sectioned routinely (Carson, 1997) for histology. Microscopically, freezing artifacts were mild to moderate. The brain had minimal to mild scattered infiltrates of predominately mononuclear inflammatory cells in the meninges and as perivascular cuffs in the superficial neuropil. Lungs had fibrin with stringy basophilic material on the pleura with mild accompanying subpleural infiltrates of lymphocytes, histiocytes and a few neutrophils.

In small intestine, scattered enterocytes contained large, homogeneous basophilic intranuclear inclusion bodies (Fig. 1). In affected nuclei, chromatin was displaced to the periphery of the nucleus and replaced by smudged, basophilic material. There was little indication of necrosis or inflammation in the intestine, although autolysis hampered interpretation.

Portions of formalin-fixed small intestine were placed in modified Karnovsky's solution (Norwell et al., 1972) and then transferred to 1% osmium tetroxide in 0.1 M sodium cacodylate. The tissues were then embedded in 50:50 Spurr's/epon resin (Ted Pella, Redding, California, USA). Thin sections were cut, stained with toluidine blue O stain (Fisher Scientific Company, Fair Lawn, New Jersey) and examined microscopically for the presence of inclusion bodies. Suitable blocks were sectioned at 70–90 nm, mounted on copper grids, stained with uranyl acetate and lead citrate, and examined using a Zeiss 10C electron microscope (Carl Zeiss, Oberkochen, Germany). Ultrastructurally, the intranuclear inclusions were composed of paracrystalline arrays of non-enveloped,

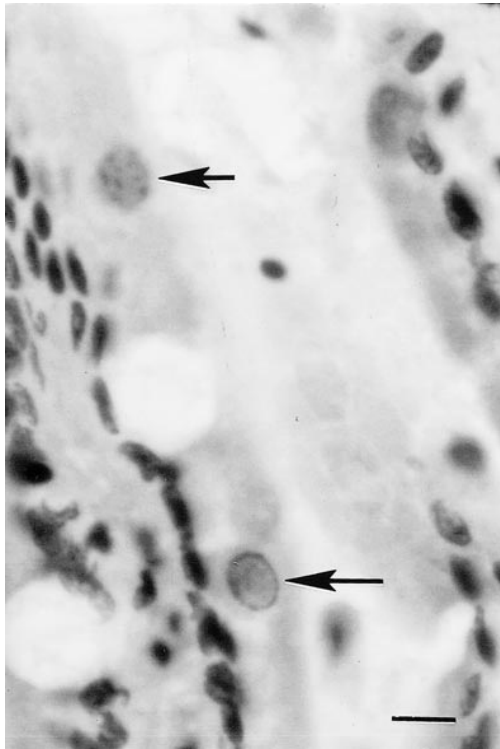


FIGURE 1. Photomicrograph of small intestine of muskrat. Adenovirus inclusion bodies (arrows) are present in the nuclei of enterocytes. H&E stain. Bar = 10  $\mu\text{m}$ .

icosahedral virus particles, 60–80 nm in diameter (Fig. 2) consistent with the morphology of adenoviruses (Fenner et al., 1993).

Immunohistochemistry was performed to determine if the muskrat adenovirus was antigenically related to the deer adenovirus, which has been demonstrated to be antigenically related to, but distinct from, bovine adenovirus types 5 and 7. Immunohistochemistry using polyclonal antiserum to bovine adenovirus type 5 (American BioResearch, Seymour, Tennessee, USA), performed as previously described (Woods et al., 1999), did not stain the intranuclear inclusions in the enterocytes.

Adenoviruses cause disease in a wide range of animal species. Some are capable of causing epidemics of high mortality. More commonly, adenoviruses cause spo-

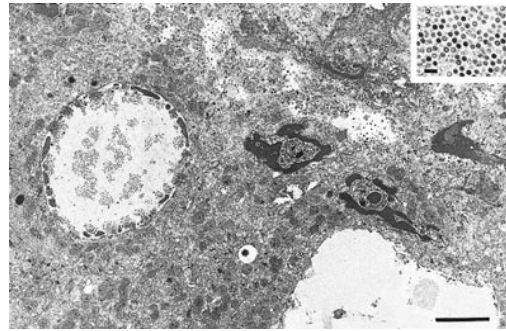


FIGURE 2. Electron micrograph of jejunal epithelial cell of muskrat. Chromatin is clumped at the margin of the nucleus. Several irregular paracrystalline arrays of virus particles are evident. Bar = 2  $\mu\text{m}$ . Inset is a high magnification of virus particles. Bar = 300  $\mu\text{m}$ .

radic diseases limited to neonates or immunologically compromised individuals. There are few reports of adenovirus infections in small mammals. An adenovirus was recovered from the blood of a white-footed deer mouse (*Peromyscus maniculatus*) in California (Reeves et al., 1967). Adenoviral inclusions were seen in kidneys of seven of 13 Franklin's ground squirrels (*Spermophilus franklini*) during routine pathologic studies associated with a predator control program in Canada (Durham et al., 1988). The adenovirus was identified by transmission electron microscopy and then isolated from the kidney. No gross or microscopic pathologic changes were evident in the affected animals (Durham et al., 1988). An adenovirus was the apparent cause of an epizootic in which 12 of 15 captive infant tree shrews (*Tupaia glis*) died. In this case, necrosis of the alimentary tract, liver, and nasal cavity were associated with the presence of inclusion bodies (Schoeb and DaRif, 1984). Adenovirus antibodies have been detected in the sera of brush-tailed possums (*Trichosurus vulpecula*) in New Zealand (Rice et al., 1991). A raccoon (*Procyon lotor*) from Oregon with adenovirus infection accompanied by fungal (*Candida* sp.) and bacterial (*Listeria monocytogenes*) infections has been reported recently (Hamir et al., 2000).

No references of adenovirus infection in muskrats were found. There was no evidence of inflammation or necrosis associated with the presence of the viral inclusions in this muskrat, suggesting this adenovirus may be a non- or minimally pathogenic infection in that species. Pathologic and laboratory findings indicated the likelihood of a bacterial cause for the illness and death of the muskrat. It is possible that the bacterial infection was debilitating and resulted in increased susceptibility to adenoviral infection.

The authors thank R. W. Nordhausen for his assistance in preparing specimens for electron microscopy.

#### LITERATURE CITED

- CARSON, F. L. 1997. Histotechnology, a self-instructional text. ASCP Press, Chicago, Illinois, 304 pp.
- DURHAM, P. J. K., F. A. LEIGHTON, AND G. A. WOBESER. 1988. An adenovirus infection of the kidney of Franklin's ground squirrels (*Spermophilus franklini*) in Saskatchewan, Canada. *Journal of Wildlife Diseases* 24: 636–641.
- FENNER, F. J., E. P. J. GIBBS, F. A. MURPHY, R. ROTT, M. J. STUDDERT, AND D. O. WHITE. 1993. *Veterinary virology*, 2nd edition. Academic Press, Inc., San Diego, California, 666 pp.
- HAMIR, A. N., D. E. MATTSON, R. J. SONN, J. STASKO, AND P. L. HABECKER. 2000. Concurrent candidiasis, listeriosis, and adenovirus infections in a raccoon (*Procyon lotor*). *Veterinary Record* 146: 320–322.
- MURRAY, P. (Editor). 1995. *Manual of clinical microbiology*, 6th Edition. ASM Press, Washington, D.C., 1149 pp.
- NORWELL, J. A., J. PANGBORN, AND W. S. TYLER. 1972. Stabilization and replication of soft tubular and alveolar systems. A scanning electron microscope study of the lungs. *In Scanning electron microscopy*, O. Johari and I. Cowin (eds.). Research Institute, Chicago, Illinois, pp. 305–313.
- REEVES, W. C., R. P. SCRIVANI, W. E. PUGH, AND W. P. ROWE. 1967. Recovery of an adenovirus from a feral rodent *Peromyscus maniculatus*. *Proceedings of the Society of Experimental Biology and Medicine* 124: 1173–1175.
- RICE, M., C. R. WILKS, D. PFEIFFER, AND R. JACKSON. 1991. Adenovirus precipitating antibodies in the sera of brush-tailed possums in New Zealand. *New Zealand Wildlife Journal* 39: 58–60.
- SCHOEB, T. R., AND C. A. DARIF. 1984. Adenoviral infection in infant tree shrews. *Journal of the American Veterinary Medical Association* 185: 1363–1366.
- SNEATH, P. H. A. (Editor). 1986. *Bergey's manual of systematic bacteriology*, Vol. 2. Williams and Wilkins, Baltimore, Maryland, USA, 1599 pp.
- WOODS, L. W., R. S. HANLEY, P. H. CHIU, H. D. LEHMKUHL, R. W. NORDHAUSEN, M. H. STILLIAN, AND P. K. SWIFT. 1999. Lesions and transmission of experimental adenovirus hemorrhagic disease in black-tailed deer fawns. *Veterinary Pathology* 36: 100–110.

*Received for publication 15 July 2000.*