

Esophageal Diverticulum Associated with *Aerococcus viridans* Infection in a Loggerhead Sea Turtle (*Caretta caretta*)

Authors: Torrent, Ayose, Déniz, Soraya, Ruiz, Antonio, Calabuig, Pascual, Sicilia, Javier, et al.

Source: Journal of Wildlife Diseases, 38(1) : 221-223

Published By: Wildlife Disease Association

URL: <https://doi.org/10.7589/0090-3558-38.1.221>

BioOne Complete (complete.BioOne.org) is a full-text database of 200 subscribed and open-access titles in the biological, ecological, and environmental sciences published by nonprofit societies, associations, museums, institutions, and presses.

Your use of this PDF, the BioOne Complete website, and all posted and associated content indicates your acceptance of BioOne's Terms of Use, available at www.bioone.org/terms-of-use.

Usage of BioOne Complete content is strictly limited to personal, educational, and non - commercial use. Commercial inquiries or rights and permissions requests should be directed to the individual publisher as copyright holder.

BioOne sees sustainable scholarly publishing as an inherently collaborative enterprise connecting authors, nonprofit publishers, academic institutions, research libraries, and research funders in the common goal of maximizing access to critical research.

Esophageal Diverticulum Associated with *Aerococcus viridans* Infection in a Loggerhead Sea Turtle (*Caretta caretta*)

Ayose Torrent,¹ Soraya Déniz,¹ Antonio Ruiz,¹ Pascual Calabuig,² Javier Sicilia,¹ and Jorge Orós^{1,3} ¹ Veterinary Faculty, University of Las Palmas de Gran Canaria, Trasmontaña s/n, 35416 Arucas (Las Palmas), Canary Islands, Spain; ² Center of Rehabilitation of Wild Fauna, Vivero Forestal, 35017 Tafira Baja (Las Palmas), Canary Islands, Spain; ³ Corresponding author (e-mail: oros@cicei.ulpgc.es)

ABSTRACT: A juvenile loggerhead sea turtle (*Caretta caretta*) stranded in Gran Canaria, Spain was necropsied. The turtle was underweight, had sunken eyes, and small amounts of crude oil were in the oral cavity. The most significant lesion was a large esophageal diverticulum at the junction of the esophagus and stomach. The diverticulum was full of gas and green mucoid fluid and a diffuse thick yellow fibrinonecrotic membrane covered the mucosa. The lumen of the diverticulum also contained moderate numbers of cephalopods, crustaceans, and anthropogenic debris including crude oil balls, plastics, and fishing lines. Histologically there was a severe diffuse fibrinonecrotic esophagitis. *Aerococcus viridans* was isolated from the diverticulum. This is the first report of an esophageal diverticulum in a sea turtle. Although *A. viridans* is a known pathogen of lobsters and fishes, there are no reports of *A. viridans* infection in sea turtles.

Key words: *Aerococcus viridans*, *Caretta caretta*, case report, esophageal diverticulum, loggerhead sea turtle.

Digestive system diseases are important causes of sea turtle strandings around the world (Glazebrook and Campbell, 1990; Hasbún et al., 1998). Ingestion of anthropogenic debris, volvulus, and intestinal impaction are relatively common among sea turtles (George, 1997). Esophageal diverticula are uncommon in domestic animals and may be either congenital or acquired in origin (Twedt, 1995).

Aerococcus viridans is a pathogen of crustaceans, causing gaffkaemia in marine lobsters (*Homarus americanus*) (Alderman, 1996), and has been isolated from rainbow wrasse (*Coris julis*) (Menezes, 1992). Since 1994, the Veterinary Faculty at the University of Las Palmas de Gran Canaria (ULPGC) has been carrying out a survey of lesions and causes of mortality among sea turtles stranded on the coasts of the Canary Islands. We report here the

post-mortem findings of a stranded juvenile loggerhead sea turtle (*Caretta caretta*) with an esophageal diverticulum associated with *A. viridans* infection.

An 11 kg juvenile female loggerhead sea turtle was found in December 1998 floating off the coast of Gran Canaria, Canary Islands (27°40'N, 15°20'W). The turtle had a curved carapace length and width of 50 cm and 45 cm, respectively, and a straight carapace length of 46 cm and width of 41 cm. The turtle was very weak, lethargic, and nonresponsive to external stimuli. It had sunken eyes, small amounts of crude oil in the oral cavity, and a sunken plastron. The animal died in transport to the Center of Rehabilitation of Wild Fauna, Tafira. It was submitted to the Veterinary Faculty, ULPGC, for necropsy.

The turtle was cachectic and the carapace was covered by numerous algae and barnacles. Grossly, a large (24 cm × 30 cm × 20 cm) esophageal diverticulum at the junction of esophagus and stomach (Fig. 1) displaced the liver and intestines caudally. The diverticulum was adherent to the lung, thoracic wall, and duodenum and was full of gas and green mucoid fluid. A diffuse thick yellow fibrinonecrotic membrane covered the mucosa. The lumen of the diverticulum contained moderate numbers of cephalopods, crustaceans, and anthropogenic debris including crude oil balls, plastics, and fishing lines. The wall of the diverticulum was thick and the serosa was partially covered by yellow fibrinonecrotic material. There was severe edema in the serosa of the junction of esophagus and stomach. The stomach was firm with mild thickening of the gastric mucosa. No foreign bodies or ingesta were

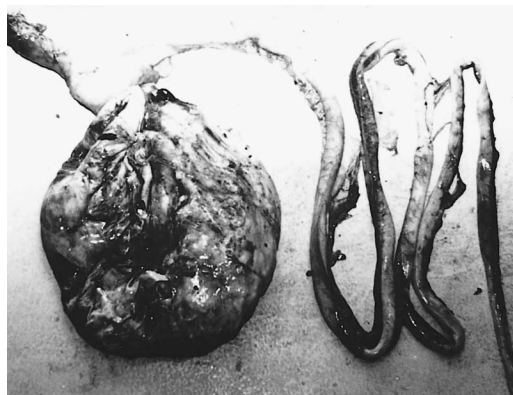


FIGURE 1. Esophageal diverticulum in a loggerhead sea turtle.

in the gastric lumen. A 1 cm nematode was on the mucosa in the pyloric region. The rest of the digestive system appeared normal and empty, with the exception of some sections posterior to the duodenum which were distended and full of gas. No macroscopic parasites were observed. The liver was friable and moderately atrophied. The spleen appeared enlarged and friable and the kidneys were enlarged and pale. A moderate amount of yellow fluid was present in the coelomic cavity. No gross lesions were visible in other major organs.

Samples of all major organs were fixed in 10% neutral buffered formalin, routinely processed, embedded in paraffin, sectioned at 4 μm , and stained with hematoxylin and eosin. Selected samples from the esophageal diverticulum were also stained with Gram's and periodic acid-Schiff (PAS) stains. Tissue samples from the esophageal diverticulum were cultured in duplicate on MacConkey agar, blood agar, Columbia agar, and Sabouraud agar. Plates were incubated for 24–48 hr at 20 C and 24 C under aerobic and anaerobic conditions.

A severe diffuse fibrinonecrotic esophagitis with infiltration of the lamina propria by lymphocytes, heterophils, and macrophages was present in the esophageal diverticulum (Fig. 2). Numerous Gram positive bacteria were associated with this lesion. Bacteria were seen intracytoplasmically

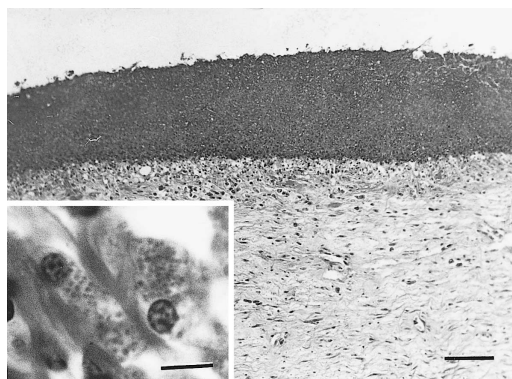


FIGURE 2. Ulceration and fibrinonecrotic esophagitis in the diverticulum. HE. Bar = 200 μm . Inset showing bacteria within the cytoplasm of two macrophages in the lamina propria. HE. Bar = 9 μm .

within macrophages in the lamina propria (Fig. 2, Inset). The PAS stain did not reveal any fungi. All layers of the esophageal wall were identified in the diverticulum. The serosa of the diverticulum showed severe multifocal granulomatous serositis with multinucleated giant cells. The lamina propria and submucosa of the stomach were moderately edematous without inflammation. Moderate number of mononuclear inflammatory cells surrounded some portal areas of the liver. Mild chronic interstitial nephritis occurred in both kidneys. Moderate hyperplasia of Peyer's patches was observed. No significant microscopic lesions were detected in other major organs.

Gram-positive, nonmotile, microaerophilic bacteria were isolated and characterized as *Aerococcus viridans* by biochemical tests (API 20 STAPH, BioMérieux, France), including catalase (-), nitrate reduction (-), acetyl methyl carbinol (-), ammonia (-), and greening reaction on blood agar (+) tests. No other microorganism was isolated.

This is the first report of an esophageal diverticulum in a sea turtle. Whereas congenital esophageal diverticula in domestic animals are attributed to abnormalities in embryologic development, acquired diverticula are described as either pulsion or traction forms. The origin of this divertic-

ulum is unknown, but the identification of all layers of the esophageal wall in the diverticulum suggests it may have been a development anomaly. Pulsion diverticula are the most common and result from increased intraluminal pressure or from herniation of mucosa through a disruption in the muscular layer of the esophageal wall. Because of their proposed traumatic origin, they do not contain layers of the muscle wall. In dogs, these diverticula usually arise secondary to an esophageal foreign body and occur in the distal esophagus (Twedt, 1995). Traction diverticula are far less common and occur secondary to periesophageal inflammation in which all layers of the esophageal wall are pulled away from the lumen to form an evagination in the esophageal wall. Traction diverticula generally form in the cranial or midesophagus (Twedt, 1995).

The large size of this diverticulum and associated compression atrophy of the liver indicate a chronic process. The progressive accumulation of foreign bodies and ingesta into the diverticulum could have contributed to its large size. Partial blockage of the gastrointestinal tract by foreign material in the diverticulum was responsible for poor body condition and buoyancy problems. Foreign bodies in the digestive tract can harm the health of sea turtles both directly and indirectly. Plastics and other materials may block the digestive tract, or cause local necrosis and ulceration (George, 1997). Indirectly, ingested waste material may harm turtles by interfering with lipid metabolism (Schulman and Lutz, 1995), increasing intestinal transit time, or contributing to the accumulation of gas and uncontrollable floating (George, 1997).

To our knowledge, there are no reports of *A. viridans* infection in sea turtles. This microorganism is a pathogen of marine lobsters (Menard and Myrand, 1987; Marks et al., 1992; Alderman, 1996) and it has been also isolated from fishes in the Atlantic Ocean (Menezes, 1992). In this turtle *A. viridans* may have entered by in-

gestion, proliferated in the diverticulum, and caused fibrinonecrotic inflammation.

The survey of the lesions and causes of mortality among sea turtles stranded in the Canary Islands was supported by the project I+D REN2000-1753. We are grateful to members of Viceconsejería de Medio Ambiente, Cabildo Insular de Gran Canaria for providing us the turtles.

LITERATURE CITED

- ALDERMAN, D. J. 1996. Geographical spread of bacterial and fungal diseases of crustaceans. *Revue Scientifique et Technique* 15: 603-632.
- GEORGE, R. H. 1997. Health problems and diseases of sea turtles. In *The biology of sea turtles*, P. L. Lutz and J. A. Musick (eds.). CRC Press, Inc., Boca Raton, Florida, pp. 363-385.
- GLAZEBROOK, J. S., AND R. S. F. CAMPBELL. 1990. A survey of the diseases of marine turtles in Northern Australia. II. Oceanarium-reared and wild turtles. *Diseases of Aquatic Organisms* 9: 97-104.
- HASBÚN, C. R., A. J. LAWRENCE, J. H. SAMOUR, AND S. AL-GHAIS. 1998. Duodenal volvulus in free-living green turtles from coastal United Arab Emirates. *Journal of Wildlife Diseases* 34: 797-800.
- MARKS, L. J., J. E. STEWART, AND T. HASTEIN. 1992. Evaluation of an indirect fluorescent antibody technique for detection of *Aerococcus viridans* (var.) *homari*, pathogen of homarid lobsters. *Diseases of Aquatic Organisms* 13: 133-138.
- MENARD, J., AND B. MYRAND. 1987. Incidence of *Aerococcus viridans* var. *homari* in the natural stock of lobsters (*Homarus americanus*) in Magdalen Islands (Quebec) following and outbreak of gaffkaemia in farmed lobsters. *Canadian Journal of Fisheries and Aquatic Sciences* 44: 368-372.
- MENEZES, J. 1992. Hazards from pathogens carried by wild fish particularly wrasse used as lice cleaners. *Bulletin of the European Association of Fish Pathologists* 12: 194-195.
- SCHULMAN, A. A., AND P. L. LUTZ. 1995. The effect of plastic ingestion on lipid metabolism in the green sea turtle (*Chelonia mydas*). In *Proceedings 12th Annual workshop on sea turtle conservation and biology*, J. I. Richardson and T. H. Richardson (compilers), National Marine Fisheries Service, Technical Memorandum. NOAA-TM-NMFS-SEFSC-361, Miami, Florida, pp. 122.
- TWEDT, D. C. 1995. Diseases of the esophagus. In *Textbook of veterinary internal medicine*, Vol. 2, S. J. Ettinger and E. C. Feldman (eds.). W. B. Saunders Company, Philadelphia, Pennsylvania, pp. 1124-1142.

Received for publication 10 October 2000.