



Epididymal Cysts in European Bison

Authors: Matuszewska, Magdalena, and Sysa, Paweł S.

Source: Journal of Wildlife Diseases, 38(3) : 637-640

Published By: Wildlife Disease Association

URL: <https://doi.org/10.7589/0090-3558-38.3.637>

BioOne Complete (complete.BioOne.org) is a full-text database of 200 subscribed and open-access titles in the biological, ecological, and environmental sciences published by nonprofit societies, associations, museums, institutions, and presses.

Your use of this PDF, the BioOne Complete website, and all posted and associated content indicates your acceptance of BioOne's Terms of Use, available at www.bioone.org/terms-of-use.

Usage of BioOne Complete content is strictly limited to personal, educational, and non - commercial use. Commercial inquiries or rights and permissions requests should be directed to the individual publisher as copyright holder.

BioOne sees sustainable scholarly publishing as an inherently collaborative enterprise connecting authors, nonprofit publishers, academic institutions, research libraries, and research funders in the common goal of maximizing access to critical research.

Epididymal Cysts in European Bison

Magdalena Matuszewska,^{1,2} and Paweł S. Sysa¹ ¹ Department of Morphological Sciences, Faculty of Veterinary Medicine, Warsaw Agricultural University, 159, Nowoursynowska str., 02 776 Warsaw, Poland; ² Corresponding (email: magdamatusz@hotmail.com)

ABSTRACT: We describe gross and histopathology of cysts found in the epididymis of the European bison (*Bison bonasus*). The material was collected from 107, 3 mo to 20 yr old, free-ranging, culled males from the Białowieża Primeval Forest (Poland). Epididymal cysts were observed in 65 (61%) of bison of varying ages. They were primarily in the head of epididymis and less often in the corpus or tail. The cysts contained opalescent fluid devoid of spermatozoa. They were lined by epithelium resembling that of efferent ducts and appeared to be congenital abnormalities.

Key words: *Bison bonasus*, congenital abnormality, cysts, epididymis, European bison.

Although many aspects of male genital pathology have been described, these reports focus on the testis and abnormalities of spermatogenesis. Routine pathologic examination of the epididymis is often neglected.

Testicular sperm lack ability to move and fertilize an ovum; they acquire these properties during the passage through the epididymis. The normal path of sperm following their release from the testis includes the ductuli efferentes, the caput epididymidis, the corpus epididymidis, and finally the cauda epididymidis where they are stored until ejaculated. Sperm passage through the entire epididymal environment is essential for sperm maturation.

Various anomalies of the epididymis have been reported including segmental aplasia of the mesonephric duct in which there was partial or complete absence of the epididymis, the presence of blind efferent ductules, and epididymal cysts (Blom and Christensen, 1958; Ladds et al., 1973; Humphrey and Ladds, 1975; Hemeida et al., 1978; Goyal, 1983; Ladds et al., 1990). Gross and microscopic lesions of the epididymis have been reported in bulls, male goats, rams, stallions, boars, and dogs. However the pathology of the

epididymis of male European bison is poorly documented (Czykier et al., 1999).

The European bison (*Bison bonasus*) which used to inhabit vast areas in Europe, gradually disappeared until it only remained in Poland. No free-ranging bison survived World War I, however, a few animals survived in zoological gardens. In 1929 three bison were purchased from a zoo in Sweden and introduced into the Białowieża Primeval Forest (Poland). Successful captive breeding allowed bison to be released into the forest as a free-living herd (Krysiak, 1967; Krasiński, 1994; Gill, 1999; Krasiński et al., 1999). The bison are carefully monitored and some are culled annually. This culling provided the opportunity to assess occurrence of reproductive problems and infectious diseases (Kita and Anusz, 1991; Bomba, 1995; Czykier et al., 1999; Jakob et al., 2000). This study focused on gross changes and histopathology of epididymal cysts found in the European bison.

We collected samples from culled male bison from the Polish side of the Białowieża Forest (52°45'N, 23°50'E) in the winters of 1995–2000. Bison were culled because of poor condition, trauma of various types, parasitic diseases, and balanoposthitis; weak calves especially those born after October also were culled. Samples from the testes and epididymides were taken from 107 bison (3 mo–20 yr of age), fixed in Bouin's fluid and/or formalin and embedded in paraffin. Four–five μ m thick intermittent serial sections were collected. These sections were stained with hematoxylin and eosin and examined with a light microscope. Periodic acid Schiff (PAS) reaction and van Gieson stains also were used (Culling et al., 1985).

Epididymal cysts were observed in 65 of

TABLE 1. Age of European bison and location of epididymal cysts.

Location of epididymal cysts	Calves (3 mo–1 yr) <i>n</i> = 17	Juveniles (1–3 yr) <i>n</i> = 20	Adult (3–20 yr) <i>n</i> = 28
Head of epididymis	59%	50%	54%
Corpus of epididymis	12%	5%	14%
Head and corpus of epididymis	24%	40%	21%
Tail of epididymis	6%	5%	4%
Head, corpus, and tail of epididymis	Not observed	Not observed	7%

107 bison. Cysts were present in calves (3 mo–1 yr of age), juveniles (1–3 yr of age), and adults (>3–20 yr of age); frequency of cysts increased with age. Cysts were present in 45% (17 of 38) calves, 69% (20 of 29) juveniles, and 70% (28 of 40) adults. Cysts were unilateral in 35 (54%) animals and bilateral in 30 (46%) of males. The cysts were most common in the head, fewer in the corpus, and were sporadic in the tail of epididymis (Table 1). The cysts in head of the epididymis were rounded and primarily in the anterior region or in the passage between the head and the corpus. In the corpus or tail of the epididymis the cysts usually were pedunculated. The size of cysts varied from 4–20 mm in diameter, but there was no correlation between size and age. The cysts formed an integral part of epididymis, were well delimited, and usually were covered by the capsule. Through the capsule a clear aqueous fluid was discernible.



FIGURE 1. Pseudostratified cuboidal epithelium lining the epididymal cyst of a 2.5 yr old bull. The cyst is lined by two kinds of cuboidal epithelial cells: ciliated (\downarrow) and nonciliated with acidophilic droplets seen on the surface (\blacktriangledown). HE. Bar=10 μ m.

The cavity of the cysts was lined with pseudostratified epithelium with a cuboidal to low columnar cells with round or slightly oval nucleus and often with many long cilia at the luminal surface. Nonciliated epithelial cells also were observed (Figs. 1, 2). Distinct acidophilic droplets were often seen on the surface of the epithelium. The epithelium rested on a well defined, homogenous, PAS positive basal membrane. There were no signs of inflammation in the tissue surrounding cysts. Smooth muscle was surrounded by collagen fibers forming a thick connective tissue capsule. The microscopic features of the cysts in young bison were similar to those observed in older animals. Cysts contained a small amount of homogenous, acidophilic fluid that was devoid of spermatozoa, with the exception of one 10 yr old bull where sperm were found within the cyst. Spermatozoa were observed in epididymal ducts of males over 3 yr of age (Fig. 3).

We found high prevalence of cysts in




FIGURE 2. Pseudostratified columnar epithelium of the epididymal cyst from a 2 yr old bull. HE. Bar=10 μ m.

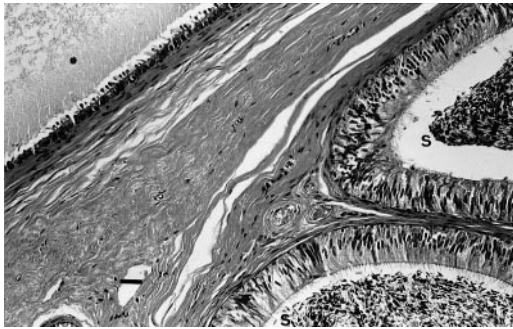


FIGURE 3. Spermatozoa in the lumen of an epididymal duct (S) but not in the cyst (*) in a 7 yr old bull. HE. Bar=20 μ m.

the epididymis of European bison males. In comparison with measurements of segments of the epididymis in cattle (Goyal, 1985), the epididymis of European bison has a wide head and thickened tail (Świeżyński, 1968). Epididymal cysts were found in bison of different ages with highest prevalence in adult males; however in cattle they were more common in newborn calves (Humphrey and Ladds, 1975). Slightly more bison has unilateral than bilateral epididymal cysts. Similarly, more Merino rams were observed with unilateral than bilateral retention cysts of the epididymis (Watt, 1971).

The microscopic features of the epididymal cysts in European bison were similar to those observed in bulls, rams, and goats (Watt, 1971; Goyal, 1983; Tarigan et al., 1990; Wakui et al., 1997). The origin of the epididymal cysts in European bison could not be unequivocally determined. Most researchers distinguish between congenital and acquired cysts in the genitals. The causes of acquired cysts may be trauma or inflammation. No post-traumatic changes were observed in the region of scrotum and testes of the European bison examined nor were signs of inflammation observed. Our gross and histologic findings suggest they were probably congenital abnormalities.

Congenital cysts are derived from closed ducts originating from the rete testis or the epididymal duct (Blom and Christensen,

1958). Epididymal cysts may arise from paradidymis internus or aberrant tubules (Ladds et al., 1973). Some authors suggest congenital epididymal cysts are derived from remnants of mesonephric tubules (Watt, 1971; Humphrey and Ladds, 1975; Wakui et al., 1997). The cysts found in the epididymis of European bison were similar to those described by Watt (1971) in Merino rams and Wakui et al. (1997) in the Shetland sheepdogs.

The epididymal cysts found in the European bison are most likely isolated remnants or vestiges of mesonephric tubules and may have originated as ectopic mesonephric epithelium during embryologic development. European bison are highly inbred (Olech, 1989) and congenital abnormalities may appear more often than in other ruminants. The presence of cysts in the epididymis could affect reproduction, however, data are not available to evaluate breeding success in free-ranging herds of bison.

The authors thank Z. Pucek for comments and discussion. Special thanks to Z. Krasieński for documentation on culled animals and the technical staff of the Mammal Research Institute in Białowieża for their assistance in collecting the material. The authors also acknowledge D. Łakus and E. Henczke for their technical assistance in the laboratory.

LITERATURE CITED

- BLOM, E., AND N. O. CHRISTENSEN. 1958. Cysts and cyst-like formations (inter alia spermiostasis) in the genitals of the bull. Royal Veterinary and Agricultural College, Copenhagen, Denmark, Yearbook 1958: 101–133.
- BOMBA, G. 1995. Pathomorphologic investigations of the testis of the European bison and domestic cattle hybrids. Ph.D. Thesis, University of Agriculture and Technology, Olsztyn, 90 pp. [In Polish.]
- CULLING, C. F. A., R. T. ALLISON, AND W. T. BARR. 1985. Cellular pathology technique, 4th Edition. Butterworths, London, pp. 168, 220.
- CZYKIER, E., B. SAWICKI, AND M. KRASIŃSKA. 1999. Postnatal development of the European bison spermatogenesis. *Acta Theriologica* 44: 77–90.
- GILL, J. 1999. Physiology of bison. SEVERUS Publisher, Warsaw, Poland, pp. 24–62. [In Polish.]

- GOYAL, H. O. 1983. Appendix epididymidis and aberrant ductules of the bull: Light-microscopic and ultrastructural study. *Acta Anatomica* 117: 321–330.
- . 1985. Morphology of the bovine epididymis. *American Journal of Anatomy* 172: 155–172.
- HEMEIDA, N. A., W. O. SACK, AND K. MCENTEE. 1978. Ductuli efferentes in the epididymis of boar, goat, ram, bull and stallion. *American Journal of Veterinary Research* 39: 1892–1900.
- HUMPHREY, J. D., AND P. W. LADDS. 1975. Pathology of the bovine testis and epididymis. *Veterinary Bulletin* 45: 787–797.
- JAKOB, W., H-D. SCHRÖDER, M. RUDOLPH, Z. A. KRASIŃSKI, M. KRASIŃSKA, O. WOLF, A. LANGE, J. E. COOPER, AND K. FRÖLICH. 2000. Necrobacillosis in free-living male European bison in Poland. *Journal Wildlife Diseases* 36: 248–256.
- KITA, J., AND K. ANUSZ. 1991. Serologic survey for bovine pathogens in free-ranging European bison from Poland. *Journal Wildlife Diseases* 27: 16–20.
- KRASIŃSKI, Z. 1994. Restitution of the European bison in the Białowieża reserve in the years 1929–1952. *Parki Narodowe i Rezerваты Przyrody* 13: 3–23 [in Polish with an English summary.]
- , M. KRASIŃSKA, AND A. N. BUNEVICH. 1999. Free-ranging populations of lowland European bison in the Białowieża Forest. *Parki Narodowe i Rezerваты Przyrody* 18: 23–75.
- KRYSIK, K. 1967. The history of the European bison in the Białowieża Forest and the results of its protection. *Acta Theriologica* 12: 323–331.
- LADDS, P. W., D. P. DENNETT, AND J. S. GLAZEBROOK. 1973. A survey of the genitalia of bulls in northern Australia. *Australian Veterinary Journal* 49: 335–340.
- , G. D. BRIGGS, AND R. A. FOSTER. 1990. Epididymal aplasia in two rams. *Australian Veterinary Journal* 67: 457–458.
- OLECH, W. 1989. The participation of ancestral genes in the existing population in European bison. *Acta Theriologica* 34: 397–407.
- ŚWIEŻYŃSKI, K. 1968. The male reproductive organs in the European bison. *Acta Theriologica* 13: 511–551.
- TARIGAN, S., P. W. LADDS, AND R. A. FOSTER. 1990. Genital pathology of feral male goats. *Australian Veterinary Journal* 67: 286–290.
- WAKUI, S., M. FURUSATO, K. YOKOO, AND S. USHIGOME. 1997. Testicular efferent ductule cyst of a dog. *Veterinary Pathology* 34: 230–232.
- WATT, D. A. 1971. Congenital retention cysts of the epididymis in rams. *Australian Veterinary Journal* 47: 287–288.

Received for publication 17 August 2000.