



AN OUTBREAK OF FUNGAL DERMATITIS AND STOMATITIS IN A FREE-RANGING POPULATION OF PIGMY RATTLESNAKES (SISTRURUS MILIARIUS BARBOURI) IN FLORIDA

Authors: Cheatwood, Joseph L., Jacobson, Elliott R., May, Peter G., Farrell, Terence M., Homer, Bruce L., et al.

Source: Journal of Wildlife Diseases, 39(2) : 329-337

Published By: Wildlife Disease Association

URL: <https://doi.org/10.7589/0090-3558-39.2.329>

BioOne Complete (complete.BioOne.org) is a full-text database of 200 subscribed and open-access titles in the biological, ecological, and environmental sciences published by nonprofit societies, associations, museums, institutions, and presses.

Your use of this PDF, the BioOne Complete website, and all posted and associated content indicates your acceptance of BioOne's Terms of Use, available at www.bioone.org/terms-of-use.

Usage of BioOne Complete content is strictly limited to personal, educational, and non - commercial use. Commercial inquiries or rights and permissions requests should be directed to the individual publisher as copyright holder.

BioOne sees sustainable scholarly publishing as an inherently collaborative enterprise connecting authors, nonprofit publishers, academic institutions, research libraries, and research funders in the common goal of maximizing access to critical research.

AN OUTBREAK OF FUNGAL DERMATITIS AND STOMATITIS IN A FREE-RANGING POPULATION OF PIGMY RATTLESNAKES (*SISTRURUS MILIARIUS BARBOURI*) IN FLORIDA

Joseph L. Cheatwood,^{1,4} Elliott R. Jacobson,¹ Peter G. May,² Terence M. Farrell,² Bruce L. Homer,¹ Don A. Samuelson,¹ and James W. Kimbrough³

¹ University of Florida, College of Veterinary Medicine, Gainesville, Florida 32610, USA

² Department of Biology, Stetson University, Deland, Florida 32720, USA

³ Department of Plant Pathology, University of Florida, Gainesville, Florida 32611, USA

⁴ Corresponding author (email: cheatwoo@ufl.edu)

ABSTRACT: Between September 1997 and March 1998, a severe skin, eye, and mouth disease was observed in a population of dusky pigmy rattlesnakes (*Sistrurus miliarius barbouri*), at the Lake Woodruff National Wildlife Refuge in Volusia County, Florida (USA). Three affected pigmy rattlesnakes were submitted for necropsy. All snakes had severe necrotizing and predominantly granulomatous dermatitis, stomatitis, and ophthalmitis, with involvement of the subadjacent musculature and other soft tissues. Numerous fungal hyphae were seen throughout tissue sections stained with periodic acid Schiff and Gomori's methenamine silver. Samples of lesions were cultured for bacteria and fungi. Based on hyphae and spore characteristics, four species of fungi were identified from culture: *Sporothrix schenckii*, *Pestalotia pezizoides*, *Geotrichum candidum* (*Galactomyces geotrichum*), and *Paecilomyces* sp. While no additional severely affected pigmy rattlesnakes were seen at the study site, a garter snake (*Thamnophis sirtalis*) and a ribbon snake (*Thamnophis sauritis*) with similar lesions were found. In 1998 and 1999, 42 pigmy rattlesnakes with multifocal minimal to moderate subcutaneous masses were seen at the study site. Masses from six of these snakes were biopsied in the field. Hyphae morphologically similar to those seen in the severe cases were observed with fungal stains. Analysis of a database representing 10,727 captures in previous years was performed after the 1998 outbreak was recognized. From this analysis we determined that 59 snakes with clinical signs similar to those seen during the 1998 outbreak were documented between 1992 and 1997. This study represents the first documented report of a mycotic disease of free-ranging snakes.

Key words: Florida, fungus, mycotic dermatitis, mycotic stomatitis, pigmy rattlesnake, *Sistrurus miliarius*, *Sporothrix schenckii*.

INTRODUCTION

In the winter of 1997 and spring of 1998, nine dusky pigmy rattlesnakes (*Sistrurus miliarius barbouri*) with severe skin, eye, and mouth lesions were found at Lake Woodruff National Wildlife Refuge, Volusia County, Florida (USA) during surveys of a study site to collect demographic and ecologic data. Subsequently, two ribbon snakes (*Thamnophis sauritis sauritis*) and a garter snake (*Thamnophis sirtalis sirtalis*) with similar lesions were also seen at the site during routine surveys. Snakes with severe lesions were either found dead in the field or were moribund. In addition, other pigmy rattlesnakes were seen with less severe multifocal subcutaneous masses or crusted scutes during the same period. After discovery of the initial cases, we collected tissue samples from af-

ected snakes in an effort to determine the etiology of the lesions.

Skin lesions in snakes can be caused by a variety of pathogens including bacteria, fungi, and parasites. Although there is a paucity of information on free-ranging reptiles, there have been a number of reports of fungal infections in captive reptiles. In snakes, the integumentary system is affected commonly. The following fungi have been isolated from skin lesions of snakes: *Geotrichum* spp. (Karstad, 1961), *Candida albicans* (Zwart, 1968), *Penicillium* spp. (Jacobson, 1980), and an unidentified phycomycete (Werner et al., 1978). Fungal skin and granulomatous disease have been seen in a variety of species of captive snakes including an anaconda (*Eunectes murinus*; Marcus, 1971), reticulated pythons (*Python reticulatus*; Frank, 1970),

a boa constrictor (*Constrictor constrictor*; Frank, 1976), carpet pythons (*Morelia spilotes*; McKenzie and Green, 1976), and a northern water snake (*Nerodia sipedon*; Karstad, 1961). Herein we report the presence of fungi in granulomatous skin lesions of free-ranging pigmy rattlesnakes and the results of attempts to isolate fungi from these lesions.

MATERIALS AND METHODS

In 1992, a study site was established at Lake Woodruff National Wildlife Refuge (DeLeon Springs, Florida; 29°07'N, 81°22'30"W) in order to understand demographic and ecologic aspects of dusky pigmy rattlesnakes. This research has provided new information on the life history of this snake (Bishop et al., 1996; Rabatsky and Farrell, 1996; Roth et al., 1999). The refuge contains a large range of habitat types including sandy uplands, seasonally damp oak hammocks, pine flatlands, and areas of tall marsh grass. A diverse reptile population is present in the refuge. During this study, we observed seven species of turtles, one species of crocodilian, five species of lizards, and 17 species of snakes. Of these, pigmy rattlesnakes were the most plentiful species. May et al. (1996) reported the size and density of the population to be approximately 600 rattlesnakes in the research site, providing a density of >50 pigmy rattlesnakes per hectare. Density and population size fluctuate yearly, partially because the number of juveniles born each year varies (Farrell et al., 1995).

Between September 1997 and March 1998, nine pigmy rattlesnakes with severe eye, head, mouth, and multifocal skin lesions were found during regular surveys of the study site. Three of these snakes were transported to the University of Florida (Gainesville, Florida) where they were euthanatized with pentobarbital (100 mg/kg, intracoelomic) and examined at necropsy. Heads were removed and decalcified using formic acid sodium citrate decalcification solution (Luna, 1968). Samples of all major organ systems were collected and placed in neutral buffered 10% formalin (NBF). For microbial isolation attempts, samples of lesions were homogenized and streaked onto blood agar for bacterial isolation and incubated at 36 C. Samples were pressed into Sabouraud dextrose agar (SAB) and mycobiologic agar for fungal isolation and incubated at 23 C for 30 days.

During weekly surveys from January 1998 through November 1999, biopsies were obtained in the field from six pigmy rattlesnakes with multifocal minimal to moderate necrotiz-

ing skin lesions overlying subcutaneous masses. For biopsy, the snakes were captured and restrained manually using heavy leather welding gloves and a ring block of 2% lidocaine (Butler Company, Columbus, Ohio, USA) was used for local anesthesia. Biopsy samples were obtained aseptically by cleansing the scales with a 2% chlorhexidine solution (Nolvasan, Fort Dodge, Fort Dodge, Iowa, USA) and immediately incising the affected scales and subdermal masses with a sterile scalpel blade. The incision site was then cleansed with an organic iodine solution (Betadine, Fort Dodge) and the snakes were released. The biopsies were divided in half and placed in either NBF or sterile water. Samples placed in NBF were processed for histology. For isolation of fungi, samples in sterile water were placed on SAB agar or mycobiologic agar and incubated at 23 C.

Tissues in NBF were embedded in paraffin and sectioned at 5 µm. Sections were stained with hematoxylin and eosin (H&E), periodic acid-Schiff (PAS) stain, or Gomori's methenamine silver (GMS) stain and were evaluated by light microscopy.

Cultures for fungal isolation were observed for fungal growth over a 30-day period. Fungi forming colonies on the plates were separated into pure culture on additional SAB plates. Samples of pure fungal cultures were placed on malt extract agar to encourage the production of asexual reproductive structures. All fungi growing on plates were identified by morphologic characteristics and colony presentation using several previously published keys (Ellis, 1972, 1976; Fisher and Cook, 1998). Samples of mature cultures were placed on a slide in a drop of lactophenol cotton blue to help visualize the morphologic features of the fungi (Rippon, 1988). Measurements of fungi in tissue were made with an optical micrometer.

Samples for microbial isolation were also obtained from leather gloves used to handle the rattlesnakes. Small pieces (2–3 mm) of leather were removed from the gloves aseptically and placed on SAB as described above. Fungi from these cultures were identified as described above.

During the study, all pigmy rattlesnakes with a mass >25 g encountered in the field were restrained manually using leather welder's gloves and identified with a passive integrated transponder tag (PIT-tag; AVID Marketing Inc., Norco, California, USA) was inserted into the coelom using a modified hypodermic syringe (Jemison et al., 1995). Individual animal PIT-tagging was begun in this population in 1992, allowing for collection of life history and movement data for individual snakes, sometimes yielding dozens of captures over a period

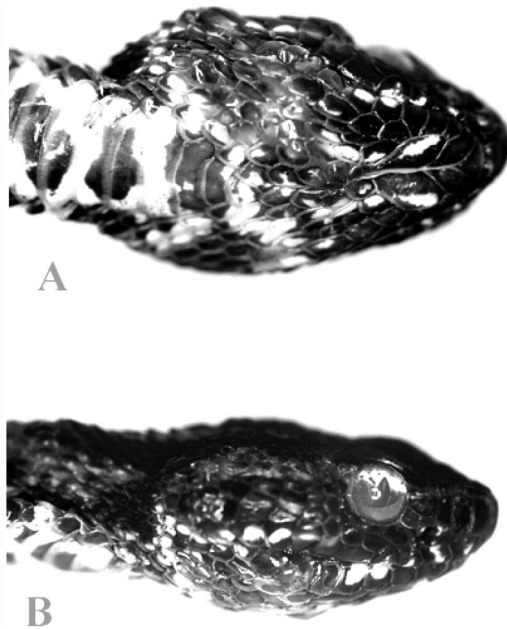


FIGURE 1. Ventrodorsal (A) and lateral (B) views of a pigmy rattlesnake with severe facial skin disease. The spectacle is cloudy and bulging beyond normal limits. There are diffuse areas of epidermal necrosis with subcutaneous swelling that distort the appearance of the head.

as long as 8 yr. A database (Microsoft Access 97 for Microsoft Windows, Redmond, Washington, USA) containing records of all captures since the beginning of the ecologic study was available and it was possible to conduct a retrospective evaluation to determine the presence of lesions in previously captured snakes. Information contained in the database included capture location, mass, length, gravidity, sex, presence or absence of prey, and any special comments necessary to describe the individual. In this database, cutaneous masses were referred to as “lumps,” “bumps,” or “tumors” and snakes with severe orofacial lesions were described as having “mouth rot.” Mild to moderate multifocal skin lesions seldom were recorded in the database. The number of snakes with each type of lesion seen during the study period was determined by querying the database for these terms.

RESULTS

Between February 1992 and November 1999, a total of 10,727 pigmy rattlesnake captures were made at the field site. This number represented multiple captures of approximately 600 individual snakes (May

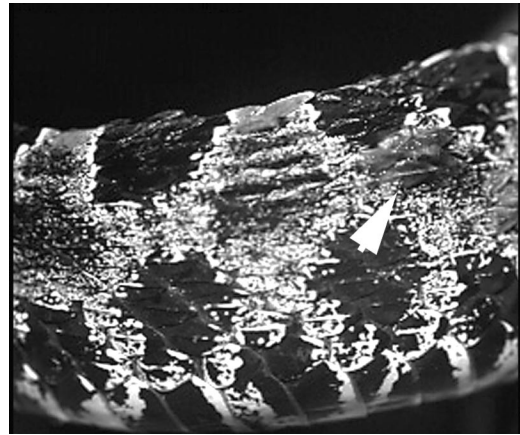


FIGURE 2. Focal epidermal necrosis and subcutaneous masses (arrow) in the skin of a pigmy rattlesnake.

et al., 1996). Between February 1992 and September 1997, 59 pigmy rattlesnakes were observed with moderate to severe lesions (Figs. 1, 2), based on mark/recapture data in the database. Lesions from these snakes were not examined.

The number and frequency of lesions was highest during the 1997–98 epizootic according to the capture database. During the 6 mo period between October 1997 and March 1998, 26 new cases of either mild to moderate granulomatous lesions, crusted scutes, or a severe necrotizing fungal infection involving the head were observed from 164 individual rattlesnakes (16.9%), but only two of these cases were examined at necropsy due to the emergent status of the epizootic. This period appeared to be the peak of the epizootic. The epizootic diminished during our study, and only 11 new individuals were seen with lesions between April 1998 and November 1999. Rattlesnakes affected during this study ranged in age from <1 yr to >6 yr. Age for many snakes was known because they were PIT-tagged during their first few months of life.

By light microscopy, the severe facial and orbital lesions seen in the pigmy rattlesnakes, garter snakes, and ribbon snakes had similar features. Affected skin, spectacles, and mucosa lining the oral cavity

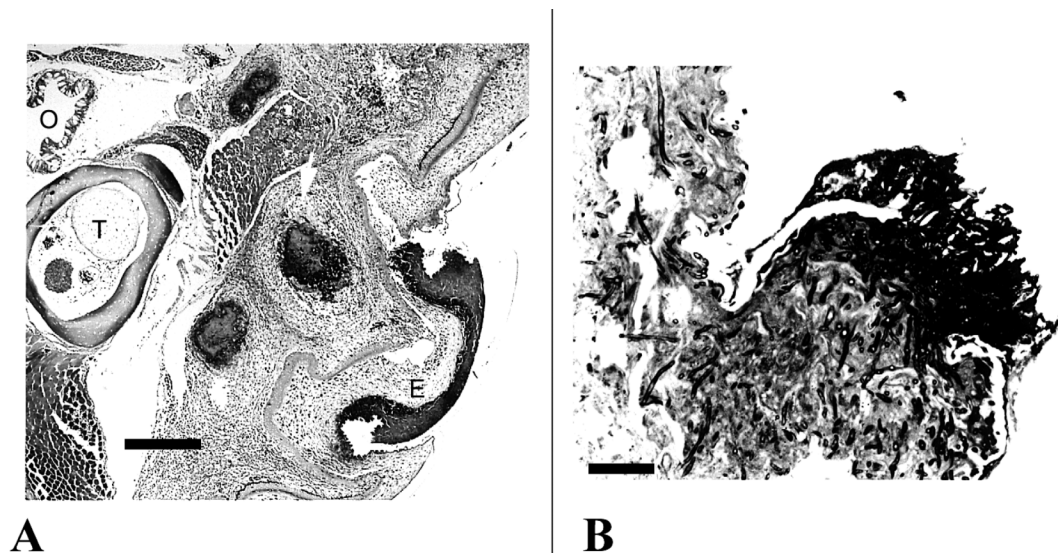


FIGURE 3. A. Photomicrograph of the head of a pigmy rattlesnake showing necrotic epidermis (E), subcutaneous granulomas, tooth (T), and oral cavity (O). H&E stain. 40 \times . Bar=2 mm. B. At a higher magnification, numerous fungal hyphae can be seen in an area of epidermal necrosis. PAS stain. 400 \times . Bar=10 μ m.

were diffusely necrotic with either diffuse infiltrates of mixed inflammatory cells including heterophils, small mononuclear leukocytes, and macrophages (i.e., immature granulomas) or more organized, mature granulomas. The mature granulomas observed in both the severe and multifocal infections were comprised of a mantle of epithelioid macrophages and multinucleated giant cells surrounding a necrotic, deeply eosinophilic center with H&E staining (Fig. 3A). Using PAS and GMS stains, branching septate hyphae were seen (Fig. 3B). Branching hyphae of several different widths (1.1–5.5 μ m) were observed in tissues, suggesting there were multiple fungal agents associated with the granulomatous response. Some hyphae in tissue branched often (every 3–6 μ m) and others had much longer intervals between branches (20–30 μ m). Fungal hyphae were seen in all granulomas, both immature and mature. Evaluation of all internal tissues did not reveal any fungal granulomas.

Biopsies of mild to moderate skin lesions positive for fungi were characterized by epidermal hyperplasia, often with ul-

ceration, subtended by an edematous dermis and subdermis. In skin samples from one affected pigmy rattlesnake, there was severe epidermitis with focal to diffuse coagulation necrosis of the epidermis and dermis. Clusters of mature granulomas with deeply eosinophilic centers were seen in the subcutis and contained fungal hyphae (Fig. 4).

The severe facial and orbital lesions distorted the appearance of affected snakes. Spectacles of severely affected snakes were edematous, white or clouded, and abnormally bulged from the margins of the orbit. The oral cavity and surrounding tissues were also edematous, thickened, and necrotic. Histologic evaluation indicated that the more severe lesions consisted of granulomatous inflammation intermixed with areas of cellulitis and necrosis. The overlying mucosa and epidermis were often necrotic.

Fungi were isolated from five samples collected from rattlesnakes with mild to moderate multifocal skin lesions. Based upon the morphology of conidia, spores, and other sexual structures, the following fungi were identified on malt extract agar

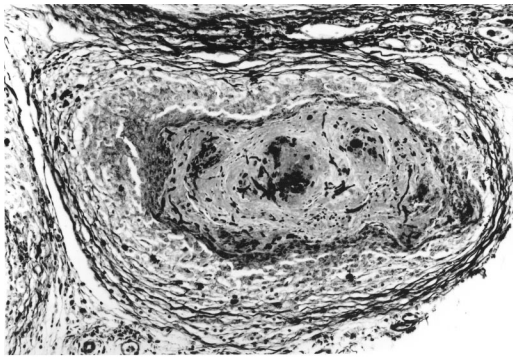


FIGURE 4. Photomicrograph of a subcutaneous granuloma in a pigmy rattlesnake with multifocal skin lesions. Fungal hyphae can be seen within the center of the granuloma. GMS stain. 400 \times . Bar=10 μ m.

plates: *Sporothrix schenckii* (two rattlesnakes), *Paecilomyces* sp. (one rattlesnake), *Pestalotia pezizoides* (one rattlesnake), and *Geotrichum candidum* (*Galactomyces geotrichum*) (one rattlesnake). The first three fungi were isolated from initial cultures from severely affected rattlesnakes. *Galactomyces geotrichum* was isolated from two cultures of biopsies of granulomatous lesions from different rattlesnakes. In addition to the fungi, the following bacteria were isolated from the initial severe orofacial lesions of two rattlesnakes: *Xanthomonas* sp., *Klebsiella-Enterobacter* sp., *Corynebacterium* sp., and *Bacillus* spp.

An unidentified actinomycete and two species of fungi, *Pestalotia pezizoides* and *Cladosporium sphaerospermum*, were isolated from samples taken from the gloves used to handle snakes.

In field studies on this population after the severe oral and integumentary lesions were recognized, snakes with focal to multifocal mild integumentary lesions were

also observed. Previous reports of similar lesions were found in a review of field records.

Calculations based on the number of new cases and the numbers of individual snakes captured per year indicate a high degree of variability in the incidence of the disease in the population (Table 1). The number of snakes captured each year varied with a maximum of 1,047 in 1994 and a minimum of 285 in 1999.

Lesions were not limited to pigmy rattlesnakes during our study. Similar severe gross lesions were observed in a ribbon snake and a garter snake at the site in the fall of 1997. There are, however, no records in the database prior to 1997 of any snakes other than pigmy rattlesnakes with lesions.

DISCUSSION

In reptiles, granulomatous inflammation can be caused by a wide variety of pathogens including bacteria, fungi, and parasites (Montali, 1988). While several bacteria were isolated from lesions in snakes in this study and were identified in tissue section using special stains, fungal hyphae were consistently seen within the centers of organized granulomas in GMS and PAS stained tissue sections, in areas of less organized granulomatous inflammation, and also within necrotic tissue on the body surface. Similar appearing integumentary lesions have been reported in captive snakes with fungal epidermitis and dermatitis (Williams et al., 1979; Jacobson, 1984). One of us (Jacobson, unpubl. data) has seen similar fungi-associated integumentary lesions in other free-ranging snakes in the southeastern United States including a corn snake (*Elaphe guttata*), water snakes

TABLE 1. Incidence of mycotic oral and skin lesions in pigmy rattlesnakes.

	Year							
	1992	1993	1994	1995	1996	1997	1998	1999
New cases/total snakes captured	6/619	6/800	10/1047	20/670	3/533	10/829	30/474	1/285
Incidence	0.66	0.75	0.96	2.99	0.56	1.21	6.32	0.35

(*Nerodia* spp.), garter snakes (*Thamnophis* spp.), and eastern indigo snakes (*Drymarchon corais*). Such lesions probably occur frequently but go unreported or unrecognized by investigators working on snakes in the field. The mild to moderate focal to multifocal integumentary lesions, often resulting in a superficial necrosis, are easily overlooked because the overlying epidermis is only slightly elevated. Because all of the lesions biopsied during our prospective study contained fungi, lesions on the snakes found in the field prior to October 1997 were probably also of fungal origin.

The fungi isolated from pigmy rattlesnakes have not been previously reported as pathogens of free-ranging snakes. *Sporothrix schenckii* is a well-known pathogen of other organisms. It has been reported to cause subcutaneous lesions in primates (Kauffman, 1999), ungulates (Irizarry-Rovira et al., 2000), felids (Davies and Troy, 1996), and armadillos (*Dasypus novemcinctus*) (Wenker et al., 1998) that are similar to those that we have observed in pigmy rattlesnakes. Previous isolation of *S. schenckii* from reptiles has been limited to a group of mariculture-reared green turtles (*Chelonia mydas*) with mixed mycotic pneumonia (Jacobson et al., 1979). *Paecilomyces* sp. was also isolated from the lungs of the same turtles. Two additional reports implicated *Paecilomyces* as a pathogenic fungus in reptiles: infections in a captive Aldabra tortoise (*Geochelone gigantea*) that died with macroscopic, firm yellow nodular lesions distributed across the oral surface, gastric mucosa, and throughout the liver (Heard et al., 1986), and a systemic infection of a captive crocodile (*Crocodylus porosus*; Maslen et al., 1988) that showed granulomatous lesions of fungal origin in the liver, left lung, and spleen. *Pestalotia pezizoides* has never been implicated as a pathogenic fungus, except in some plant species, and was probably a contaminant in the tissue. However, it is possible that the organism was acting as a facultative pathogen because of the advanced necrotic condition

of the lesions from which it was isolated. *Geotrichum candidum* (*Galactomyces geotrichum*) has been reported as a pathogen in a group of captive carpet pythons (McKenzie and Green, 1976), a northern water snake (Karstad, 1961), and an unspecified garter snake (*Thamnophis* sp.; Vissienon et al., 1999).

Based upon our findings, more than one fungus was probably involved in the lesions. Hyphae with several different morphologic characteristics were observed. Although morphologies of the fungi seen in the tissue were consistent with what would be expected if the isolated fungi were present in tissue, it is not possible to know which, if any, of the fungi cultured were actually in the tissue samples; isolation in pure culture is still the gold standard. It is often difficult to determine the identity of fungi in tissue without special techniques such as immunofluorescent antibody assays, immunohistochemistry, or molecular (i.e. polymerase chain reaction) assays (Fisher and Cook, 1998). In some cases, these can be used to identify fungi to genus and species (Makimura et al., 1994; Sandhu et al., 1995; Fisher and Cook, 1998). None of these procedures were performed in our cases. Thus, it is possible that other pathogenic or opportunistic fungi may have been present in the lesions, but not isolated in culture. Conversely, some of the fungi that were isolated could have been surface contaminants and not actually involved in the lesions. Transmission studies are needed to demonstrate a causal relationship and were beyond the scope of this report.

The pathogenesis of these lesions, both the severe orofacial lesions and mild to moderate integumentary lesions, is unclear. Penetrating wounds in the integument may have resulted in infection and granuloma formation in the dermis in those snakes with mild to moderate integumentary lesions. Though no ticks or other external parasites were observed on pigmy rattlesnakes at the time of capture, this is also a potential route of infection and

could explain the multifocal distribution of the subcutaneous granulomas. Ticks exist in the study area, but their role, if any, as a parasite of pigmy rattlesnakes is unknown. Another explanation could be the association with subcutaneous parasites. Fungal granulomas associated with subcutaneous pentastomid parasites in indigo snakes in Florida have been seen by one of us (Jacobson, unpubl. data). No pentastomes were observed in any of the rattlesnakes at necropsy, but this does not exclude the possibility that they may be in the population. Full necropsies on several snakes with severe lesions did not indicate systemic disease. While this suggests that lesions commenced locally and spread to surrounding tissues, it is still possible that the pathogen(s) spread via the circulatory system, causing granulomatous inflammation at multiple sites. In humans, spread of *S. schenckii* and other systemic fungi may occur through the circulatory system and lymphatics (Rippon, 1988).

An anthropogenic basis for the epidemic also was considered. One of the initial concerns in this study was that fungi were transferred between snakes and entered tissues due to handling and sampling techniques being used in the field. Due to their small size, all pigmy rattlesnakes were manually restrained using a pair of leather welder's gloves. The pair of gloves being used at the time of the 1997–98 outbreak had been in use for approximately 2 yr. No reports were found in the literature to indicate that either of the two fungi identified in pure culture from samples taken from the gloves, *Cladosporium sphaerospermum* and *Pestalotia pezizoides*, are primary pathogens of vertebrates. However, *C. sphaerospermum* was isolated from lesions in a lesser octopus (*Eledone cirrhosa*) and transmission studies were conducted that confirmed the pathogenic nature of the fungus in a marine environment (Polglase et al., 1984). This suggests that this fungus should be included in transmission studies to determine its ability to act as a primary patho-

gen of vertebrates. It was not isolated from any lesions in our study, however, and therefore probably did not play a role in the 1997–98 outbreak. Although *P. pezizoides*, was isolated from both the severe necrotizing lesions on one of the pigmy rattlesnakes and the gloves used for manual restraint, it is unlikely that the fungus was a primary pathogen, since *P. pezizoides* has never been reported as a pathogen of vertebrates or invertebrates. Again, *P. pezizoides* should be included in transmission studies to conclusively rule it out as a pathogen in this case. Although there is no direct evidence to confirm that handling techniques were involved in the outbreak, the possible effects of stress and abrasion of the skin could have made infection more likely.

Field records indicated that only four of 16 snakes (25%) with the severe oral and facial lesions observed during the 1997–98 epidemic had been captured previously or handled by the study team. Still, field equipment could be fomites for transfer of pathogens between animals and should be disinfected as appropriate. This may necessitate having more than one set of equipment available when handling snakes, especially if snakes with lesions are encountered. A protocol for handling snakes in the field to reduce the spread of transmission of pathogens between animals is needed.

ACKNOWLEDGMENTS

We gratefully thank S. Tucker, A. Aycrigg, A. Pazzalia, and the Stetson University Pig Team for their support on the project. College of Veterinary Medicine, Journal Series Number 593.

LITERATURE CITED

- BISHOP, L. A., T. M. FARRELL, AND P. G. MAY. 1996. Sexual dimorphism in a Florida population of the rattlesnake *Sistrurus miliarius*. *Herpetologica* 52: 360–364.
- DAVIES, C., AND G. C. TROY. 1996. Deep mycotic infections in cats. *The Journal of the American Animal Hospital Association* 32: 380–391.
- ELLIS, M. B. 1972. *Dematiaceous hyphomycetes*. Commonwealth Mycological Institute, Kew, England, 608 pp.

- . 1976. More dematiaceous hyphomycetes. Commonwealth Mycological Institute, Kew, England, 512 pp.
- FARRELL, T. M., P. G. MAY, AND M. A. PILGRIM. 1995. Reproduction in the rattlesnake, *Sistrurus miliarius barbouri*, in central Florida. *Journal of Herpetology* 29: 21–27.
- FISHER, F., AND N. B. COOK. 1998. Fundamentals of diagnostic mycology. W.B. Saunders, Philadelphia, Pennsylvania, 352 pp.
- FRANK, W. 1970. Mykotische Erkrankungen der Haut und der inneren Organe bei Amphibien und Reptilien. In XII. International Symposium Erkr. Zootiere (Budap.) Berlin, Akademie Verlag.
- . 1976. Mycotic infections in amphibians and reptiles. In *Wildlife diseases*. L. A. Page (ed.). Plenum Press, New York, pp. 73–88.
- HEARD, D. J., G. H. CANTOR, E. R. JACOBSON, B. PURICH, L. AJELLO, AND A. A. PADHYE. 1986. Hyalohyphomycosis caused by *Paecilomyces lilacinus* in an Aldabra tortoise. *Journal of the American Veterinary Medical Association* 189: 1143–1145.
- IRIZARRY-ROVIRA, A. R., L. KAUFMAN, J. A. CHRISTIAN, S. R. REBERG, S. B. ADAMS, D. B. DENICOLA, W. RIVERS, AND J. F. HAWKINS. 2000. Diagnosis of sporotrichosis in a donkey using direct fluorescein-labeled antibody testing. *Journal of Veterinary Diagnostic Investigation* 12: 180–183.
- JACOBSON, E. R. 1980. Necrotizing mycotic dermatitis in snakes—clinical and pathologic features. *Journal of the American Veterinary Medical Association* 177: 838–841.
- . 1984. Chromomycosis and fibrosarcoma in a mangrove snake. *Journal of the American Veterinary Medical Association* 185: 1428–430.
- , J. M. GASKIN, R. P. SHIELDS, AND F. H. WHITE. 1979. Mycotic pneumonia in mariculture-reared green sea turtles. *Journal of the American Veterinary Medical Association* 75: 929–933.
- JEMISON, S. C., L. A. BISHOP, P. G. MAY, AND T. M. FARRELL. 1995. The impact of PIT-tags on growth and movement of the rattlesnake, *Sistrurus miliarius*. *Journal of Herpetology* 29: 129–132.
- KARSTAD, L. 1961. Reptiles as possible reservoir hosts for eastern encephalitis virus. *Transactions North American Wildlife and Natural Resources Conference* 26: 186–202.
- KAUFFMAN, C. A. 1999. Sporotrichosis. *Clinical Infectious Diseases* 29: 231–237.
- LUNA, L. G. 1968. Manual of histologic staining methods of the Armed Forces Institute of Pathology, 3rd Edition. McGraw-Hill, New York, p. 8.
- MAKIMURA, K., S. Y. MURAYAMA, AND H. YAMAGUCHI. 1994. Detection of a wide range of medically important fungi by the polymerase chain reaction. *Journal of Medical Microbiology* 40: 358–364.
- MARCUS, L. C. 1971. Infectious diseases of reptiles. *Journal of the American Veterinary Medical Association* 159: 1626.
- MASLEN, M., J. WHITEHEAD, W. M. FORSYTH, H. MCCracken, AND A. D. HOCKING. 1988. Systemic mycotic disease of captive crocodile hatchling (*Crocodylus porosus*) caused by *Paecilomyces lilacinus*. *Journal of Medical and Veterinary Mycology* 26: 219–225.
- MAY, P. G., T. M. FARRELL, S. T. HEULETT, M. A. PILGRIM, L. A. BISHOP, D. J. SPENCE, A. M. RABATSKY, M. G. CAMPBELL, A. D. AYCRIGG, AND W. E. RICHARDSON. 1996. Seasonal abundance and activity of a rattlesnake (*Sistrurus miliarius barbouri*) in central Florida. *Copeia* 1996: 389–401.
- MCKENZIE, R. A., AND P. E. GREEN. 1976. Mycotic dermatitis in captive carpet snakes. *Journal of Wildlife Diseases* 12: 405.
- MONTALI, R. J. 1988. Comparative pathology of inflammation in the higher vertebrates (reptiles, birds and mammals). *Journal of Comparative Pathology* 99: 1–26.
- POLGLASE, J. L., N. J. DIX, AND A. M. BULLOCK. 1984. Infection of skin wounds in the lesser octopus, *Eledone cirrhosa*, by *Cladosporium sphaerospermum*. *Transactions of the British Mycological Society* 82: 577–580.
- RABATSKY, A. M., AND T. M. FARRELL. 1996. The effects of age and light level on foraging posture and frequency of caudal luring in the rattlesnake, *Sistrurus miliarius barbouri*. *Journal of Herpetology* 30: 558–561.
- RIPPON, J. W. 1988. Medical mycology: The pathogenic fungi and the pathogenic actinomycetes. W. B. Saunders, Philadelphia, Pennsylvania, 797 pp.
- ROTH, E. D., P. G. MAY, AND T. M. FARRELL. 1999. Pigmy rattlesnakes use frog-derived chemical cues to select foraging sites. *Copeia* 1999: 772–774.
- SANDHU, G. S., B. C. KLINE, L. STOCKMAN, AND G. D. ROBERTS. 1995. Molecular probes for diagnosis of fungal infections. *Journal of Clinical Microbiology* 33: 2913–2919.
- WENKER, C. J., L. KAUFMAN, L. N. BACCARIANI, AND N. ROBERT. 1998. Sporotrichosis in a nine-banded armadillo (*Dasypus novemcinctus*). *Journal of Zoo and Wildlife Medicine* 29: 474–478.
- WERNER, R., M. A. BALADY, AND G. J. KOLAJA. 1978. Phycomycotic dermatitis in an eastern Indigo Snake. *Veterinary Medicine and Small Animal Clinician* 73: 362–363.
- WILLIAMS, L. W., E. R. JACOBSON, K. N. GELATT, K. P. BARRIE, AND R. P. SHIELDS. 1979. Phycomycosis in a western massasaugua rattlesnake (*Sistrurus catenatus*) with infection of the telenceph-

- alon, orbit, and facial structures. *Veterinary Medicine, Small Animal Clinician* 74: 1181–1184.
- VISSIENNON, T., K. F. SCHUPPEL, E. ULLRICH, AND A. F. KUIJPERS. 1999. Case report: Disseminated infection due to *Chrysosporium queenslandicum* in a garter snake (*Thamnophis*). *Mycoses* 42: 107–110.
- ZWART, P. 1968. Parasitare und mykotische Lungenaffektionen bei Reptilien. In X. International Symposium Erkr. Zootiere (Salzburg) Berlin, Akademie Verlag, p. 45.

Received for publication 25 June 2002.