

PATHOLOGIC CONFIRMATION OF MALARIA (*Plasmodium elongatum*) IN AFRICAN PENGUINS (*Spheniscus demersus*)

Authors: FLEISCHMAN, ROBERT W., SQUIRE, ROBERT A.,
SLADEN, W. J. L., and MOORE, JOHN

Source: Bulletin of the Wildlife Disease Association, 4(4) : 133-135

Published By: Wildlife Disease Association

URL: <https://doi.org/10.7589/0090-3558-4.4.133>

BioOne Complete (complete.BioOne.org) is a full-text database of 200 subscribed and open-access titles in the biological, ecological, and environmental sciences published by nonprofit societies, associations, museums, institutions, and presses.

Your use of this PDF, the BioOne Complete website, and all posted and associated content indicates your acceptance of BioOne's Terms of Use, available at www.bioone.org/terms-of-use.

Usage of BioOne Complete content is strictly limited to personal, educational, and non - commercial use. Commercial inquiries or rights and permissions requests should be directed to the individual publisher as copyright holder.

BioOne sees sustainable scholarly publishing as an inherently collaborative enterprise connecting authors, nonprofit publishers, academic institutions, research libraries, and research funders in the common goal of maximizing access to critical research.

PATHOLOGIC CONFIRMATION OF MALARIA (*Plasmodium elongatum*) IN AFRICAN PENGUINS (*Spheniscus demersus*)

Between August 4 and December 13, 1967, a total of eighteen African penguins (*Spheniscus demersus*) died at the Baltimore Zoo. Among the eighteen were six histologically confirmed cases of malaria. The parasite was demonstrated to be *Plasmodium elongatum*, (Herman et. al., Bull. Wild. Dis. Assn., 4: 132, 1968) by inoculating blood and organ emulsions from an infected penguin into ducks and canaries.

The clinical course in all cases was acute with the only signs being anorexia and vomiting. External examination revealed all of the penguins to be in excellent physical condition. The gross lesions noted were subcutaneous, pulmonary, and epicardial edema, hydropericardium and hepato-splenomegaly. Peripheral blood smears in five out of six affected penguins failed to show any gametocytes but did contain rare trophozoites and immature erythrocytic schizonts. Microscopically the most striking feature in these five birds was exoerythrocytic schizogony affecting a variety of tissues (Figs. 1 and 2). The greatest number of exoerythrocytic schizonts were found in the lungs, followed by spleen, liver, and heart. Fewer numbers were present in the kidneys, skeletal muscles, intestine, brain, and bone marrow. The schizonts generally appeared to be in histiocytes. In addition to the exoerythrocytic

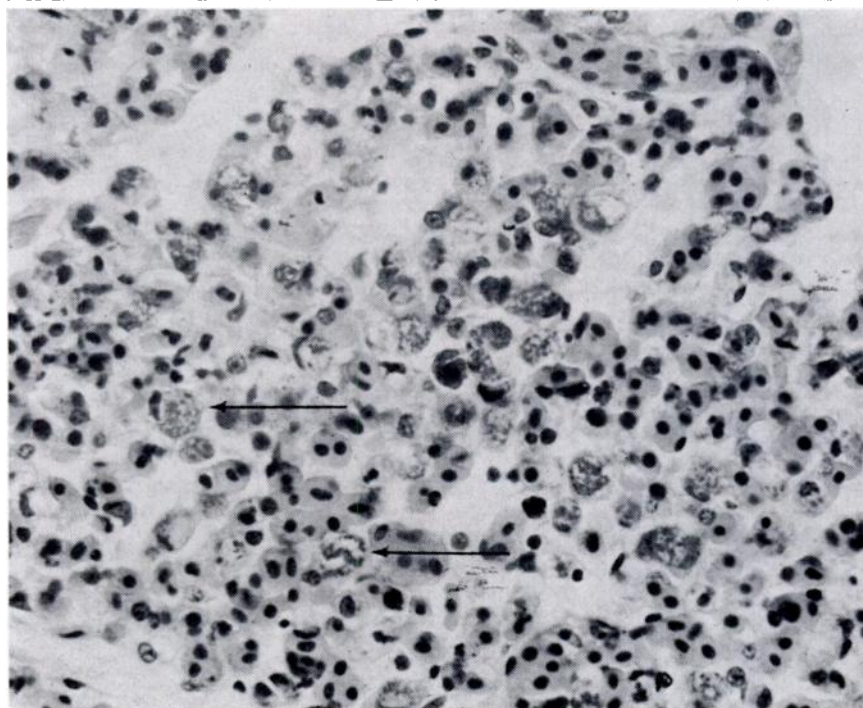


FIGURE 1: Numerous exoerythrocytic schizonts in the lung (arrows). (Hematoxylin and eosin stain; x550).

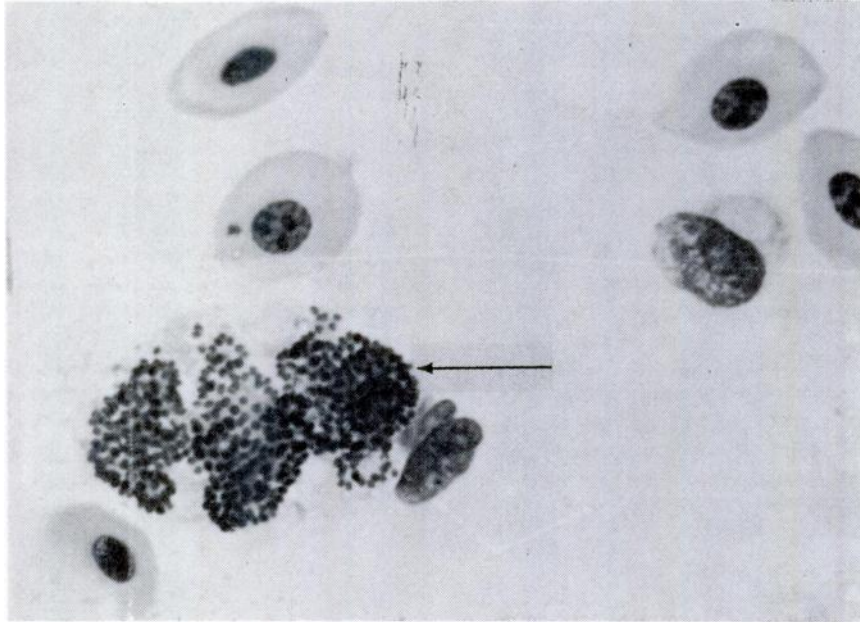


FIGURE 2: Lung imprint. Detail of an exoerythrocytic schizont within a macrophage (arrow). (May Grunwald - Giemsa stain; x1650).

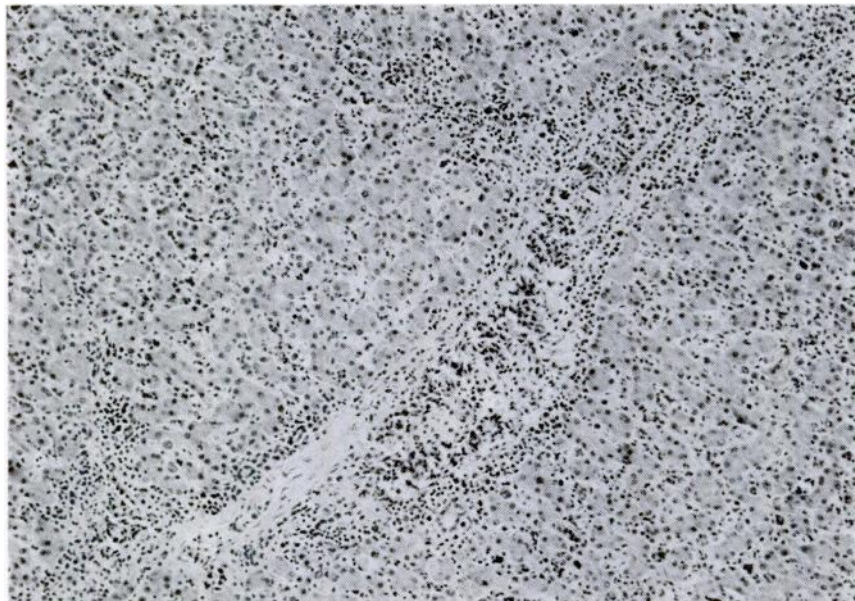


FIGURE 3: Portal and sinusoidal distribution of liver infiltrate. (Hematoxylin and eosin stain; x180).

schizogony, an inflammatory infiltrate consisting of lymphoreticular cells was found in the lungs, livers, and spleens of all of the penguins (Fig. 3). The livers also showed extramedullary hematopoiesis. The bone marrow was very cellular in all cases showing both myeloid and erythroid hyperplasia.

In the sixth penguin, which was used for the canary and duck inoculations, there were no exoerythrocytic schizonts in the tissues; but gametocytes as well as trophozoites and immature schizonts were present in peripheral blood erythrocytes. The hematocrit in this penguin was 27.5 compared with normal values of 40-44 determined in apparently normal penguins. Hematocrit values for the other five penguins were not determined. There was no malarial pigment in any of the tissues.

A complete clinico-pathologic description of this outbreak is in preparation. In so far as we know, this is the first occurrence of *Plasmodium elongatum* reported in African penguins.

ROBERT W. FLEISCHMAN
ROBERT A. SQUIRE

Department of Pathology
Johns Hopkins Hospital
Baltimore, Maryland 21205

W. J. L. SLADEN

Department of Pathobiology
School of Public Health and Hygiene
Johns Hopkins University
Baltimore, Maryland 21205

JOHN MOORE

Assistant Director
Baltimore Zoo
Baltimore, Maryland 21205

May 28, 1968

ECTOPARASITIC INFECTIONS ON FISH OF VOLTA LAKE, GHANA

The construction of Akosombo Dam in 1964, resulted in the inundation of the Volta River basin, forming the largest known man-made lake.

Unfortunately, limited data are available on the ectoparasites of fish in the Volta River before inundation. In a survey conducted by Thomas on the Black Volta only one species of Monogenea was found (Thomas J. D., 1957, J. W. Afr. Sci. Ass. 3:178). In a later study carried out by Prah et al. in 1964 quote: "About 1.7% of 405 fish from the Volta Lake and rivers draining into it, showed helminthic infection with *Clinostomum* sp. and copepod infection with *Lernaea* sp. and *Ergasilus* sp." (Prah, S. K. et al. 1966, Man-made lake Inter. Symp. Accra).