



Endoparasites of Western Lowland Gorillas (*Gorilla gorilla gorilla*) at Bai Hokou, Central African Republic

Authors: Freeman, Andrea S., Kinsella, John M., Cipolletta, Chloe, Deem, Sharon L., and Karesh, William B.

Source: Journal of Wildlife Diseases, 40(4) : 775-781

Published By: Wildlife Disease Association

URL: <https://doi.org/10.7589/0090-3558-40.4.775>

BioOne Complete (complete.BioOne.org) is a full-text database of 200 subscribed and open-access titles in the biological, ecological, and environmental sciences published by nonprofit societies, associations, museums, institutions, and presses.

Your use of this PDF, the BioOne Complete website, and all posted and associated content indicates your acceptance of BioOne's Terms of Use, available at www.bioone.org/terms-of-use.

Usage of BioOne Complete content is strictly limited to personal, educational, and non - commercial use. Commercial inquiries or rights and permissions requests should be directed to the individual publisher as copyright holder.

BioOne sees sustainable scholarly publishing as an inherently collaborative enterprise connecting authors, nonprofit publishers, academic institutions, research libraries, and research funders in the common goal of maximizing access to critical research.

Endoparasites of Western Lowland Gorillas (*Gorilla gorilla gorilla*) at Bai Hokou, Central African Republic

Andrea S. Freeman,^{1,4,6} John M. Kinsella,² Chloe Cipolletta,³ Sharon L. Deem,^{1,5} and William B. Karesh¹

¹ Field Veterinary Program, Wildlife Conservation Society, 185th Street and Southern Boulevard, Bronx, New York 10460, USA; ² HelmWest Laboratory, 2108 Hilda Avenue, Missoula, Montana 59801, USA; ³ World Wildlife Fund, Dzanga-Sangha National Park, Bayanga, Central African Republic; ⁴ Current address: Department of Pathobiology, School of Veterinary Medicine, University of Pennsylvania, 3800 Spruce Street, Philadelphia, Pennsylvania 19104, USA; ⁵ Current address: Department of Animal Health, Smithsonian's National Zoological Park, Washington, DC 20008, USA; ⁶ Corresponding author (email: andrea@vet.upenn.edu)

ABSTRACT: A coprologic study of free-ranging western lowland gorillas (*Gorilla gorilla gorilla*) at Bai Hokou, Dzangha-Ndoki National Park, Central African Republic (2°51'34"N, 16°28'03"E) was conducted from October 1999 to November 2000. All 75 fecal samples examined were positive for endoparasites, and each contained at least two species. Parasites present included two genera of amoebae, entodiniomorph ciliates, including *Prototapirella gorillae*, *Troglodytella* spp., and *Gorillophilus thoracatus*, a *Balantidium*-like organism, strongyle/trichostrongyle eggs (including a presumptive *Mammomonogamus* sp. and several other genera), *Strongyloides* sp., *Probstmayria* sp., a spirurid, a trichuroid, and several unidentified trematodes. Flagellates and cestodes were not found. Despite the presence of a variety of parasite genera, in general, levels of parasitism were low. These data provide baseline parasitologic data for this population as part of a comprehensive health-monitoring program. With the advent of ecotourism in this study area, continued monitoring is indicated for insuring the health of both gorillas and humans in the Bai Hokou study area.

Key words: Ecotourism, endoparasite, entodiniomorph ciliate, *Gorilla gorilla*, habituation, lowland gorillas, *Mammomonogamus*.

The number of coprologic studies to survey the prevalence of parasites in wild gorilla populations is limited. Sleeman et al. (2000) examined 74 fecal samples from mountain gorillas (*Gorilla gorilla beringei*) in Rwanda. Ashford et al. (1996) conducted a larger study ($n=305$) on mountain gorillas in Uganda and Hastings et al. (1992) examined 128 samples from mountain gorillas in Rwanda and the Democratic Republic of Congo. Three coprologic studies of western lowland gorillas (*Gorilla gorilla gorilla*) have been reported: Goussard et al. (1983) examined 109 samples from Ga-

bon; Landsoud-Soukate et al. (1995) examined 61 samples, also from Gabon; and Lilly et al. (2002) examined 156 samples from Dzanga-Ndoki National Park, Central African Republic. Many species of parasites have been identified from gorillas in the wild, including protozoans, nematodes, cestodes, and trematodes.

In an effort to monitor the health of western lowland gorillas in the wild, a comprehensive health-monitoring program was established at Bai Hokou, located in Dzanga-Ndoki National Park (DNNP), Central African Republic, prior to commencement of ecotourism in the area. Coprologic examinations of feces allow identification of parasite species present in gorilla populations and assessment of the relative abundance of these parasites. Changes in species and/or abundances following commencement of ecotourism might provide insights into the impact of tourism on health of the animals.

Fecal samples were collected from free-ranging western lowland gorillas from October 1999 to November 2000 at the Bai Hokou Gorilla Study Site (BH) located in southwestern Central African Republic (2°51'34"N, 16°28'03"E). The BH study site encompasses 50 km² and is located within the northern Dzanga region of the DNNP. The national park was established in December 1990 and is located within the larger Dzanga-Sangha Dense Special Forest Reserve (3,500 km²) established in the mid-1980s. The Sangha River transects the reserve and drains into the Congo River; thus, this area forms the northern extension of the forests of the Congo Basin.

Within the reserve, the human population is low, approximately one person per km². The area undergoes considerable seasonal fluctuations in rainfall, with a long rainy season from March to November and a shorter dry season from December to February. Annual rainfall is approximately 1,745 mm and average temperature is 23.5 C, with little variation in temperature between months. In addition to lowland gorillas, the area contains a diverse collection of mammals, including forest elephants (*Loxodonta africana*), buffalo (*Syncerus caffer*), leopards (*Panthera pardus*), and 12 species of nonhuman primates (Goldsmith, 1996). Several gorilla groups have been habituated or are in the process of human habituation at BH. These include Munye group, Groups 2, 3, and 5. Several unidentified lone adult males are also known to inhabit BH.

Fecal samples were collected from gorilla night nests the morning after sample deposition in the nests. Each sample was marked with the time of collection, estimated age of the sample, sample diameter, and abnormalities were recorded. Whenever known, the social group, sex, age, and identification of the individual were noted. Fecal samples were collected from four known gorilla groups (Munye group, Groups 2, 3, and 5), several unknown or unidentified groups, and several lone adult males. Each dung pile was wrapped in leaves and brought back to the BH research station and a sample placed in a bottle containing 10% buffered formalin. Most samples were estimated to be less than 6 hr old at the time of fixation; however, several samples may have been as old as 10–11 hr by the time they were formalin fixed. Samples were stored at room temperature at BH until they were shipped under CITES Permit 01US033594/9 to the Wildlife Conservation Society's Field Veterinary Laboratory in Bronx, New York, USA, and stored there at room temperature until examined.

Each fecal sample was prepared by ethyl acetate sedimentation, stained with Lu-

gol's iodine, and several drops examined under a light microscope. As a result of the method of collection, the Cornell-McMaster dilution egg-counting technique, although preferable for quantifying parasite loads via egg counts, was not feasible. Instead, parasite abundances in each sample were quantified using a scale of 0 to +5, corresponding to the number of each parasite found per microscope field.

Seventy-five fecal samples were examined. Thirty-five of these were from individuals in Munye group, 14 were from Group 2, one from Group 3, two from Group 5, three from lone adult males, and 20 were from unknown or unidentified gorilla groups. Ten parasite genera were identified as well as a number of unclassified strongyle/trichostrongyles, one or more spirurids and trematodes, one unidentified trichuroid, and one unidentified entodiniomorph corresponding to Type B of Goussard et al. (1983) (Table 1). All samples had at least two parasite genera present.

Three genera of amoebae occurred in extremely low abundances and all were quantified as +1. *Endolimax* were identified in nine samples; however, seven of these were from the Munye group. *Entamoeba* cysts were present in 11 samples, seven of which were from Munye group. *Blastocystis* sp. was found in one sample from an unidentified individual in the Munye group. Several *Balantidium coli*-like trophozoites were found in a single sample from the 2–3-yr-old male infant in the Munye group. However, six other samples were collected from this same individual a month or more apart and none of these additional samples contained *B. coli*-like organisms.

Entodiniomorph ciliates were common (81% of the samples) in the gorillas at BH. *Gorillophilus thoracatus* was identified in three samples; one from the Munye group and two from unknown/unidentified groups. *Prototapirella gorillae* and *Trogloodytella* spp. (a complex of at least three species, including *Trogloodytella gabonen-*

TABLE 1. Prevalence of parasites in 75 western lowland gorillas (*Gorilla gorilla gorilla*) at Bai Hokou, Central African Republic.

Parasite	Number of samples positive and prevalence	(%)
<i>Blastocystis</i> sp.	2	(3)
<i>Endolimax</i> sp.	9	(12)
<i>Entamoeba</i> sp.	11	(15)
<i>Balantidium</i> -like ciliate	1	(1)
<i>Gorilophilus thoracatus</i>	3	(4)
<i>Prototapirella gorillae</i>	55	(73)
<i>Trogloidyrella</i> spp. ^a	27	(36)
Other Entodiniomorphs (Type B)	1	(1)
Strongyle/trichostrongyle ^b	75	(100)
<i>Mammomonogamus</i> sp. eggs	62	(83)
<i>Strongyloides</i> sp. eggs	15	(20)
<i>Probstmayria</i> sp. larva	1	(1)
Spirurid eggs	21	(28)
Trematode eggs	17	(23)
Unidentified trichuroid eggs	1	(1)

^a A complex of at least three species, including *Trogloidyrella gabonensis*.

^b Does not include *Mammomonogamus* sp.

sis), were common coparasites in a number of samples. Two samples had abundances of *P. gorillae* of +3 and +5; however, the rest were quantified as +1. *Trogloidyrella* spp. were less prevalent than *P. gorillae* and in all cases were scored as +1. The Type B entodiniomorph, apparently an undescribed species, was found in a single sample from the adult male of the Mune group.

Strongyle/trichostrongyle eggs were present in all samples. Despite their distribution throughout the study population, infection levels were low in most animals (+1), although several samples were scored as +2 and one as +5. All other helminths were present at low abundances. Because of the difficulty in differentiating strongyles on the basis of egg size and morphology, the genera and species present could not be identified, with the exception of a presumptive *Mammomonogamus* sp., present in 83% of the samples. Both thin- and thick-shelled strongyle-type eggs were present. Several samples had strongyle eggs containing larva.

Eggs of *Strongyloides* sp. but no *Strongyloides* larvae were found in the feces. Spirurid eggs were found in 28% of the

samples. A *Probstmayria* sp. larva was found in one sample from an individual from an unknown/unidentified group. The only sample from an unknown individual from Group 3 contained a bipolar, 58×25 μm, trichuroid egg. Trematode eggs were present in 23% of the samples. No cestode eggs were found in any sample.

A similar study of lowland gorillas in about the same time period was conducted in the southern Ndoki sector of the DNNP by Lilly et al. (2002), who examined 156 fecal samples. Prevalences of *Entamoeba* spp., *Balantidium* sp., strongylates, and *Strongyloides* sp. were similar to our study, as was the absence of *Giardia* and *Chilomastix*. Entodiniomorph ciliates were also reported as common, but prevalences were not reported. No spirurid eggs were reported in their study; however, the authors found 22% of their samples contained ascaroid eggs, which were absent in our samples. More investigation is needed to resolve these discrepancies.

Because many gorilla parasite species are present in low prevalence, differences in techniques with regard to sample size, amount of sample examined, concentration, and examination methods, and inter-

observer error are important. Thus, small differences in the prevalence of rare parasites should be interpreted with caution. Nizeyi et al. (1999) and Graczyk et al. (2002) used a more sensitive immunofluorescent antibody technique to detect *Giardia* cysts in 2% and *Cryptosporidium* sp. cysts in 11% of mountain gorillas in Uganda. Application of these methods may also reveal the presence of these parasites in lowland gorillas.

Entamoeba sp. and *Endolimax* sp. occurred in low frequencies. The species are probably *Entamoeba coli* and *Endolimax nana* based on size and morphology, although conclusive identification was not possible. Lilly et al. (2002) reported low prevalences of amoebae (including *Entamoeba coli*, *E. histolytica*, and *Iodamoeba butschlii*). In contrast, the Virunga Volcanoes' mountain gorilla population in Rwanda had a high prevalence of amoebae (Sleeman et al., 2000). These authors suggested that humans were a likely source of these amoebae as a result of a long history of close contact between humans and gorillas at their study site. Although this possibility requires further investigation, close monitoring of these species in the BH population is indicated, particularly with the advent of ecotourism in the area.

Abundance of entodiniomorph ciliates in the BH gorilla population was similar to the lowland gorillas at the Mondika Research Site, also in DNNP (Lilly et al., 2002), the lowland gorillas in Gabon (Landsoud-Soukate et al., 1995), and the mountain gorillas in Uganda (Ashford et al., 1996). Failure to detect these ciliates in the study of mountain gorillas of Rwanda (Sleeman et al., 2000) may be due to preparation methods.

Balantidiasis, although well-documented in captive primate populations, has only been reported once in free-ranging gorillas (Lilly et al., 2002). While this may be a result of poor preservation of this parasite in chemical fixatives and may not be indicative of the true absence of this parasite in the wild, a coprologic study of three

species of captive and wild-trapped African nonhuman primates using formalin as a preservative and modified formal-ether sedimentation as a preparation technique reported a *B. coli* prevalence of 40.3% (127 of 315 samples) (Munene et al., 1998). Thus, use of formalin as a preservative and formalin-ethyl acetate sedimentation, as employed in this study, appears to be an adequate method for detection of this parasite. Using these methods, only one of 75 samples contained a *Balantidium*-like organism. Because this sample was from the 2–3-yr-old male infant in Munye group, from which six other samples were also collected and were negative, this parasite appears to be extremely rare within the gorilla population at BH. This emphasizes the importance of establishing an adequate sample size to detect rare parasites as well as the importance of selecting appropriately sensitive methods.

Strongyles of three genera (*Oesophagostomum*, *Murshidia*, *Ternidens*) and trichostrongyles of two genera (*Paralibyostrongylus*, *Hyostrongylus*) have been found in free-living gorillas at necropsy (Durette-Desset et al., 1992; Hastings et al., 1992). Ashford et al. (1996) found that strongyle eggs could be clustered into groups based on morphometric data but individual eggs could not be identified. The presence of both thick- and thin-shelled eggs in this study, combined with the wide range in egg measurements, indicates that multiple species are probably present at BH.

Identification of *Mammomonogamus* sp. (family, Syngamidae) was based on its distinct appearance (a large, pinkish ellipsoid egg with a striated surface, containing usually two, but sometimes one or three, blastomeres). Although not reported in gorillas, *Mammomonogamus* spp. are tracheal parasites that affect many species, including buffalo (*Syncerus caffer*) (Graber et al., 1972), elephants (*L. africana*), okapi (*Okaapia johnstoni*), and humans (Mornex et al., 1980; Nosanchuk et al., 1995; Li et al., 1997). The *Mammomonogamus* eggs found in this study and eggs dissected

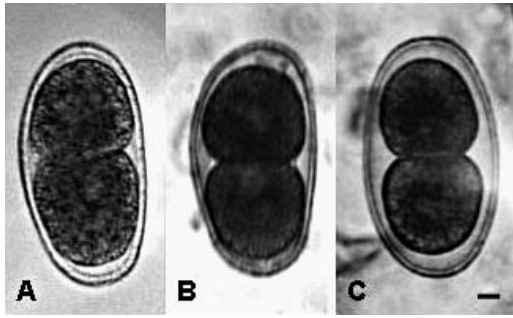


FIGURE 1. Comparison of *Mammomonogamus* eggs from an African forest elephant (*Loxodonta africana*) and a western lowland gorilla (*Gorilla gorilla gorilla*) from Bai Hokou, Central African Republic. A. *Mammomonogamus loxodontis* egg dissected from a female *M. loxodontis* worm. B. *Mammomonogamus* egg (presumably *M. loxodontis*) from an African elephant fecal sample (Kinsella et al., 2004). C. *Mammomonogamus* egg from a fecal sample from a gorilla at Bai Hokou. Scale bar = 10 μ m.

from a voucher specimen of *M. loxodontis* borrowed from the Natural History Museum in London (UK) and eggs from an African elephant fecal sample (presumably *M. loxodontis*) (Kinsella et al., 2004) were similar (Fig. 1). Because human infections with ruminant species of *Mammomonogamus* are relatively common, it is possible that gorillas also acquire infections from ecologic associates. Until specimens are collected from the trachea of gorillas, it is impossible to determine if this is a new species.

Although *Strongyloides* sp. larvated eggs were identified in eight samples, the species could not be identified in the absence of adult worms. Ashford et al. (1990, 1996) identified *Strongyloides fuelleborni* in the Bwindi mountain gorilla population and Sleeman et al. (2000) suggested *S. fuelleborni* was in their mountain gorilla samples. Landsoud-Soukate et al. (1995) were unable to identify the species of *Strongyloides* present in their lowland gorilla samples. *Strongyloides stercoralis* parasitizes humans as well as captive gorillas; however, in this species, larvated eggs are not present in the feces. Instead, *S. stercoralis* eggs hatch within the primary host, producing first-stage larvae that are then de-

posited in the feces. As a result, it is likely that the *Strongyloides* eggs in the samples from the BH gorillas are not *S. stercoralis* but instead are *S. fuelleborni*.

A distinctive, thick-walled larvated spirurid egg was found in 17% of the samples. Chabaud and Rousselot (1956) reported *Protospirura muricola* from a gorilla captured in the Congo and also described a new species of spirurid, *Chitwoodspirura wehri*, from the same individual. Only an immature female of *C. wehri* was found so the eggs were not described. Noda and Yomada (1964) collected gravid *C. wehri* from a lowland gorilla that was captured in the Congo and died at a Japanese zoo. They described the eggs as 42–46 μ m long with micropyle-like structures at both ends. The spirurid eggs in our study were larger and lacked these structures so they probably are not *C. wehri*. They are, however, the first spirurid eggs to be reported from gorilla feces and could either be *P. muricola* or an undescribed species.

Cestodes are reported to be abundant in mountain gorillas. *Anoplocephala gorillae* is found in frequencies of 51–92% (Redmond, 1983; Ashford et al., 1990, 1996; Sleeman et al., 2000) depending on the season. Hastings et al. (1992) also reported the presence of *A. gorillae* but did not report the prevalence of this parasite. Cestodes were not found in the lowland gorillas of Gabon (Landsoud-Soukate et al., 1995) nor were any found in the BH lowland gorilla population. Lilly et al. (2002) found tapeworm eggs in two of 156 lowland gorillas in the southern DNNP. The scarcity of cestodes in lowland gorillas compared with mountain gorillas may be the result of microhabitat differences. Specifically, lowland gorilla habitat may not contain adequate intermediate hosts, presumably oribatid mites, required for completion of the cestode life cycle.

Although differences in methodology should be considered in interpreting site-to-site differences in parasites detected, other variables may be responsible. In-

creased gorilla population densities results in increased contact between gorillas and facilitates transmission of their parasites, both directly as well as indirectly through contaminated vegetation and contact with soil and water.

Local human population densities may influence the levels of parasite infection. Because humans and gorillas are capable of exchanging many parasites (Sleeman, 1998; Deem et al., 2001; Woodford et al., 2002), direct and indirect contact with humans has the potential to alter gorilla parasite burdens. In addition, anthropogenic habitat destruction may result in drastic changes in microhabitats that could change the parasites present.

Variation in parasite abundances at different sites is related to more than host subspecies. It also depends on the habitat of the gorillas and site-specific anthropogenic factors. Ecotourism is one such factor, with the potential to facilitate transmission of anthroponozoonotic diseases, thereby influencing the parasite fauna of humans and gorillas (Woodford et al., 2002). Fecal samples are easy to obtain and once collected can be stored in preservatives for long periods of time, allowing for parasitologic examination at a later time or at an offsite location. Resulting data on parasite burdens is an important component of a site-specific health assessment plans for gorilla populations. These data are necessary for understanding the impact of human activities and management efforts on wildlife and human populations and to develop responsible long-term conservation strategies.

We thank the government of the Central African Republic for permission to work in the DNNP. The authors also thank the Dzanga-Sangha Project, in particular, L. Steel for her support of the Health Monitoring Program, of which this study is a part. Special thanks to G. Graziani and the field staff at Bai Hokou for collection of fecal samples. Thank you also to V. Greco, L. Starr, and P. Manning for technical support. The authors are grateful to E.

Harris at the Museum of Natural History, London, for loan of vouchers, and to E. Sterling for comments on an early version of this manuscript. This research was supported in part by the Wildlife Conservation Society and World Wildlife Fund.

LITERATURE CITED

- ASHFORD, R. W., H. LAWSON, T. M. BUTYNSKI, AND G. D. F. REID. 1996. Patterns of intestinal parasitism in the mountain gorilla, *Gorilla gorilla*, in the Bwindi-Impenetrable Forest, Uganda. *Journal of Zoology* 239: 507–514.
- , G. D. F. REID, AND T. M. BUTYNSKI. 1990. The intestinal faunas of man and mountain gorillas in a shared habitat. *Annals of Tropical Medicine and Parasitology* 84: 337–340.
- CHABAUD, A. G., AND R. ROUSSELOT. 1956. Un nouveau Spiruridé parasite du gorille, *Chitwoodspirura wehri*, n.g.n.sp. *Bulletin de la Societe de Pathologie Exotique* 49: 467–472.
- DEEM, S. L., W. B. KARESH, AND A. WEISMAN. 2001. Putting theory into practice: Wildlife health in conservation. *Conservation Biology* 15: 1224–1233.
- DURETTE-DESSET, M. C., A. G. CHAUBAUD, R. W. ASHFORD, T. BUTYNSKI, AND G. F. REID. 1992. Two new species of the Trichostrongylidae (Nematoda: Trichostrongyloidea), parasite in *Gorilla gorilla beringei* in Uganda. *Systematic Parasitology* 23: 159–166.
- GOLDSMITH, M. L. 1996. Ecological influences on the ranging and grouping behavior of western lowland gorillas at Bai Hokou, Central African Republic. PhD Dissertation, State University of New York at Stony Brook, 403 pp.
- GOUSSARD, B., J.-Y. COLLET, Y. GARIN, C. E. G. TUTIN, AND M. GERNANDEZ. 1983. The intestinal entodiniomorph ciliates of wild lowland gorillas (*Gorilla gorilla gorilla*) in Gabon, West Africa. *Journal of Medical Primatology* 12: 239–249.
- GRABER, M., J. EUZEBY, P. M. TRONCY, AND J. THAL. 1972. Parasites collected in Central Africa in the cardiovascular system of the buffalo (*Bubalu (syncerus) caffer*; Sparrman, 1779) and of diverse antelopes. *Revue d'Elevage et de Medicine Veterinaire des Pays Tropicaux* 25: 219–243.
- GRACZYK, T. K., J. B. NIZEYI, B. SSEBIDE, R. C. A. THOMPSON, C. READ, AND M. R. CRANFIELD. 2002. Anthroponozoonotic *Giardia duodenalis* genotype (Assemblage) A infections in habitats of free-ranging human-habituated gorillas, Uganda. *Journal of Parasitology* 88: 905–909.
- HASTINGS, B. E., L. M. GIBBONS, AND J. E. WILLIAMS. 1992. Parasites of free-ranging mountain gorillas: Survey and epidemiological factors. *Proceedings of the American Association of Zoo Veterinarians* 1992: 301–302.

- KINSELLA, J. M., S. L. DEEM, S. BLAKE, AND A. S. FREEMAN. 2004. Endoparasites of African forest elephants from the Republic of Congo and Central African Republic. *Comparative Parasitology* 71: 104–110.
- LANDSOUD-SOUKATE, J. C., E. G. TUTIN, AND M. FERNANDEZ. 1995. Intestinal parasites of sympatric gorillas and chimpanzees in the Lopé Reserve, Gabon. *Annals of Tropical Medicine and Parasitology* 89: 73–79.
- LI, D. N., G. Y. LI, AND X. M. ZHAN. 1997. Three cases of human *Mammomonogamus laryngeus* infection. *Chinese Journal of Parasitology and Parasitic Diseases* 15: 281–284.
- LILLY, A. A., P. T. MEHLMAN, AND D. DORAN. 2002. Intestinal parasites in gorillas, chimpanzees, and humans at Mondika Research Site, Dzanga-Ndoki National Park, Central African Republic. *International Journal of Primatology* 23: 555–573.
- MUNENE, E., M. OTSYULA, D. A. N. MBAABU, W. T. MUTAHI, S. M. K. MURIUKI, AND G. M. MUCHEMI. 1998. Helminth and protozoan gastrointestinal parasites in captive and wild-trapped African non-human primates. *Veterinary Parasitology* 78: 195–201.
- MORNEX, J. F., J. MAGDELEINE, AND J. DE THORE. 1980. Human syngamosis (*Mammomonogamus nasicola*) as a cause of chronic cough in Martinique. *Nouvelle Presse Medicale* 9: 3628.
- NIZEYI, J. B., R. MWEBE, A. NANTEZA, M. R. CRANFIELD, G. R. N. N. KALEMA, AND T. K. GRACZYK. 1999. *Cryptosporidium* sp. and *Giardia* sp. infections in mountain gorillas (*Gorilla gorilla beringei*) of the Bwindi Impenetrable National Park, Uganda. *Journal of Parasitology* 85: 1084–1088.
- NODA, R., AND H. YAMADA. 1964. On two species of nematodes, *Necator gorillae* sp. nov. (Ancylostomidae) and *Chitwoodspirura wehri*, Chabaud and Rousset, 1956 (Spiruridae) from a gorilla. *Bulletin University Osaka Prefecture, Series B* 15: 175–180.
- NOSANCHUK, J. S., S. E. WADE, AND M. LANDOLF. 1995. Case report of and description of parasite of *Mammomonogamus laryngeus* (human syngamosis) infection. *Journal of Clinical Microbiology* 33: 998–1000.
- REDMOND, I. 1983. Summary of parasitology research, November 1976 to April 1978. In *Gorillas in the mist*, D. Fossey (ed.). Hodder and Stoughton, London, United Kingdom, pp. 271–286.
- SLEEMAN, J. M. 1998. Preventative medicine programme for the mountain gorillas (*Gorilla gorilla beringei*) of Rwanda: A model for other endangered primate populations. In *Proceedings of the European Association of Zoo and Wildlife Veterinarians*, P. Zwart (ed.). Chester, UK, pp. 127–132.
- , L. L. MEADER, A. B. MUDAKIKWA, J. W. FOSTER, AND S. PATTON. 2000. Gastrointestinal parasites of mountain gorillas (*Gorilla gorilla beringei*) in the Parc National des Volcans, Rwanda. *Journal of Zoo and Wildlife Medicine* 31: 322–328.
- WOODFORD, M. H., T. M. BUTYNSKI, AND W. B. KARESH. 2002. Habituating the great apes: The disease risks. *Oryx* 36: 153–160.

Received for publication 23 September 2003.