



Leucocytozoon lovati Infections in Wild Rock Ptarmigan (*Lagopus mutus*) in Japan

Authors: Hagihara, Mio, Yamaguchi, Tsuyoshi, Kitahara, Masanobu, Hirai, Katsuya, and Murata, Koichi

Source: Journal of Wildlife Diseases, 40(4) : 804-807

Published By: Wildlife Disease Association

URL: <https://doi.org/10.7589/0090-3558-40.4.804>

BioOne Complete (complete.BioOne.org) is a full-text database of 200 subscribed and open-access titles in the biological, ecological, and environmental sciences published by nonprofit societies, associations, museums, institutions, and presses.

Your use of this PDF, the BioOne Complete website, and all posted and associated content indicates your acceptance of BioOne's Terms of Use, available at www.bioone.org/terms-of-use.

Usage of BioOne Complete content is strictly limited to personal, educational, and non - commercial use. Commercial inquiries or rights and permissions requests should be directed to the individual publisher as copyright holder.

BioOne sees sustainable scholarly publishing as an inherently collaborative enterprise connecting authors, nonprofit publishers, academic institutions, research libraries, and research funders in the common goal of maximizing access to critical research.

***Leucocytozoon lovati* Infections in Wild Rock Ptarmigan (*Lagopus mutus*) in Japan**

Mio Hagihara,¹ Tsuyoshi Yamaguchi,² Masanobu Kitahara,³ Katsuya Hirai,² and Koichi Murata^{1,4} ¹ Department of Wildlife Science, College of Bioresource Sciences, Nihon University, 1866 Kameino, Fujisawa, Kanagawa 252-8510, Japan; ² Department of Veterinary Microbiology, Gifu University, 1-1 Yanagito, Gifu 501-1112, Japan; ³ Institute of Alpine Environmental Research, 12-388 Inao, Taira, Ohmachi, Nagano 398-0001, Japan; ⁴ Corresponding author (email: k-murata@brs.nihon-u.ac.jp)

ABSTRACT: *Leucocytozoon lovati* infections were detected in free-flying rock ptarmigan (*Lagopus mutus*), an endangered species that inhabits alpine areas in Japan. Eight of nine adult birds tested positive for *L. lovati* infection. For comparison, two captive rock ptarmigans hatched in a breeding facility at the foot of the mountains were examined. Both were negative for *L. lovati* infection. This is the first report of *L. lovati* infection in the rock ptarmigan in Japan.

Key words: Hematozoa, Japan, *Lagopus mutus*, *Leucocytozoon lovati*, rock ptarmigan.

Leucocytozoon spp. are hematozoan parasites that are transmitted by blood-sucking arthropods (Jordan, 1990). Currently, more than 60 species of *Leucocytozoon* have been detected from birds throughout the world (Bennett et al., 1994). Although it is rare that leucocytozoonosis is incriminated as a cause of death, it has been observed in some avian species, including waterfowl (Greiner, 1991), eagles (Stuht et al., 1999), and grouse (Clarke, 1935). *Leucocytozoon lovati* is a common parasite of birds belonging to the Tetraoninae and has a Holarctic distribution (Bennett et al., 1991). Infections have been reported in red grouse (*Lagopus lagopus scoticus*), sage grouse (*Centrocercus urophasianus*), ruffed grouse (*Bonasa umbellus*), black grouse (*Tetrao tetrix*), blue grouse (*Dendragapus obscurus*), western capercaillie (*Tetrao urogallus*), willow ptarmigan (*Lagopus lagopus*), as well as rock ptarmigan (*Lagopus mutus*) (Sambon, 1908; Fantham, 1910; Clarke, 1935; Stabler et al., 1967; Bennett et al., 1991; Forbes et al., 1994; Dunbar et al., 2003; Holmstad et al., 2003).

The rock ptarmigan is adapted to a wide range of natural habitats such as forests,

meadows, and the tundra of the Northern Hemisphere (Haneda et al., 1985). The habitat in Japan is the alpine zone in the central part of the main island, where the birds inhabit regions at 1,800–3,000 m elevation in the summer (May–August) and fly to forest areas at lower elevations from winter to early spring (September–April). The present population is estimated at about 3,000 birds and the species is listed as vulnerable in the Appendix of the Law for Conservation of Endangered Species of Wild Fauna and Flora and also designated as a protected species of one of the Special Natural Monuments under the Law for the Protection of Cultural Properties in Japan.

Currently nothing is known about the blood parasites of rock ptarmigan in Japan. The present study was undertaken to determine the presence and prevalence of *L. lovati* in populations of rock ptarmigan in two areas on the main island in Japan.

Rock ptarmigan were captured with the permission of the Ministry of the Environment of the Japanese Government on Mt. Tateyama (36°35'N, 137°36'W) at about 2,400 m elevation in April and on Mt. Jii-gatake (36°35'N, 137°45'W) at about 2,650 m elevation in June 2002. The birds were captured in the daytime by using a long fishing rod with a looped soft wire fixed at the tip. The birds were humanely restrained by hand to check the band number and confirm body condition before withdrawing a blood sample. Two adult females and three adult males were sampled in April and four adult males were sampled in June. All individuals were determined to be in good health by visual examination. For comparison, two captive

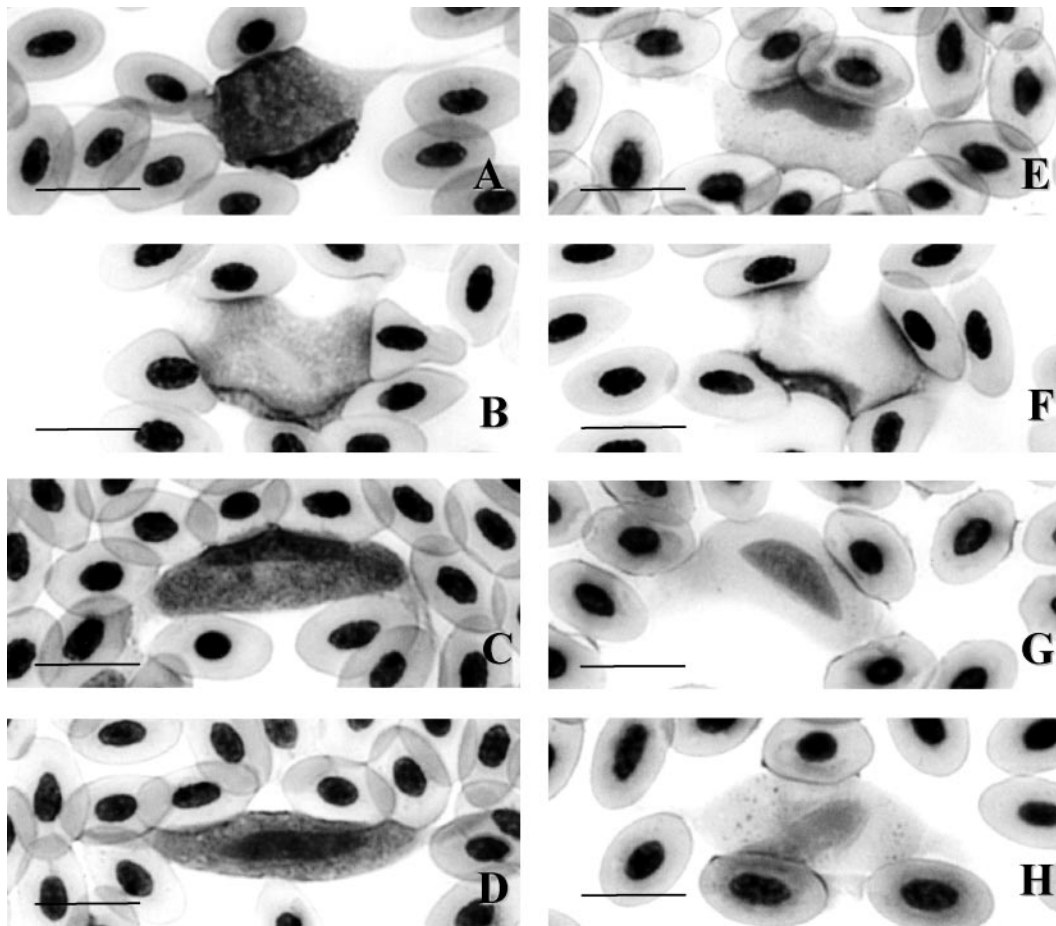


FIGURE 1. Photomicrographs of gametocytes and the host-cell complex of *Leucocytozoon lovati* from the rock ptarmigan (*Lagopus mutus*) in Japan. Macrogametocytes are shown in A–D and microgametocytes are shown in E–H. Bar=10 μ m.

adult male rock ptarmigans (3 and 8 yr old) kept in a captive-breeding facility at the Ohmachi Alpine Museum (36°30'N, 137°52'W), City of Shinano Ohmachi, Nagano Prefecture, at 880 m elevation were examined in October 2001 and 2002.

Peripheral blood was collected from the wing vein by using sodium heparin as an anticoagulant. The heparinized blood samples were transported in a cooler box (4 C) to our laboratory at Nihon University, Kanagawa Prefecture, where hematologic examinations were performed. Thin blood films were made, fixed with 99.5% ethanol, and stained with HEMACOLOR® (Merck Co., Darmstadt, Germany) in the laboratory.

The stained blood films were observed under a light microscope and about 400 leucocytes were observed on each slide. The ratio of infected cells to noninfected cells was calculated, and the intensity of parasitism was classified by the Ashford scale (Ashford et al., 1990). Parasitism was scored on a scale of 0–4 as follows: 0, no parasites in 100 fields under low magnification (100 \times); 1, one parasite; 2, 2–10 parasites; 3, 11–100 parasites; and 4, 100 or more parasites in 100 fields under high magnification (400 \times).

The morphology of micro- and macrogametocytes was studied under oil immersion (1,000 \times), and measurements were made in micrometers. The width and

TABLE 1. Morphometry of gametocytes and host cells of *Leucocytozoon lovati* from the rock ptarmigan (*Lagopus mutus*) in Japan.

Measurement	Minimum–maximum (μm)	Mean±SD (μm)
Unparasitized erythrocyte (n=60)		
Length	9.6–12.0	11.0±0.56
Width	4.8–7.7	6.5±0.51
Length of nucleus	3.8–6.7	5.0±0.55
Width of nucleus	1.9–3.9	2.4±0.37
Macrogametocyte (n=63)		
Length	2.2–27.0	17.6±4.26
Width	5.9–16.1	10.9±2.66
Length of nucleus	3.0–8.5	4.8±1.20
Width of nucleus	1.7–5.1	2.9±0.84
Length of host cell nucleus	2.2–18.6	13.7±2.91
Width of host cell nucleus	0.8–11.8	2.9±2.12
Length of host cell–parasite complex	22.0–60.8	42.7±8.94
Microgametocyte (n=64)		
Length	15.2–28.7	22.6±3.17
Width	4.7–15.2	9.1±2.51
Length of host cell nucleus	8.5–16.6	12.7±1.72
Width of host cell nucleus	4.7–15.2	9.1±2.51
Length of host cell–parasite complex	5.6–60.8	45.9±9.17

length of the gametocytes, host nuclei, and the host cells were measured by following the techniques described by Valkiūnas et al. (2002).

Representative stained blood films from infected birds have been deposited in the Meguro Parasitological Museum (4-1-1 Shimomeguro, Meguro, Tokyo 153-006, Japan; accession numbers MPM Col. 18818–18819).

Micro- and macrogametocytes of *L. lovati* were identified in four (80%) of five wild birds captured in April and four (100%) of four wild birds captured in June (Fig. 1). This is the first report of *L. lovati* in grouse in Japan. The captive birds were not infected.

The percentage of infected cells per 400 leukocytes was 0.32–12.1% (mean±SD, 2.31±3.92%) and the Ashford scale varied from 1 to 3 (mean±S.D, 1.6±1.0). No mixed infections with other hematozoa were observed.

The macrogametocytes stained a shade of blue and the nucleus stained light pink, whereas vacuoles were present in the cytoplasm. Microgametocytes stained pale

blue and the nucleus had expanded to the periphery farther than the macrogametocytes. The host cell was remarkably transformed due to the infection and several patterns of shape were observed (Fig. 1). The microgametocytes were more oval compared to the macrogametocytes. Both ends of long axis of the host cells infected with the micro- and macrogametocytes were extended. There were many mature gametocytes, but no immature gametocytes were observed. The means and standard deviations of various measurements of the gametocytes and the host cells are given in Table 1.

The measurements of the parasites in this study were not identical with those given for *L. lovati* by Sambon (1908) and Fantham (1910), but as pointed out by Bennett et al. (1991) in their redescription of this species, these parasites are highly pleomorphic. The host cell was greatly transformed by the parasite in our samples. Fantham (1910) reported that the gametocyte of *L. lovati* changes its form when growing from immature to mature stages. The various forms of the gameto-

cytes observed in this study probably represent different growth stages, although more precise studies regarding the possibility of mixed infections of more than two species of *Leucocytozoon* are needed.

In Alaska, 144 (90%) of 162 rock ptarmigan were infected with *L. lovati* (Stabler et al., 1967) and a similarly high prevalence (89%) of infection was observed among the birds in this study at Mt. Tateyama and Mt. Jiigatake. Our sample size was small, however, and additional studies are needed to determine the various facets of the prevalence of this blood parasite in ptarmigan in Japan.

The authors are indebted to the members of Ptarmigan Research Group of Toyama Prefecture and the staff of Ohmachi Alpine Museum for sampling at Mt. Tateyama, Mt. Jiigatake, and the Museum.

LITERATURE CITED

- ASHFORD, R. W., I. WYLLIE, AND I. NEWTON. 1990. *Leucocytozoon toddi* in British sparrowhawks *Accipiter nisus*: Observation on the dynamics of infection. *Journal of Natural History* 24: 1101–1107.
- BENNETT, G. F., R. A. EARLE, M. A. PEIRCE, F. W. HUCHZERMAYER, AND D. SQUIRES-PARSONS. 1991. Avian Leucocytozoidae: The leucocytozoids of the Phasianidae sensu lato. *Journal of Natural History* 25: 1407–1428.
- , M. A. PEIRCE, AND R. A. EARLE. 1994. An annotated checklist of the valid species of *Haemoproteus*, *Leucocytozoon* (Apicomplexa: Haemosporida) and *Hepatozoon* (Apicomplexa: Haemogregarinidae). *Systematic Parasitology* 29: 61–73.
- CLARKE, C. H. D. 1935. Blood parasites of ruffed grouse (*Bonasa umbellus*) and spruce grouse (*Canachites canadensis*), with description of *Leucocytozoon bonasae* n. sp. *Canadian Journal of Research* 12: 646–650.
- DUNBAR, M. R., S. TORNQUIST, AND M. R. GIOR-DANO. 2003. Blood parasites in sage-grouse from Nevada and Oregon. *Journal of Wildlife Diseases* 39: 203–208.
- FANTHAM, H. B. 1910. Observation on the parasitic protozoa of the red grouse (*Lagopus scoticus*), with a note on the grouse fly. In *Proceedings of the General Meetings for Scientific Business of the Zoological Society of London*, pp. 692–709.
- FORBES, M., P. J. WEATHERHEAD, AND G. F. BENNETT. 1994. Blood parasites of blue grouse: Variation in prevalence and patterns of interspecific association. *Oecologia* 97: 520–525.
- GREINER, E. C. 1991. Leucocytozoonosis in waterfowl and wild galliform birds. *Bulletin of the Society for Vector Ecology* 16: 84–93.
- HANEDA, K., H. NAKAMURA, A. KOIWAI, T. IIZAWA, AND K. TAJIMA. 1985. Distribution and density of the rock ptarmigan *Lagopus mutus* in the southern Japan Alps. *Tori. Bulletin of the Ornithological Society of Japan* 34: 33–48. [In Japanese with English summary.]
- HOLMSTAD, P. R., A. ANWAR, T. IEZHOVA, AND A. SKORPING. 2003. Standard sampling techniques underestimate prevalence of avian hematozoa in willow ptarmigan (*Lagopus lagopus*). *Journal of Wildlife Diseases* 39: 354–358.
- JORDAN, F. T. W. 1990. Leucocytozoonosis. In *Poultry diseases*, F. T. W. Jordan (ed.). 3rd Edition. Bailliere Tindall, London, UK, p. 245.
- SAMBON, L. R. 1908. Remarks on the avian haemoprotozoa of the genus *Leucocytozoon*, Danilewsky. *Journal of Tropical Medicine and Hygiene* 11: 245–248, 325–328.
- STABLER, R. M., N. J. KITZMILLER, AND R. B. WEEDEN. 1967. Blood parasites in rock ptarmigan from Eagle Summit, Alaska. *Journal of Parasitology* 53: 1297.
- STUHT, J. N., W. W. BOWERMAN, AND D. A. BEST. 1999. Leucocytozoonosis in nestling bald eagles in Michigan and Minnesota. *Journal of Wildlife Diseases* 35: 608–612.
- VALKIŪNAS, G., T. A. IEZHOVA, AND S. V. MIRONOV. 2002. *Leucocytozoon hamiltoni* n. sp. (Haemosporida, Leucocytozoidae) from the Bukharan great tit *Parus bokharensis*. *Journal of Parasitology* 88: 577–581.

Received for publication 23 June 2003.