



Outbreak of Avian Polyomavirus Infection with High Mortality in Recently Captured Crimson's Seedcrackers (*Pyrenestes sanguineus*)

Authors: Rossi, Giacomo, Taccini, Ennio, and Tarantino, Chiara

Source: Journal of Wildlife Diseases, 41(1) : 236-240

Published By: Wildlife Disease Association

URL: <https://doi.org/10.7589/0090-3558-41.1.236>

BioOne Complete (complete.BioOne.org) is a full-text database of 200 subscribed and open-access titles in the biological, ecological, and environmental sciences published by nonprofit societies, associations, museums, institutions, and presses.

Your use of this PDF, the BioOne Complete website, and all posted and associated content indicates your acceptance of BioOne's Terms of Use, available at www.bioone.org/terms-of-use.

Usage of BioOne Complete content is strictly limited to personal, educational, and non - commercial use. Commercial inquiries or rights and permissions requests should be directed to the individual publisher as copyright holder.

BioOne sees sustainable scholarly publishing as an inherently collaborative enterprise connecting authors, nonprofit publishers, academic institutions, research libraries, and research funders in the common goal of maximizing access to critical research.

Outbreak of Avian Polyomavirus Infection with High Mortality in Recently Captured Crimson's Seedcrackers (*Pyrenestes sanguineus*)

Giacomo Rossi,^{1,3} Ennio Taccini,² and Chiara Tarantino^{2,1} Department of Animal Science, University of Camerino, Camerino, Italy; ² Department of Animal Pathology, University of Pisa, Pisa, Italy; and ³ Corresponding author (email: giacomo.rossi@unicam.it).

ABSTRACT: Avian polyomavirus (APV) infection of recently imported Crimson's seedcrackers (*Pyrenestes sanguineus*) resulted in mortality in 56 of 70 (80%) birds in January 2000. Viral infection in these birds was characterized by diarrhea, anorexia, and lethargy, and death usually ensued within 48 to 72 hr of initial clinical signs. Bacteriologic testing resulted in consistently negative results. Histologic examination of tissues from dead birds revealed large intranuclear inclusion bodies, which at electron microscopy examination, contained 42- to 49-nm viral particles. The diagnosis of APV infection was based on immunohistochemistry and immunoelectronmicroscopy, using a monoclonal antibody specific for VP-1 major capsidic APV protein. This is the first report of an acute APV outbreak in wild, recently imported, Crimson's seedcrackers.

Key words: Immunoelectronmicroscopy, immunohistochemistry, polyomavirus, *Pyrenestes sanguineus*.

Crimson's seedcracker (*Pyrenestes sanguineus* Swanson, 1837) is a passeriform native to the area from southern Senegal and Gambia to southern Mali, Guinea Bissau, and Ivory Coast (Clement, 1993). This shy and elusive bird lives in swamps, marshes, or dense undergrowth and bushes alongside streams, rivers, or flooded rice-fields. Very little is known about diseases occurring in this species, and only two reports regarding APV infection in a colony of seedcrackers born in captivity in the United States are available (Garcia et al., 1993, 1994). A group of 70 Crimson's seedcrackers were imported from the area of Kerewan (13°48'N, 15°59'W) in western Gambia into Pisa (central Italy) in January 2000. No other avian species were present in this shipment. Upon arrival, all birds had similar signs, including anorexia, weakness, ataxia, diarrhea, and lethargy and died within 48 to 72 hr of initial clinical

signs. Birds were placed in large cages (10 birds/cage) and fed a mixture of seeds found in their area of origin. Medicated drinking water, with bacteriostatic or coccidiostatic drugs containing sulfaquinossaline, furazolidone, and menadione (Candiocidin®, Istituto Candioli, Beinasco, Torino, Italy) at 5 g/l of water, was given ad libitum to affected animals for 1 wk. Fifty-six (80%) of the 70 birds died during the week after arrival. Nine of them (13%), after a period of depression and diarrhea, became clinically normal and apparently healthy. Only five (7%) birds did not develop signs of disease.

All birds recently dead or euthanized by ether overdose in the last stages of the disease were examined at necropsy. Fresh smears of intestinal content were made and examined both for parasites and bacteria. For the latter purpose, feces was inoculated onto desoxycholate agar (Difco Laboratories, Detroit, Michigan, USA) and onto *Campylobacter* Kit Blaser (Difco Laboratories); some stool samples were enriched using selenite broth (Difco Laboratories) and then inoculated onto *Salmonella-Shigella* agar and brilliant-green agar (Difco Laboratories). For virologic examination, samples from intestinal content of dead seedcrackers were homogenized and diluted 1:5 with sterile physiologic saline and centrifuged at 15,000×G; the sediment was resuspended 1:5 in distilled water and negatively stained and examined using a JEOL 1200-EX transmission electron microscope (JEOL, Peabody, Massachusetts, USA). Blood smears were stained with May Grünwald-Giemsa (McManus and Mowry, 1960) for hemoprotozoan detection.

Samples of liver, spleen, kidney, intestine, bursa, pancreas, lungs, heart, and skin were collected from all birds, fixed in 10% buffered formalin, and embedded in paraffin; 3- μ m sections were stained using hematoxylin and eosin and periodic acid Schiff's reaction (Pearse, 1985) for histologic examination. Sections were also mounted on positively charged glass slides (Superfrost Plus, Fisher, Pittsburgh, Pennsylvania, USA), routinely deparaffinized, and then immersed in distilled water containing 15% H₂O₂ for 30 min at room temperature to inactivate endogenous peroxidases. The slides were rinsed in phosphate-buffered saline (PBS) three times for 2 min each, followed by a proteinase K (DAKO Corporation, Carpinteria, California, USA) treatment at room temperature for 6 min. To minimize nonspecific, background staining, the sections were incubated in a serum-blocking solution (10% nonimmune horse serum in 1% bovine serum albumin dissolved in PBS) for 1 hr at 37 C. The sections were then incubated with primary anti-VP-1 antibody (Khan et al., 2000), diluted 1:500 in PBS overnight in a 4 C moist chamber, rinsed in PBS, and incubated with a biotinylated antimouse secondary antibody for 45 min at room temperature. After three rinses in PBS, sections were incubated with enzyme conjugate (ABC-peroxydase complex, Vector, Burlingame, UK) for 45 min at room temperature, followed by incubation with 3,3'-diaminobenzidine solution containing H₂O₂ as substrate-chromogen for 5 min. The slides were rinsed in distilled water, rapidly counterstained with hematoxylin, and examined microscopically. Negative controls included normal bird tissues, and positive controls included passerine and psittacine bird tissues infected by APV. In addition, portions of liver, spleen, and kidney were immediately fixed in phosphate-buffered 0.1 M 2%-glutaraldehyde pH 7.4, postfixed in phosphate-buffered 1%-OsO₄, and after dehydration, embedded in Epon/Araldite (Polyscience Inc., Warrington, Pennsylvania, USA). Semithin sections

were stained with methylene blue and Azur II while for immunoelectron microscopy, ultrathin sections (70 nm) were placed on 200-mesh nickel grids supplied with formvar-carbon film (Agar Scientific Ltd., Stansted, UK), etched with sodium metaperiodate for 30 min, and floated on drops of 10% normal goat serum, 0.2% saponin, and 0.1% bovine serum albumin plus 0.05% Tween 20 in PBS bis-tris propane (BTP). Sections were then incubated for 24 hr at 4 C with either anti-VP-1 mouse monoclonal antibody (Khan et al., 2000) or nonimmune-mouse ascitic fluid (both diluted 1:10 in BTP containing 1% normal goat serum and 0.2% saponin). Finally, the sections were incubated with goat antimouse immunoglobulin-G gold conjugated, 10 nm (Sigma, Chemical Co., St. Louis, Missouri, USA) diluted 1:50 in BTP containing 1% normal goat serum and 0.2% saponin for 60 min. Grids were then fixed in 1% glutaraldehyde and stained with uranyl acetate and lead citrate and examined with a JEOL 1200-EX transmission electron microscope (JEOL). Control procedures included the use of known polyomavirus-infected tissue.

At necropsy, 56 birds had similar lesions including abdominal distension with spleno- and hepatomegaly with irregular red and yellow mottling of the liver. Hemorrhages were also observed in spleen, heart, and in some cases, skin and skeletal muscles. In most affected birds, kidneys were pale and swollen. Hydropericardium was evident. The lungs were generally congested and filled with exudate. Only seven (13%) birds had severe thickening of the intestinal walls with hemorrhage. Mild *Isospora* sp. infection was found in all 70 seedcrackers. No bacteria were isolated from cultures prepared with material collected at necropsy. Hemoprotozoan were not observed in blood smears.

Negative-stain electron microscopy of intestinal and cloacal material contained 45 nm viral particle aggregates in 18 (26%) birds. Histologically, the birds had various lesions characterized by the presence of

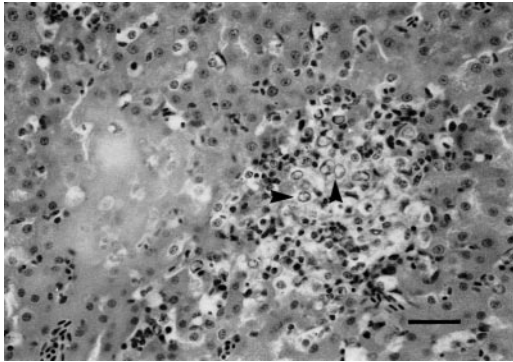


FIGURE 1. Liver of a Crimson's seedcracker with intranuclear inclusions (arrows) accompanied by hepatocellular necrosis. HE stain. Bar = 76 μ m.

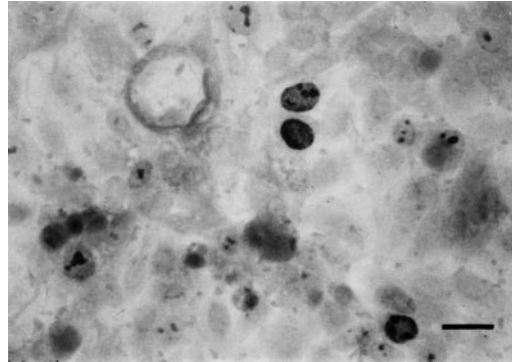


FIGURE 2. Liver of a Crimson's seedcracker with immunohistochemical positive reaction characterized by intense chromogen deposition in intranuclear inclusions. Immunohistochemistry. Bar = 25 μ m.

typical karyomegalic, amphophilic intranuclear inclusions, suggestive of an APV infection. The presence of intranuclear inclusions was accompanied by multifocal hepatocellular necrosis and hemorrhages, especially in the liver (Fig. 1). In some cases, inflammatory cell infiltrates, consisting in multifocal heterophilic to lymphoplasmacytic cells, surrounded the areas of hepatocellular necrosis. Variable degrees of epithelial necrosis, accompanied by interstitial inflammatory infiltrates, were also observed in renal, tubular epithelial cells, but in these cells, intranuclear inclusions were less frequently observed. In the spleen as well as in the bursa of 34 (61%) birds, severe depletion and lymphocytic apoptosis were observed; in the same tissues, inclusion bodies were present within intimal cells of arterioles. In addition, various degrees of myocardial necrosis were detected in 29 (52%) of birds that were necropsied.

Using monoclonal VP-1-specific antibody, APV infection was documented in tissues of all dead birds that had typical intranuclear inclusions. The positive reaction was characterized by intense-brown chromogen deposition in large inclusions (Fig. 2), indicating the VP-1-specific antibody recognition of APV. All negative-control tissues were devoid of chromogen deposition. Aggregates of 42- to 49-nm viral particles were found inside intranuclear

inclusions (Fig. 3 insert). Similar results were obtained in immunoelectronmicroscopic tests, in which endonuclear aggregates of viruses were labeled by gold particles (Fig. 3).

Acute and chronic infections of APV have been observed in various juvenile and adult psittacines (Ritchie et al., 1995) particularly in budgerigars (*Melopsittacus undulatus*) (Phalen et al., 1993). Passerine birds are sporadically infected, and reports of APV outbreaks in these birds are rare (Forshaw et al., 1988). Avian polyomavirus infections in captive passeriformes have been associated with clinical signs of sudden death or chronic weight loss, lethargy, fledgling disease, and beak abnormalities and, in one case, a tumor (Sironi and Rampin, 1987; Marshall, 1989; Woods, 1989; Rossi et al., 2003). Similar signs were described for the first time by Garcia et al. (1993) in three seedcrackers and in an outbreak of APV in a colony of seedcrackers (Garcia et al., 1994). In both episodes, birds were born in captivity, and the authors were not able to determine the origin of the virus.

The APV in seedcrackers differs from the psittacine type, based on the fact that DNA probes designed to detect APV in psittacine birds did not detect polyomavirus nucleic acid in infected seedcrackers (Garcia et al., 1994). We know of no pre-

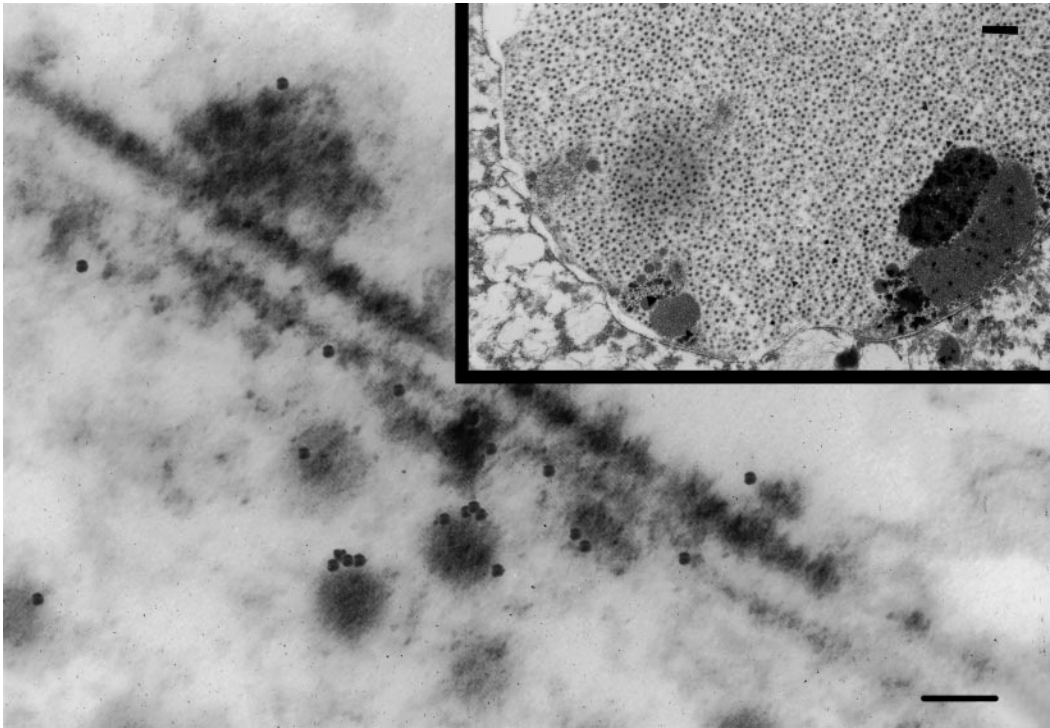


FIGURE 3. Immunoelectronmicroscopy positive reaction in liver of a Crimson's seedcracker with viruses labeled by gold particles. Bar = 50 nm. Insert: Intranuclear inclusion containing a great number of 42- to 49-nm viral particles. Bar = 500 nm.

vious reports of APV-induced disease in free-ranging seedcrackers; our work represents the first report of APV infection in wild-born Crimson's seedcrackers, with acute death upon arrival from their native area. This finding may mean that the birds were infected with APV before leaving Gambia, and the stress brought on by their capture and the changes in food and climate might have exacerbated a subclinical viral infection. There are several reports that stress or concomitant diseases in subclinically infected birds result in virus shedding and outbreaks of disease (Bernier et al., 1981; Gaskin, 1989; Phalen et al., 1993). In addition, immunodeficiency might be responsible for the occasional APV-induced death in chronically infected adult psittacines or the frequent deaths that occur in some newly hatched birds (Ritchie et al., 1995).

LITERATURE CITED

- BERNIER, G., M. MORIN, AND G. MARSOLAIS. 1981. A generalized inclusion body disease in the budgerigar (*Melopsittacus undulatus*) caused by a papovavirus-like agent. *Avian Diseases* 25: 1083-1092.
- CLEMENT, P. 1993. Finches and sparrows. C. A. Helm, and C. Black (eds). London, UK, pp. 147-148.
- FORSHAW, D., S. L. WYLIE, AND D. A. PASS. 1988. Infection with a virus resembling papovavirus in gouldian finches (*Erythrura gouldiae*). *Australian Veterinary Journal* 65: 26-28.
- GARCIA, A. P., K. S. LATIMER, F. D. NIAGRO, T. M. NORTON, B. G. HARMON, R. P. CAMPAGNOLI, AND W. L. STEFFENS. 1993. Avian polyomavirus infection in three black-bellied seedcrackers (*Pyrenestes ostrinus*). *Journal of the Association of Avian Veterinarians* 7: 79-82.
- _____, _____, _____, _____, R. P. CAMPAGNOLI, B. G. HARMON, E. W. HOWERTH, AND B. W. RITCHIE. 1994. Diagnosis of polyomavirus infection in seedcrackers (*Pyrenestes* sp.) and blue bills (*Spermophaga haematina*) using DNA in situ hybridization. *Avian Pathology* 23: 525-537.

- GASKIN, J. M. 1989. Psittacine viral diseases. A perspective. *Journal of Zoo and Wildlife Medicine* 20: 249–264.
- KHAN, M. S., R. JHONE, I. BECK, M. PAWLITA, E. F. KALETA, AND H. MULLER. 2000. Development of a blocking enzyme-linked immunosorbent assay for the detection of avian polyomavirus-specific antibodies. *Journal of Virological Methods* 89: 39–48.
- MARSHALL, R. 1989. Papova-like virus in a finch aviary. *In* Proceeding of the annual conference of the Association of Avian Veterinarians, Seattle, Washington, pp. 203–207.
- MCMANUS, J. F. A., AND R. W. MOWRY. 1960. Staining methods, histologic and histochemical. P. B. Hoeber (ed.), Harper & Brothers, New York, New York, pp. 275–276.
- PEARSE, A. G. E. 1985. Histochemistry, theoretical and applied. Vol. 2. *In* Analytical technology, 4th Edition. Churchill Livingstone Inc., Edinburgh, UK, pp. 735–832.
- PHALEN, D. N., V. G. H. WILSON, AND D. L. GRAHAM. 1993. Avian polyomavirus biology and its clinical applications. *In* Proceedings of the European Association of Avian Veterinarians. Utrecht, The Netherlands, pp. 200–216.
- RITCHIE, B. W., AND K. CARTER. 1995. Avian viruses: Function and control. Wingers Publishing Inc., Lake Worth, Florida, pp. 136–167.
- ROSSI, G., R. CECCHERELLI, A. PIERSIGILLI, AND C. TARANTINO. 2003. Sertoli cell tumor associated with polyomavirus infection in a Gouldian finch (*Erythrura gouldiae*). *Avian Diseases* 47: 240–243.
- SIRONI, G., AND T. RAMPIN. 1987. Papovavirus-like splenohepatic infection in greenfinches (*Carduelis chloris*). *Clinica Veterinaria* 110: 79–82.
- WOODS, L. 1989. Papova-like virus in a painted finch. *In* Proceedings of the Association of Avian Veterinarians, annual conference, Seattle, Washington, pp. 218–219.

Received for publication 21 November 2003.