



Metastrongyloid Nematode (*Otostrongylus circumlitus*) Infection in a Stranded California Sea Lion (*Zalophus californianus*)— a New Host-parasite Association

Authors: Kelly, Terra R., Greig, Denise, Colegrove, Kathleen M., Lowenstine, Linda J., Dailey, Murray, et al.

Source: Journal of Wildlife Diseases, 41(3) : 593-598

Published By: Wildlife Disease Association

URL: <https://doi.org/10.7589/0090-3558-41.3.593>

BioOne Complete (complete.BioOne.org) is a full-text database of 200 subscribed and open-access titles in the biological, ecological, and environmental sciences published by nonprofit societies, associations, museums, institutions, and presses.

Your use of this PDF, the BioOne Complete website, and all posted and associated content indicates your acceptance of BioOne's Terms of Use, available at www.bioone.org/terms-of-use.

Usage of BioOne Complete content is strictly limited to personal, educational, and non - commercial use. Commercial inquiries or rights and permissions requests should be directed to the individual publisher as copyright holder.

BioOne sees sustainable scholarly publishing as an inherently collaborative enterprise connecting authors, nonprofit publishers, academic institutions, research libraries, and research funders in the common goal of maximizing access to critical research.

Metastrongyloid Nematode (*Otostrongylus circumlitus*) Infection in a Stranded California Sea Lion (*Zalophus californianus*)—a New Host-parasite Association

Terra R. Kelly,^{1,4} Denise Greig,² Kathleen M. Colegrove,³ Linda J. Lowenstine,³ Murray Dailey,² Frances M. Gulland,² and Martin Haulena^{2,1} Environmental Medicine Consortium and Department of Clinical Sciences, North Carolina State University, 4700 Hillsborough Street, Raleigh, North Carolina 27606, USA; ² The Marine Mammal Center, Marin Headlands, Sausalito, California 94965, USA; ³ Department of Pathology, Microbiology, and Immunology, School of Veterinary Medicine, University of California, Davis, California 95616, USA; and ⁴ Corresponding author: (email: terra.kelly@hotmail.com).

ABSTRACT: A stranded yearling male California sea lion was admitted to a rehabilitation center June 2003. On presentation, the sea lion was emaciated and had diarrhea and neutrophilia. Two weeks later, the animal became anorexic, blood and mucus were observed around the oral cavity, and corneal opacity was noted in the right eye. Hematology results at that time included leukocytosis consisting of neutrophilia with a left shift, anemia, and thrombocytopenia. Despite supportive care, the sea lion died. On post mortem examination, there were multiple areas of hemorrhage scattered throughout all lung lobes, and pulmonary blood vessels were occluded by fibrin thrombi. Nematodes identified as immature forms of *Otostrongylus circumlitus* were found in the right ventricle and pulmonary arteries. Histologic findings in the lungs included severe suppurative and necrotizing arteritis with vascular thrombosis, interstitial pneumonia, and large areas of pulmonary hemorrhage. This report of *O. circumlitus* infection in a California sea lion (*Zalophus californianus*) might indicate a potentially new host-parasite association.

Key words: Arteritis, California sea lion, nematode, *Otostrongylus circumlitus*, *Zalophus californianus*.

The circumpolar metastrongyloid nematode *Otostrongylus circumlitus* is primarily a parasite of seals less than one year old (Onderka, 1989). It has an indirect life cycle that includes a variety of fish species shown experimentally to allow development of first stage larvae, but only American plaice (*Hippoglossoides platessoides*) experimentally supports development of infective larvae (Bergeron et al., 1997). The nematode has been reported in harbor (*Phoca vitulina*), and ringed (*Phoca hispida*) seals (Geraci, 1978; Onderka, 1989), and is less frequently observed in gray (*Halichoerus grypus*), harp (*Pagophi-*

lus groenlandicus), and hooded (*Cystophora cristata*) seals (Delyamure, 1968; Anderson et al., 1974; Lucas et al., 2003). More recently, *O. circumlitus* has been reported to be an important parasite of juvenile northern elephant seals (*Mirounga angustirostris*) and Pacific harbor seals (*Phoca vitulina richardsi*) along the central California coast (Gulland et al., 1997). Both of these species are sympatric with the California sea lion (*Zalophus californianus*) throughout its California range.

This case report describes *O. circumlitus* infection in a California sea lion. To the authors' knowledge, there have been no published reports of *O. circumlitus* infection in otariids, and this is the first observed case of this parasite in an otariid at The Marine Mammal Center (TMMC, Sausalito, California, USA). TMMC has been rehabilitating and investigating mortality of pinnipeds for 25 years and to date has examined approximately 6,000 California sea lions post mortem.

A yearling male California sea lion was admitted to TMMC after stranding along the central California coast 4 June 2003. On physical examination, the California sea lion was emaciated, had diarrhea, and weighed 20.4 kg. Hematology results on admission included leukocytosis (29,300/ μ l), neutrophilia (24,612/ μ l), and monocytosis (2,930/ μ l). No eosinophils were observed in the blood smear. Hematocrit was at the low end of normal at 34%, indicating anemia in a dehydrated individual. Reference ranges for these values in stranded weanling California sea lions are

9,780–22,800/ μl for leukocytes, 5,140–16,680/ μl for neutrophils, 0–1,600/ μl for monocytes, and 34–50% for hematocrit (Bossart et al., 2001). Abnormalities on serum biochemistry analysis were mild hyperglycemia (159.7 mg/dl), mild hyperproteinemia (12.0 g/dl), hyperalbuminemia (>6.0 g/dl), hyperbilirubinemia (11.0 mg/dl), and a decreased blood urea nitrogen (6.9 mg/dl). Reference ranges for these values in stranded weanling California sea lions range from 62–135 mg/dl for glucose, 7.7–10.7 g/dl for total protein, 2.9–4.0 g/dl for albumin, 0.1–1.1 mg/dl for bilirubin, and 20–88 mg/dl for blood urea nitrogen (Bossart et al., 2001). The elevation in total protein and albumin, and decrease in blood urea nitrogen concentration are most likely the result of dehydration and malnutrition, respectively. The causes of the low hematocrit and hyperbilirubinemia in this sea lion are unknown, but might be internal hemorrhage and/or hemolysis. Malnutrition might also have been a contributing factor in the etiology of the anemia of this individual.

The sea lion was initially treated with sucralfate (Carafate[®], Aventis Pharmaceuticals, Bridgewater, New Jersey, USA) at 25 mg/kg orally three times daily for three days, Vitamin B (Phoenix Pharmaceutical Inc., St. Joseph, Missouri, USA) at 7.5 mg/kg intramuscularly, and supportive care which included tube feeding. Anthelmintics were not administered to this animal. Use of anthelmintics at TMMC is reserved for those animals in which a parasite might be causing primary disease, contributing to another condition, or limiting the success of recovery of the individual. The sea lion was housed outside with other California sea lions, and was fed thawed herring and sardines that had been stored at -20 C once he began eating on his own two days after admission. A corneal opacity was observed in the right eye 13 days after admission. Enrofloxacin (Baytril[®], Bayer Corporation, Shawnee Mission, Kansas, USA) at 5 mg/kg orally once daily and carprofen (Rimadyl[®], Pfizer Inc., New York,

New York, USA) at 1.25 mg/kg orally once daily were initiated to treat keratitis in the right eye.

The following day (two weeks after admission), the sea lion became anorexic and blood was observed around his mouth and vibrissae, most likely due to hemoptysis. Hematology results included leukocytosis (26,300/ μl) consisting of neutrophilia (23,670/ μl) with left shift (1,315 bands/ μl), lymphopenia (263/ μl), anemia (29% hematocrit), and thrombocytopenia (67,000/ mm^3). The reference ranges for these values are 1180–8380/ μl for lymphocytes, 34–50% for hematocrit, and 208,000–720,000/ mm^3 for platelets (Bossart et al., 2001). Serum biochemistry was not performed at this time. Hematology findings are consistent with an inflammatory leukogram, most likely the result of an infectious process. The cause of the thrombocytopenia is unknown, but might be due to vasculitis and/or disseminated intravascular coagulation (DIC).

The sea lion died the following morning, despite supportive care. On postmortem examination, multiple areas of hemorrhage were scattered throughout all lung lobes, and on cut surface, blood vessels contained fibrin thrombi. There was moderate, diffuse interstitial edema throughout all lung lobes. Aerobic culture of the lung yielded a pure growth of *Escherichia coli*. The hilar lymph node was enlarged and contained multiple areas of hemorrhage on cut surface. There was a large amount of blood-tinged mucus within the trachea and bronchi. Two nematodes were found in the right ventricle of the heart and approximately 150 nematodes were observed in the right and left pulmonary arteries (Fig. 1). Other findings included nasopharyngeal acariasis (mites identified as *Orthohalarachne attenuata*). No parasitic protozoan cysts/trophozoites or helminth eggs/larvae were detected in a fecal sample obtained at necropsy using standard fecal flotation and Baermann sedimentation.

Tissue samples from multiple organs were fixed in 10% neutral buffered for-

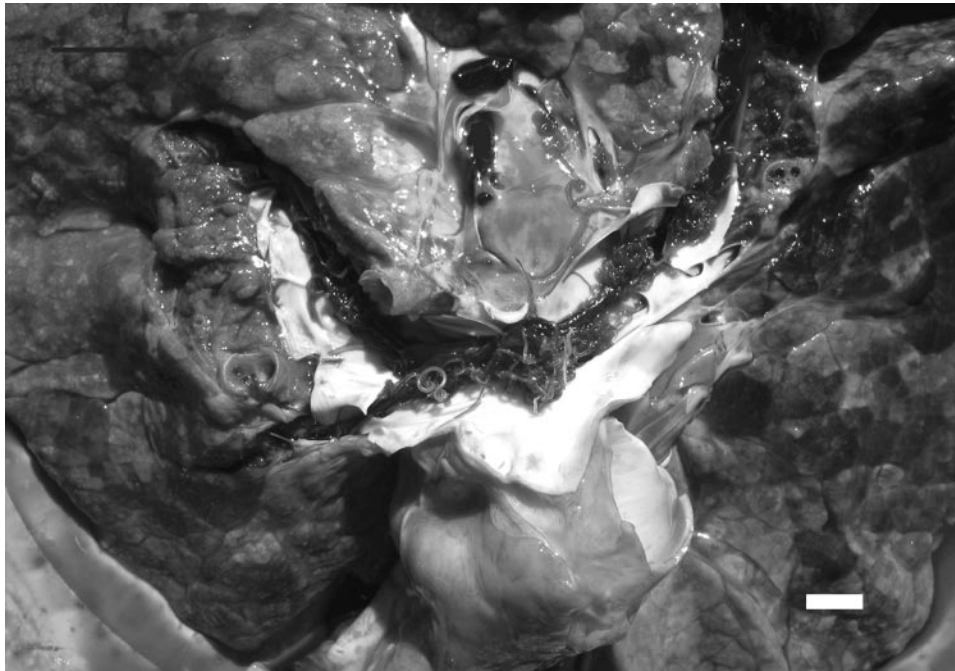


FIGURE 1. The dorsal surface of the lungs of a California seal lion infected with *Otostrongylus circumlitus*. Note the numerous nematodes in the lumen of the pulmonary artery. Bar = 2.0 cm.

malin, routinely processed for paraffin embedding, sectioned at 5 μm , and stained with hematoxylin and eosin (Luna, 1968). Histologic findings in the lungs included severe suppurative and necrotizing arteritis with vascular thrombosis, interstitial pneumonia, and large areas of pulmonary

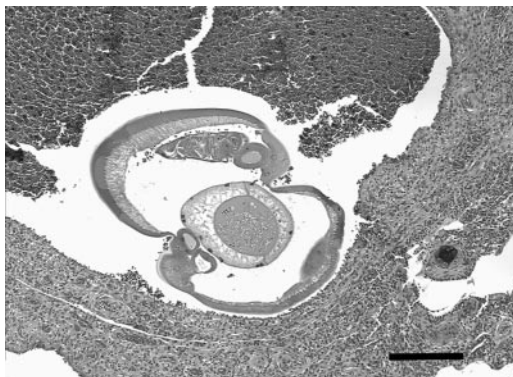


FIGURE 2. Photomicrograph of section of lung from a California sea lion infected with *Otostrongylus circumlitus*. Note the severe arteritis and cross section of an *O. circumlitus* within the lumen of the artery. H&E stain. Bar = 50 μm .

hemorrhage. Cross sections of metastrongyloid nematodes were found within the lumina of some affected arteries (Fig. 2). Numerous pulmonary vessels were occluded by fibrin thrombi (Fig. 3). In addition, multiple small metastrongyloid nema-

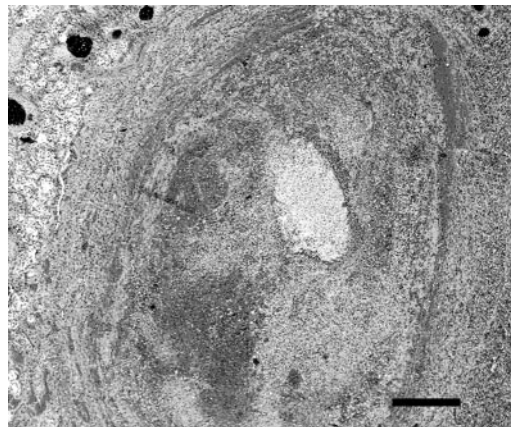


FIGURE 3. Photomicrograph of a pulmonary artery with severe arteritis in a California sea lion with *O. circumlitus*. Note the large fibrin thrombus occluding the lumen of the blood vessel. H&E stain. Bar = 100 μm .

todes, morphologically consistent with *Parafilaroides decorus* (see Gosselin and Measures, 1997) were present within alveolar spaces. A large thrombus was noted in a branch of the hepatic portal vein.

Large intranuclear inclusions suggestive of adenoviral infection were observed in the pulmonary vascular endothelium and capillary endothelium of the tracheobronchial lymph node. Other findings were consistent with debilitation and included moderate hemorrhagic colitis, mild chronic gastroenteritis, and mild pyelitis.

Ten female and male nematodes collected from the pulmonary arteries at necropsy were identified as immature forms of *O. circumlitus* using morphologic characteristics (Delyamure, 1968). Male nematodes were 30.5–34.5 mm long by 442.5 μm wide at midbody, and the buccal capsule was 42.5 μm wide by 20 μm long. The nerve ring was 312.5 μm from the cephalic extremity and the excretory pore was 137.5 μm posterior to the nerve ring. The esophagus of the male was 810 μm long by 95 μm at the widest section. The bursa was well developed, with nine rays (two fused ventroventral and lateroventral, two extenrolateral, two fused mediolateral and posterolateral, two externodorsal, and a single dorsal composed of a fusion of two rays). The spicules were equal in length, measuring 332.5 μm long by 40 μm wide at maximum width, and were brown and spongy, with two flanges, and finger-shaped distal ends. The gubernaculum measured 60 μm long by 22.5 μm wide, with a color and texture similar to those of the spicules (Fig. 4). Granular material resembling sperm was observed in the testis. Females were 47.5–50.0 mm long by 545 μm wide at midbody, and the buccal capsule was 65 μm wide by 35 μm long. The nerve ring was 315 μm from the cephalic extremity and the excretory pore was 225 μm posterior to the nerve ring. The vulva was near midbody and eggs in utero were 80 μm long by 52 μm wide. No larvae were observed in utero and no sign of mitotic development in the eggs was ob-

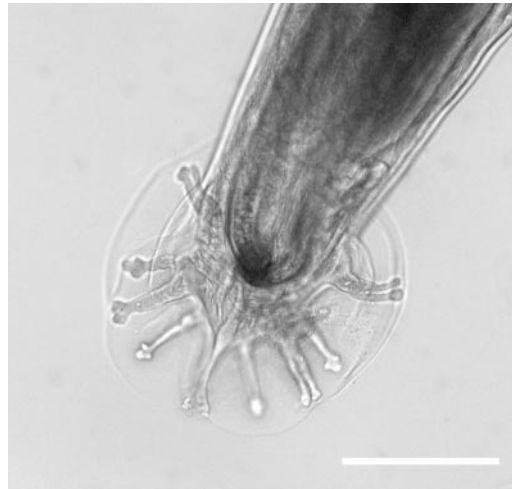

FIGURE 4. Ventral view of *O. circumlitus* male bursa. Bar = 2.5 cm.

served. Female and male voucher specimens were deposited in the U.S. National Parasite Collection, Beltsville, Maryland (accession number: USNPC# 95337).

The location of the *O. circumlitus* in this sea lion and the lesions associated with infection are similar to those observed in recently weaned northern elephant seals dying from *O. circumlitus* infection (Gulland et al., 1997). In stranded northern elephant seals less than one year old, *O. circumlitus* are most often found in the right heart and pulmonary artery, and lesions associated with infection include severe arteritis, interstitial pneumonia, and pulmonary vascular thrombosis. Northern elephant seals with *O. circumlitus* can develop DIC resulting in hemorrhage and death during the prepatent period (Gulland et al., 1997). Thrombosis of pulmonary arteries in this sea lion might have been due to damage to the vascular endothelium by severe inflammation. The thrombus in the hepatic portal vein could indicate DIC in this individual.

In contrast to northern elephant seals and California sea lions, adult nematodes in most phocids are typically found in the bronchi and bronchioles resulting in bronchitis, bronchopneumonia, and obstructive bronchiolitis (Onderka, 1989; Measures,

2001). Lesions associated with infection in most phocids other than elephant seals vary with the severity of infection and host susceptibility, and are often more severe in young or immunocompromised individuals (Measures, 2001). This California sea lion might have been predisposed to *O. circumlittus* infection due to some diminished immune competence. Stress, poor nutritional status, concurrent disease (adenovirus infection), and young age could all have been contributing factors to an immunocompromised state in this individual.

Verminous pneumonia due to *Parafilaroides decorus* is very common in stranded juvenile California sea lions (Sweeney and Gilmartin, 1974; Gerber et al., 1993) and asymptomatic infection is common in healthy young pinnipeds. However, heavy infection in a debilitated animal can result in severe morbidity and mortality (Gulland et al., 2001). Bacterial pneumonia with gram negative organisms is also commonly observed in sea lions, both as primary infections and secondary to viral and lungworm infections (Sweeney, 1986; Thornton et al., 1998). The *Escherichia coli* cultured from the lung of this animal is most likely due to secondary infection. *E. coli* is also frequently isolated from northern elephant seals infected with *O. circumlittus* (Gulland et al., 1997).

The association between adenoviral and *O. circumlittus* infection in this California sea lion is uncertain. Poor nutritional condition might have resulted in increased susceptibility to both parasitic disease and viral infection. Alternatively, viral recrudescence might have occurred secondary to severe parasitic disease. There are two reports of adenovirus infection in California sea lions, documenting six affected animals. All six sea lions had acute necrotizing hepatitis associated with adenoviral nuclear inclusions (Britt et al., 1979; Dierauf et al., 1981). Inclusions were not found in the liver of this sea lion.

The location and severe reaction to immature *O. circumlittus* by northern elephant seals during the prepatent period is

thought to be due to host reaction to the parasite in early migration (Gulland et al., 1997). Therefore, it has been suggested that the northern elephant seal and *O. circumlittus* are a recent host-parasite association. This is in contrast to the relationship between *O. circumlittus* and other phocids, in which there is minimal host reaction to immature stages, suggesting long term co-evolution of host and parasite (Gulland et al., 1997). The location of nematodes and severity of lesions during the prepatent period of this California sea lion are also likely the result of an aberrant host reaction due to a recent host-parasite association similar to that seen in northern elephant seals.

The highest number of elephant seals dying with *O. circumlittus* infection per year over the last ten years was observed in 2003 (34/56; 61% prevalence) the year of this sea lion's infection (TMMC, unpubl. data). The reason for this increase in prevalence is unknown, but likely reflects changes in prey availability or choice by host seals. Factors accounting for the high prevalence in northern elephant seals might also account for the infection seen in this individual sea lion. Further studies are needed to investigate the prevalence of this parasite in the California sea lion and to determine its role as a pathogen in this species.

The authors thank the staff and volunteers of The Marine Mammal Center, Michael K. Stoskopf DVM, PhD for editorial advice, and the North Carolina Zoological Society for its support.

LITERATURE CITED

- ANDERSON, S., W. N. BONNER, J. BAKER, AND R. RICHARDS. 1974. Grey seals, *Halichoerus grypus* of the Dee Estuary and observations on characteristic skin lesions in British seals. *Journal of Zoology* 174: 429–440.
- BERGERON, E., L. M. MEASURES, AND J. HUOT. 1997. Experimental transmission of *Otostrongylus circumlittus* (Raillet, 1899) (Metastrongyloidea: Crenosomatidae) a lungworm of seals in eastern arctic Canada. *Canadian Journal of Zoology* 75: 1364–1371.
- BOSSART, G. D., T. H. REIDARSON, L. A. DIERAUF,

- AND D. A. DUFFIELD. 2001. Clinical Pathology. *In* CRC Handbook of marine mammal medicine, L. A. Dierauf and F. M. D. Gulland (eds.). CRC Press, Boca Raton, Florida, pp. 383–430.
- BRITT, J. O., A. Z. NAGY, AND E. B. HOWARD. 1979. Acute viral hepatitis in California sea lions. *Journal of the American Veterinary Medical Association* 175: 921–923.
- DELYAMURE, S. 1968. Helminthofauna of marine mammals (ecology and phylogeny). Academy of Sciences of the USSR Laboratory of Helminthology. Israel program for scientific translations, U.S. Department of the Interior and the National Science Foundation, Washington, D.C. IPST Cat. 1886 TT 67-51202, 522 pp.
- DIERAUF, L. A., L. J. LOWENSTINE, AND C. JEROME. 1981. Viral hepatitis (adenovirus) in a California sea lion. *Journal of the American Veterinary Medical Association* 179: 1194–1197.
- GERACU, J. 1978. The enigma of marine mammal strandings. *Oceanus* 21: 38–47.
- GERBER, J. A., J. ROLETT, L. E. MORGAN, D. M. SMITH, AND L. GAGE. 1993. Findings in pinnipeds stranded along the central and northern California coast, 1984–1990. *Journal of Wildlife Diseases* 29: 423–433.
- GOSSELIN, J. F., AND L. N. MEASURES. 1997. Redescription of *Filaroides (Parafilaroides) gymnuris* (Railliet, 1899) (Nematoda: Metastrongyloidea), with comments on other species in pinnipeds. *Canadian Journal of Zoology* 75: 359–370.
- GULLAND, F. M. D., K. BECKMEN, K. BUREK, L. LOWENSTINE, L. WERNER, T. SPRAKER, M. DAILY, AND E. HARRIS. 1997. Nematode (*Ostrostrongylus circumlitus*) infestation of northern elephant seals stranded along the central California coast. *Marine Mammal Science* 13: 446–459.
- , M. HAULENA, AND L. A. DIERAUF. 2001. Seals and sea lions. *In* CRC Handbook of marine mammal medicine, L. A. Dierauf and F. M. D. Gulland (eds.). CRC Press, Boca Raton, Florida, pp. 907–926.
- LUCAS, Z., P-Y. DAOUST, G. CONBOY, AND M. BRIMACOMBE. 2003. Health status of harp seals (*Phoca groenlandica*) and hooded seals (*Cystophora cristata*) on Sable Island, Nova Scotia, Canada, concurrent with their expanding range. *Journal of Wildlife Diseases* 39: 16–28.
- LUNA, L. G. 1968. Manual of histologic staining methods of the Armed Forces Institute of Pathology. 3rd Edition. McGraw Hill Company, New York, New York, 258 pp.
- MEASURES, L. N. 2001. Lungworms of marine mammals. *In* Parasitic diseases of wild mammals, W. M. Samuel, A. A. Kocan, and M. J. Pybus (eds.). 2nd Edition. Iowa State University Press, Ames, Iowa, pp. 279–300.
- ONDERKA, D. K. 1989. Prevalence and pathology of nematode infections in the lungs of ringed seals (*Phoca hispida*) of the western arctic of Canada. *Journal of Wildlife Diseases* 25: 218–224.
- SWEENEY, J. 1986. Infectious diseases. *In* Zoo and Wildlife Medicine. M. E. Fowler (ed.). 2nd edition. W. B. Saunders, Philadelphia, Pennsylvania, pp. 777–781.
- , AND W. G. GILMARTIN. 1974. Survey of diseases in free-living California sea lions. *Journal of Wildlife Diseases* 10: 370–376.
- THORNTON, S. M., S. NOLAN, AND F. M. D. GULLAND. 1998. Bacterial isolates from California sea lions (*Zalophus californianus*), harbor seals (*Phoca vitulina*), and northern elephant seals (*Mirounga angustirostris*) admitted to a rehabilitation center along the central California coast, 1994–1995. *Journal of Zoo and Wildlife Medicine* 29: 171–176.

Received for publication 13 May 2004.