



Presumptive Gangrenous Ergotism in Free-Living Moose and a Roe Deer

Authors: Handeland, Kjell, and Vikøren, Turid

Source: Journal of Wildlife Diseases, 41(3) : 636-642

Published By: Wildlife Disease Association

URL: <https://doi.org/10.7589/0090-3558-41.3.636>

BioOne Complete (complete.BioOne.org) is a full-text database of 200 subscribed and open-access titles in the biological, ecological, and environmental sciences published by nonprofit societies, associations, museums, institutions, and presses.

Your use of this PDF, the BioOne Complete website, and all posted and associated content indicates your acceptance of BioOne's Terms of Use, available at www.bioone.org/terms-of-use.

Usage of BioOne Complete content is strictly limited to personal, educational, and non - commercial use. Commercial inquiries or rights and permissions requests should be directed to the individual publisher as copyright holder.

BioOne sees sustainable scholarly publishing as an inherently collaborative enterprise connecting authors, nonprofit publishers, academic institutions, research libraries, and research funders in the common goal of maximizing access to critical research.

Presumptive Gangrenous Ergotism in Free-Living Moose and a Roe Deer

Kjell Handeland^{1,2} and Turid Vikøren¹ ¹ Department of Animal Health, Section of Wildlife Diseases, National Veterinary Institute, PO Box 8156 Dep, NO-0033 Oslo, Norway; ² Corresponding author (email: kjell.handeland@vetinst.no)

ABSTRACT: Presumptive gangrenous ergotism in 10 moose (*Alces alces*) and one roe deer (*Capreolus capreolus*) is reported. Three of the moose came from a municipality in southeastern Norway where the disease occurred as a cluster in 1996. The other moose represented solitary or sporadic cases diagnosed in four municipalities in northwestern Norway between 1996 and 2004. Affected moose (seven calves, three yearlings) were found between October and June, showing distal limb lesions on one to three limbs. The lesions in the moose found during October and November presented as dry gangrene, whereas moose found between December and June presented with loss of the distal part of the limbs or open lesions close to sloughing. Four of the moose also had bilateral ear lesions affecting the outer third of the pinnae. A retrospective diagnosis of ergotism (June 1981) was made in a 1-yr-old roe deer from northwestern Norway showing loss of the distal part of all four limbs.

Key words: *Alces alces*, *Capreolus capreolus*, cervids, *Claviceps purpurea*, ergotism, gangrene, mycotoxin.

The parasitic fungus *Claviceps purpurea* produces ergots (sclerotia) in the seed heads of grasses and cereals. The ergots contain a number of alkaloids and amines that are pharmacologically active. Ingestion may result in several syndromes including gangrene, hyperthermia, and reproductive disturbances (Humphreys, 1988; Radostits et al., 2000). Toxicopathology caused by ergot alkaloids is due to vasoactive compounds that stimulate smooth muscles in the arterioles, intestines, and uterus. With chronic intoxication, arterial spasm occurs, with subsequent damage to the capillary endothelium, leading to thrombosis and ischemic necrosis (gangrene). Gangrenous ergotism is the classical manifestation of ergot intoxication that has been known to occur in domestic animals and man in many parts of the world for centuries. The gangrene

typically affects the distal part of limbs, ears, and tail. In wildlife, reports of ergotism seem to be restricted to a single case of gangrenous ergotism in a roe deer (*Capreolus capreolus*) from England (Green and Rose, 1995). The present paper reports 10 cases of presumed gangrenous ergotism in free-living moose (*Alces alces*) in Norway during the period 1996–2004, as well as one retrospectively diagnosed case in a roe deer.

The 10 moose originated from a coastal municipality in southeastern Norway (Holmestrand, 59°28'N, 10°09'E) and from four coastal and neighboring municipalities (Halsa, 63°04'N, 08°15'E; Hemne, 63°17'N, 09°04'E; Molde, 62°40'N, 07°04'E; Surnadal, 62°47'N, 08°52'E) in northwestern Norway (Table 1). Two of the moose were found dead, whereas the remainder were destroyed on humane grounds because of their severe locomotory disturbances. Three moose were found during hunting in October, and seven between November and June. The three cases from Holmestrand appeared as a cluster in October/November 1996. Two additional cases (not included) with similar lesions were reported killed in Holmestrand later in the same year (Moen, pers. comm.). The remaining seven moose occurred either as solitary cases during a single year (Halsa, Molde, Surnadal) or as sporadic cases over several years (Hemne). In Hemne, undocumented cases back to the 1980s have been reported (Lian, pers. comm.).

Materials submitted for pathologic examination from eight of the moose included the distal half of the limbs, and in four of these cases the ears as well. The remaining two moose were included in the

TABLE 1. Cases of gangrenous ergotism in free-living moose and roe deer in Norway.

No.	Municipality	Found dead or killed	Date	Species (Sex ^a)	Age ^b	Affected forelimbs	Affected hindlimbs	Affected ear tips
1	Halsa	Killed	Dec 03	Moose	Calf	—	2	2
2	Hemne	Killed	Jan 96	Moose (f)	Yearling	1	—	2
3	Hemne	Dead	Nov 03	Moose	Calf	—	2	—
4	Hemne	Dead	Jan 04	Moose	Calf	1	—	—
5	Hemne	Killed	Mar 04	Moose (f)	Calf	1	1	2
6	Holmestrand	Killed	Oct 96	Moose (f)	Yearling	1	2	—
7	Holmestrand	Killed	Oct 96	Moose	Calf	—	2	2
8	Holmestrand	Killed	Nov 96	Moose	Calf	—	1	—
9	Molde	Killed	Jun 02	Moose (f)	Calf	1	2	—
10	Sumadal	Killed	Oct 00	Moose (m)	Yearling	—	2	—
11	Tingvoll	Killed	Jun 81	Roe deer (m)	Calf	2	2	—

^a Sex: f = female; m = male.

^b Age: ≤1 y = calf; >1 y and < 2 y = yearling.

study on the basis of good-quality photographs, showing multiple, typical lesions. Materials were either submitted directly from the local wildlife authorities or via the local veterinarian, with histories giving information on age, body condition, and location of lesions. Sex was noted for five animals only (Table 1).

The roe deer was found in Tingvoll municipality (63°05'N, 08°03'E) in northwestern Norway in June 1981. In spite of having lost the distal part of all limbs, it could rise from a lying position and move with remarkable ease. However, it had trouble when it became frightened and retreated into a small bog, sinking deep into the soft terrain. The animal obviously had been living in a small area for a long time, leaving many tracks and markedly grazed vegetation as well as feces in the immediate vicinity. The roe deer was killed and the carcass stored frozen for 1 yr before being brought to the laboratory for postmortem examination.

Pathologic examination of the moose materials and roe deer carcass was carried out following standard procedures. From four of the moose fresh tissue adjacent to gangrenous tissues or sites of sloughing was fixed in 10% buffered formalin, embedded in paraffin, sectioned, and stained with hematoxylin and eosin for histologic examination. Samples taken from necrotic

tissue of five moose and from two fetlock joints were plated on calf blood agar plates for standard bacterial examination. The plates were incubated aerobically at 37 C and examined after 24–48 hr.

The 10 moose, seven calves, and three yearlings were in a poor or emaciated body condition. All moose had distal limb lesions, affecting one to three of the limbs (Table 1). Most commonly, the hind limbs were affected, usually bilaterally. Unilateral forelimb lesions occurred in half of the cases. The limb lesions extended from the distal phalanx up to the mid-metacarpus/metatarsus.

Limb lesions in the five moose found during October and November presented as dry gangrene (Fig. 1) and occasionally were infested by fly larvae. Hoofs and the horn of the accessory digits were frequently loose, but had not been shed. In two of these moose, one fetlock joint contained purulent exudate from which α -hemolytic *Streptococcus* sp. and *Staphylococcus aureus* were isolated. Bacteriologic examination of gangrenous soft tissues revealed no growth of bacteria, or the growth of an unidentified mixture of bacteria. In the five moose found between December and June, affected portions of the limbs had either fallen off (Fig. 2), or presented as open gangrenous lesions close to sloughing. The sites of separation were at the



FIGURE 1. Moose calf (no. 3) showing bilateral gangrene of the hind limbs extending up to the distal third of the metatarsus. There is discoloration and loss of hair in the necrotic skin, and separation of the skin between necrotic and viable areas. Rims of unshed brown calf haircoat are seen distal to the separation zone.

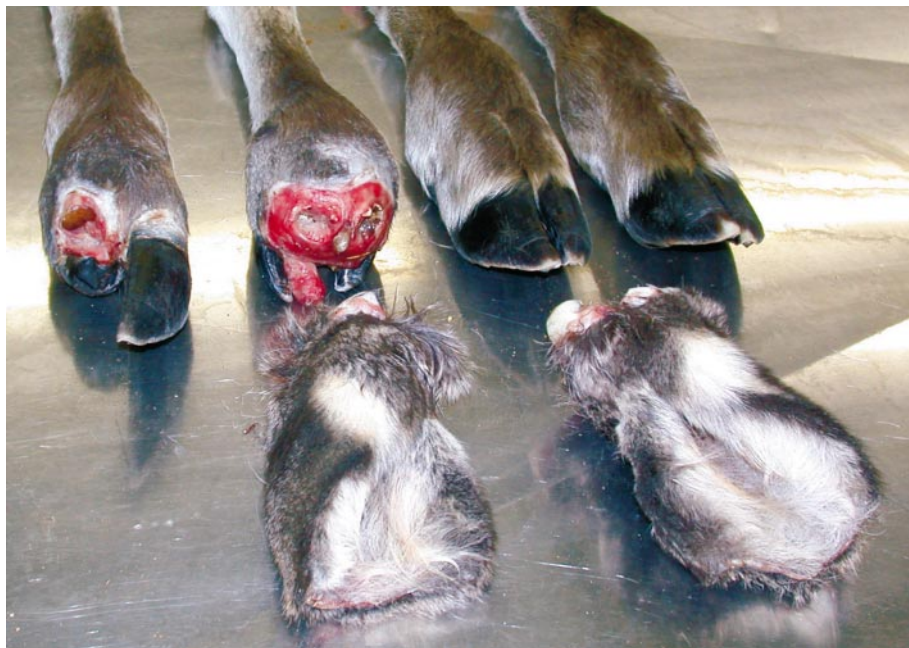

FIGURE 2. Moose calf (no. 1) showing unilateral (left) and bilateral loss of the distal and medial phalanx of the two hind limbs, as well as both ear tips. The forelimbs are normal. Swelling and exposure of the medullary cavity of the proximal phalanges are seen in the limb with bilateral lesions.

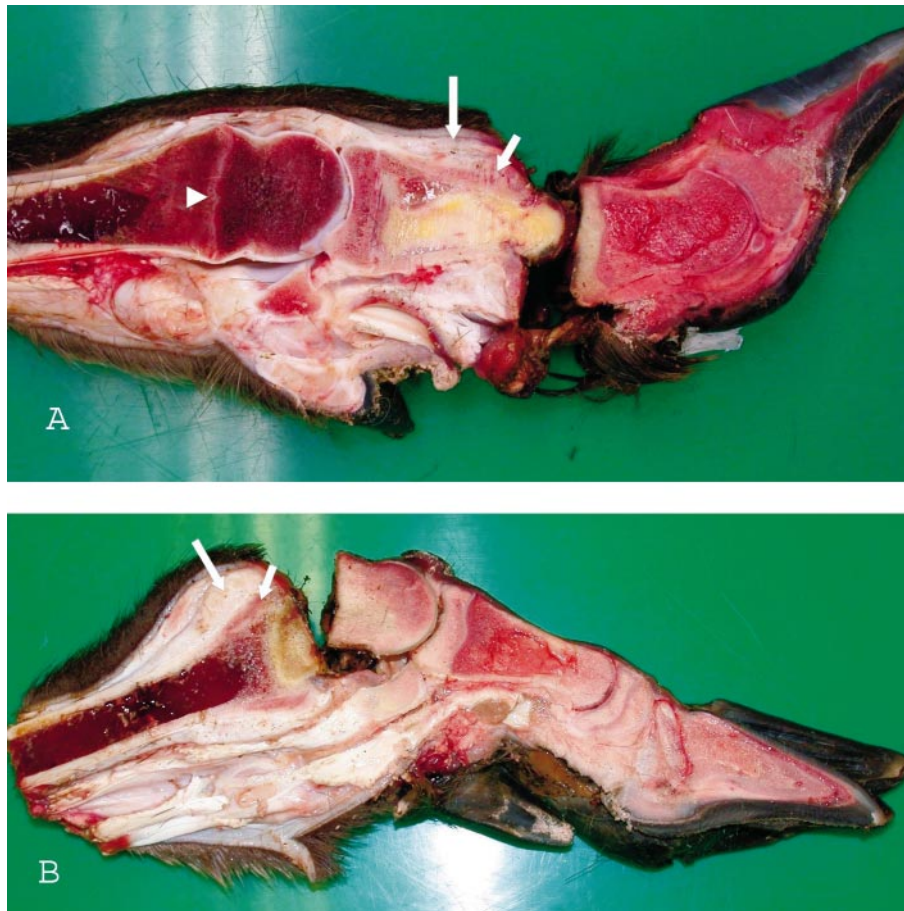


FIGURE 3. Sagittal cut through one hind limb (A) and one forelimb (B) of a moose calf (no. 5) showing gangrenous phalanges with partial sloughing through the proximal interphalangeal joint (A), and through the physis of the metacarpus (B). An intact physal line of the metatarsus (arrowhead) and yellow discoloration of necrotic bone tissue of the proximal phalanx are seen in A. There is loss of the skin on the necrotic digits. Subcutaneous granulation tissue (long arrow) and exostosis (short arrow) are visible proximal to the sites of separation.

digital joints (Fig. 3A), or through the physal lines adjacent to these joints (Fig. 3B). The exposed limb ends were enlarged because of the presence of subcutaneous granulation tissue and periosteal exostoses (Figs. 2, 3). There were variable degrees of epithelialization from the free edges of the skin, and signs of erosion and wear could be seen on the free bone ends (Fig. 2).

Four moose also had bilateral ear lesions, affecting the outer third of the pinna. The lesions in one moose presented as stiffened and demarcated necrotic ear tips.

In the remainder, the ear tips had fallen off (Fig. 2). The free edge of the wound was somewhat swollen, reflecting edema and an accumulation of inflammatory cells, and there was a variable degree of epithelialization of the wound surface.

The roe deer was a 1-yr-old buck in a poor, but not emaciated, body condition. The animal had lost all limbs distal to the fetlock (Fig. 4).

The moose and roe deer described here are believed to represent cases of gangrenous ergotism, and to be the first report of this condition in moose. This diagnosis

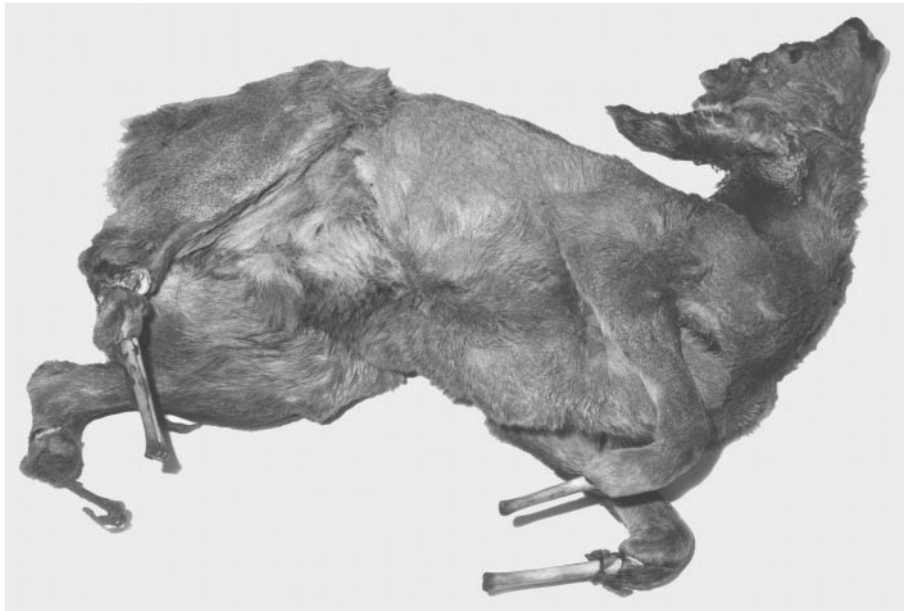

FIGURE 4. Roe deer (no. 11) showing loss of all digits and the naked metacarpal/metatarsal bone shafts with disintegrated skin and muscles advancing up to the proximal third (the left metatarsal bone had fractured during transportation and is not seen on this photograph). Wear, erosion, and discoloration are seen on the bone ends.

is difficult to confirm, especially in free-living animals that are not normally seen until lesions are in an advanced state, long after the toxic insult has ceased. The differential diagnoses would include conditions such as trauma, accidental ligation of the appendages, bacterial infections, and the effects of cold. In nine of the reported cases, there were multifocal lesions, indicating systemic vasoconstriction that was not consistent with trauma or ligation. There also were no indications of a primary bacterial infection. Both roe deer and especially moose are well adapted to the cold climate found in northern latitudes, making frostbite an unlikely cause. However, it should be kept in mind that low temperatures during late autumn and winter may have exacerbated the circulatory disturbances and the loss of extremities in these animals. Low environmental temperatures have been suspected to exacerbate clinical signs of gangrenous ergotism in domestic ruminants (Woods et al., 1966).

The ergot of *Claviceps purpurea* develops in the seed heads of grasses and cereals during autumn (Høiland and Nordal, 1983), and their presence as well as the quantity and spectrum of the alkaloids may vary considerably depending upon environmental conditions (Yager et al., 1993). Most of the moose as well as the roe deer reported here came from coastal municipalities in northwestern Norway with an oceanic climate and high humidity (Langvatn and Albon, 1986), which is favorable for development of the fungus. There is no grain production in this region and the intoxication presumably resulted from ingestion of ergot-infested wild grasses, which are a common finding in Norway (Høiland and Nordal, 1983). Intoxication during autumn corresponds well with temporal lesion profiles seen in the reported animals; the lesions being more advanced in the animals found during winter and spring compared to autumn. The reason why affected animals were limited to calves and yearlings could relate to the in-

duction of a detoxification mechanism in adult animals, following moderate exposure during earlier seasons. Such mechanisms seem to play a role in other intoxications in moose, for example in the plant intoxication caused by bog asphodel (*Narthesium ossifragum*) (Flåøyen et al., 1999; Vikøren et al., 1999).

The northwestern part of Norway has only small populations of moose (Sæther, 1990), but dense populations of red deer (*Cervus elaphus*) (Langvatn and Albon, 1986). Red deer seem to be susceptible to ergot intoxication under farmed conditions (Munro, 1994). The reason why moose seem to be more susceptible to intoxication than red deer under natural conditions is presumably related to differences in grazing pattern. Although being a browser, the moose is known to eat considerable amounts of wild grasses during the summer half of the year (Damli and Roer, 1995; Solli, 1995). The high cutting level of the moose and their preference for large-grown grasses, compared to red deer selecting low vegetation and young grass, suggests that moose are at greater risk of ingesting ergot-containing seed heads. The same explanation can be suggested for the low frequency of intoxication in domestic ruminants in Norway, in which records of gangrenous ergotism are restricted to a single case in sheep (Løken et al., 1979) and one small outbreak in cattle (Bratberg, pers. comm.). Domestic ruminants normally graze, or are fed, cultivated grasses that are harvested in an early stage of development and before seed heads are formed.

Whether other manifestations associated with ergotism in domestic ruminants, including hyperthermia, reproductive disturbances, diarrhea, ulcerations in the digestive tract (Radostits et al., 2000), central nervous system disturbances (Humphreys, 1988), and persistent lameness (Woods et al., 1966) may occur in wild ruminants remains unanswered. However, it should be mentioned that since the 1980s, a syndrome of unknown etiology charac-

terized by diarrhea, ulcerations of the digestive tract, and central nervous disturbances has been known to occur in the Scandinavian moose population (Broman et al., 2002). Moreover, during postmortem examinations in our laboratory, we have seen a few moose carcasses with areas of dead and parchmentlike skin on the trunk. This condition resembles a cutaneous manifestation of gangrenous ergotism that has been described in cattle (Coppock et al., 1989).

We thank the following persons who contributed to the submission of materials for the laboratory examination: J. A. Lian and J. Schulze (Hemne), J. H. Moen, A. Solberg, and M. Rønningen (Holmestrand), E. Snøfugl (Halsa), P. Krigsvoll and A. Ormset (Tingvoll), E. Meisingset and E. Kårvatn (Surnadal), and N. B. Venås (Molde). J. A. Lian is also thanked for providing the photograph shown in Figure 1, whereas L. Qviller is thanked for taking the remaining photographs shown in this paper.

LITERATURE CITED

- BROMAN, E., K. WALLIN, M. STEEN, AND G. CEDERLUND. A wasting syndrome in Swedish moose (*Alces alces*): Background and current hypothesis. *Ambio* 31: 409–416.
- COPPOCK, R. W., M. S. MOSTROM, J. SIMON, D. J. MCKENNA, B. JACOBSEN, AND H. L. SZLACHTA. 1989. Cutaneous ergotism in a herd of dairy calves. *Journal of the American Veterinary Medical Association* 194: 549–551.
- DAMLI, K. G. S., AND O. A. ROER. 1995. Summer browsing and choice of habitat of moose in Aust-Agder. MSc Thesis, Agricultural University of Norway, Ås, Norway, 55 pp. [In Norwegian]
- FLÅØYEN, A., K. HANDELAND, G. STUVE, K. A. RYENG, AND T. REFSUM. 1999. Experimental *Narthesium ossifragum* nephrotoxicity in cervids from Norway. *Journal of Wildlife Diseases* 35: 24–30.
- GREEN, P., AND H. ROSE. 1995. Suspected gangrenous ergotism in a wild roe deer (*Capreolus capreolus*). *Veterinary Record* 137: 220–221.
- HUMPHREYS, D. J. 1988. *Veterinary toxicology*, 3rd Edition. Baillière Tindall, London, UK, 356 pp.
- HØILAND, K., AND I. NORDAL. 1983. *Systematic botany with emphasis on medical plants*. Universitetsforlaget, Oslo, Norway, 274 pp. [In Norwegian]
- LANGVATN, R., AND S. D. ALBON. 1986. Geographic clines in body weight of Norwegian red deer: A

- novel explanation of Bergmann's rule?. *Holarctic Ecology* 9: 285–293.
- LØKEN, T., M. J. ULVUND, AND T. VÅG. 1979. A case of gangrenous ergotism in grazing sheep. *Acta Veterinaria Scandinavica* 20: 601–603.
- MUNRO, R. 1994. Mycotoxins. *In* Management and diseases of deer, 2nd Edition, T.L. Alexander and D. Buxton (eds.). Macdonald Lindsay Pindar, Loanhead, Midlothian, UK, pp. 197–198.
- RADOSTITS, O. M., C. C. GAY, D. C. BLOOD, AND K. W. HINCHCLIFF. 2000. *Veterinary medicine. A textbook of the diseases of cattle, sheep, pigs, goats and horses*, 9th Edition. W.B. Saunders Company, London, UK, 1877 pp.
- SOLLI, T. 1995. Summer browsing and choice of habitat of moose in Nord-Østerdal and Røros. MSc Thesis, Agricultural University of Norway, Ås, Norway, 48 pp. [In Norwegian]
- SÆTHER, B. E. 1990. The moose. *In* Wild mammals in Norway, Vol. 2, A. Semb-Johansson and R. Frislid (eds.). J. W. Cappelen Forlag as, Oslo, Norway, pp. 104–125. [In Norwegian]
- VIKØREN, T., K. HANDELAND, G. STUVE, AND B. BRATBERG. 1999. Toxic nephrosis in moose in Norway. *Journal of Wildlife Diseases* 35: 130–133.
- WOODS, A. J., J. BRADLEY JONES, AND P. G. MANTLE. 1966. An outbreak of gangrenous ergotism in cattle. *Veterinary Record* 78: 742–749.
- YAGER, J. A., D. W. SCOTT, AND B. P. WILCOCK. 1993. Gangrenous ergotism and fescue toxicosis. *In* Pathology of domestic animals, Vol. 1, 4th Edition, K. V. F. Jubb, P. C. Kennedy, and N. Palmer (eds.). Academica Press, San Diego, California, pp. 590–591.

Received for publication 19 June 2004