

PREVALENCE OF ANOMALIES IN THE APPENDICULAR SKELETON OF A FOSSORIAL RODENT POPULATION

Authors: Ventura, Jacint, and Götzens, Victor

Source: Journal of Wildlife Diseases, 41(4) : 728-734

Published By: Wildlife Disease Association

URL: <https://doi.org/10.7589/0090-3558-41.4.728>

BioOne Complete (complete.BioOne.org) is a full-text database of 200 subscribed and open-access titles in the biological, ecological, and environmental sciences published by nonprofit societies, associations, museums, institutions, and presses.

Your use of this PDF, the BioOne Complete website, and all posted and associated content indicates your acceptance of BioOne's Terms of Use, available at www.bioone.org/terms-of-use.

Usage of BioOne Complete content is strictly limited to personal, educational, and non - commercial use. Commercial inquiries or rights and permissions requests should be directed to the individual publisher as copyright holder.

BioOne sees sustainable scholarly publishing as an inherently collaborative enterprise connecting authors, nonprofit publishers, academic institutions, research libraries, and research funders in the common goal of maximizing access to critical research.

PREVALENCE OF ANOMALIES IN THE APPENDICULAR SKELETON OF A FOSSORIAL RODENT POPULATION

Jacint Ventura^{1,3} and Victor Götzens²

¹ Departament de Biologia Animal, Biologia Vegetal i Ecologia, Facultat de Ciències, Universitat Autònoma de Barcelona, 08193-Bellaterra, Barcelona, Spain

² Departament d'Anatomia i Embriologia humana, Facultat de Medicina, Universitat de Barcelona, Campus de Bellvitge, 08907-L'Hospitalet de Llobregat, Barcelona, Spain

³ Corresponding author (email: jacint.ventura.queija@uab.es)

ABSTRACT: The prevalence of macroscopic bone anomalies in the appendicular skeleton of wild rodents and, particularly, fossorial species is not well known. We examined 8,257 bones corresponding to 564 collection specimens (249 males and 315 females) of a fossorial form of water vole (*Arvicola terrestris monticola*). Animals were obtained monthly from July 1983 to December 1984 in the Aran Valley (Pyrenees). Most macroscopic anomalies were healed fractures or exostoses. The prevalence of anomalies was not significantly different between males and females but was clearly higher in adults than in juveniles and subadults. The frequency of alterations in the thoracic limb long bones was significantly higher than that in the pelvic counterparts. Aggressive intraspecific interactions and biomechanical factors related to burrowing may be associated with these differences. In females, remodeling of the innominate shape because of pregnancy and parturition could enhance fractures and exostoses in this structure.

Key words: Appendicular skeleton, *Arvicola terrestris monticola*, exostoses, fossorial water voles, fractures, ossifications, rodents, tumors.

INTRODUCTION

The frequency of macroscopic anomalies in the appendicular skeleton of free-living, wild rodent populations has been investigated poorly (Becker, 1966; Hamar, 1970; Arrizabalaga and Montagut, 1990), and for fossorial species in particular, information concerning this subject is lacking. Approximately 125 extant species of hypogeal rodents are known (Reig et al., 1990), and they constitute a unique group within mammals. The northern water vole (*Arvicola terrestris*) is a widespread Palearctic rodent that shows two ecologic forms (Kratochvíl, 1983): the fossorial, which occurs in the mountains of southwestern and central Europe, and the semi-aquatic, which extends over the rest of the distribution area of the species.

Although the morphology of girdles and limb long bones of fossorial water voles have been described in several studies (Laville, 1990; Ventura et al., 1991; Ventura, 1992), the kind and prevalence of morphologic alterations in these bones is unknown. These voles live in underground burrows formed by a complex system of galleries (Airoldi, 1991) with, as a result of

digging, earth tumulus on the ground surface. To construct the gallery network, these animals follow a strict pattern of stereotyped, cyclic events. The incisors are used to loosen the soil, and the limbs, the head, and again, the incisors are used to evacuate the soil and consolidate the gallery walls (Laville, 1989).

Fossorial *A. terrestris* can periodically reach high population densities in permanent grasslands of medium-height mountains and cause significant damage to agricultural lands (Saucy, 1994). During the breeding season, these rodents live mainly in family groups. They usually are monogamous, although under certain conditions, such as during high-density periods, males become polygynous. In general, adult males and females defend their own territories against other adults of their own sex (Saucy, 1988). This suggests that agonistic interactions should be common in water vole populations and particularly frequent during high-density situations.

Taking into account these ecologic and behavioral characteristics, it can be assumed that the appendicular skeleton of fossorial water voles is subjected to partic-

ularly strong mechanical stress. This can increase the prevalence of alterations to the normal bone morphology caused by other, more general factors, such as diseases, developmental abnormalities, or interactions with predators. With all this in mind, the main goal of the present study is to report the skeletal macroscopic anomalies found in girdles and limb long bones in a collection of a fossorial form of *A. terrestris* (*A. t. monticola*). Bones that were analyzed corresponded to a wide set of specimens collected monthly from a specific Pyrenean population over 1.5 yr. The bone anomalies observed and their corresponding frequencies were analyzed by age, sex, and the biologic, ethologic, and ecologic characteristics of fossorial water voles. To our knowledge, this study constitutes the first detailed analysis of the prevalence of morphologic anomalies in the appendicular skeleton of a free-living, wild rodent population and, particularly, a fossorial species.

MATERIALS AND METHODS

A total of 8,257 bones corresponding to 564 specimens of *A. t. monticola* (249 males and 315 females) were examined. This material belongs to the collection of the Department of Animal Biology of the Faculty of Biology of the University of Barcelona, Barcelona, Spain. Voles that were analyzed came from the grasslands near the localities of Arròs (42°44'N, 0°46'E) and Aubert (42°44'N, 0°47'E) in the Aran Valley (Pyrenees) and were obtained monthly from July 1983 to December 1984. During that period, fossorial voles reached high densities (not quantified) and caused considerable damage to the grasslands. Animals were grouped into six age classes according to the criteria established by Ventura and Gosálbez (1992). These age classes also have been used in other studies concerning this sample (Ventura and Gosálbez, 1990; Ventura et al., 1991). The age intervals estimated for each category were as follows: class 0, 3 wk maximum; class 1, 3–6 wk; class 2, 6–10 wk; class 3, 10–14 wk; class 4, animals older than 14 wk that either have not or have recently lived through their first winter; and class 5, specimens that have lived longer than one winter. Individuals of this population probably live no more than 2 yr (Ventura and Gosálbez, 1992) and reach sexual maturity in class 2 or 3 (Ventura and Gosálbez,

1990). The number of specimens assigned to each age group was as follows: class 0, $n = 9$ (four males and five females); class 1, $n = 31$ (14 males and 17 females); class 2, $n = 64$ (29 males and 35 females); class 3, $n = 101$ (59 males and 42 females); class 4, $n = 235$ (84 males and 151 females); and class 5, $n = 124$ (59 males and 65 females). For anatomic terms, nomenclature of the *Nomina Anatomica Veterinaria* (International Committee on Veterinary Anatomical Nomenclature, 1994) has been followed. The significance of differences between the percentage prevalences of bone anomalies was tested by means of contingency tables using SPSS 10.0 (Norusis, 1997).

RESULTS

Total percentages of anomalies in each bone were slightly higher in males except for the innominate and the tibia, which were higher in females. Nevertheless, in all cases, sexual differences were not statistically significant. Therefore, male and female bones were pooled for subsequent analysis. Alterations of normal bone morphology were detected in specimens of classes 3–5 except for consolidated fractures, which were detected in one innominate of a female from class 1 and in one femur of a male from class 2. Differences in the total percentages between all bones were significant ($\chi^2=40.402$, d.f.=7, $P<0.001$). In decreasing order, the total percentages of anomalies corresponded to the innominate, bones of the arm and thigh, bones of the forearm, scapula, and bones of the leg (Table 1).

In the thoracic appendicular skeleton, comparisons between pairs of bones revealed significantly different prevalences only in the case of the scapula-humerus ($\chi^2=6.478$, $P<0.02$). Conversely, in the pelvic skeleton, significant differences were found in many cases, probably because of the relatively low frequency of anomalies in the tibia and the fibula (innominate-tibia: $\chi^2=24.125$, $P<0.001$; innominate-fibula: $\chi^2=16.533$, $P<0.001$; femur-tibia: $\chi^2=16.755$, $P<0.001$; femur-fibula: $\chi^2=9.946$, $P<0.01$). Differences in the total percentages between morphologically equivalent bones of the thoracic and pelvic

TABLE 1. Number of anomalous bones with respect to the total number of bones examined in fossorial water voles according to relative age class.

| Bone | Age class | | | | | | Total % |
|------------|-----------|------|-------|-------|--------|--------|---------|
| | 0 | 1 | 2 | 3 | 4 | 5 | |
| Scapula | 0/16 | 0/58 | 0/123 | 1/196 | 4/459 | 5/239 | 0.9 |
| Humerus | 0/18 | 0/58 | 0/123 | 1/196 | 15/454 | 9/246 | 2.3 |
| Radius | 0/16 | 0/52 | 0/105 | 0/172 | 5/414 | 12/225 | 1.7 |
| Ulna | 0/16 | 0/51 | 0/105 | 0/172 | 6/417 | 11/220 | 1.7 |
| Innominate | 0/15 | 1/53 | 0/121 | 3/195 | 14/466 | 12/244 | 2.7 |
| Femur | 0/18 | 0/36 | 1/121 | 4/197 | 6/465 | 11/247 | 2.0 |
| Tibia | 0/14 | 0/48 | 0/97 | 0/172 | 1/409 | 0/227 | 0.1 |
| Fibula | 0/11 | 0/40 | 0/95 | 2/169 | 2/406 | 0/220 | 0.4 |

appendicular skeleton also were tested. The percentage of anomalies in the scapula was significantly lower than that in the innominate ($\chi^2=10.131$, $P=0.001$). Values obtained for the radius and the ulna were significantly higher than those corresponding to the tibia and the fibula, respectively (radius-tibia: $\chi^2=14.076$, $P<0.001$; ulna-fibula: $\chi^2=7.602$, $P<0.01$). Differences between the humerus and femur were not significant.

From the 110 specimens (55 males and 55 females) with observed bone anomalies, 25 (14 males and 11 females) showed alterations in more than one bone. These voles were of age classes 3 (one male and three females), 4 (five males and two females), and 5 (eight males and six females). In 11 of these 25 animals, anomalies occurred in the radius and ulna of one side. In another specimen, anomalies were seen in these bones but on both sides. In eight voles, alterations were observed simultaneously in the innominate and one other bone. Considering each bone separately, the following anomalies were observed.

Scapula

Ten abnormal scapulae belonging to 10 different voles (1.8% of the 564 specimens examined) were observed. Four had consolidated fractures, five had exostoses, and one exhibited a malformation. Fractures occurred in the proximal half, the borders, or the spine of scapula. Exostoses were ob-

served in the caudal border or the spine of scapula. The malformation observed was a modification in the form and size of the supraspinous fossa.

Humerus

Anomalies in 25 humeri from 23 individuals (4.1% of the 564 specimens examined) were recorded. These corresponded mainly to exostosis ($n=14$) or consolidated fractures ($n=2$) of the deltoid tuberosity (Fig. 1a,b). In one of these specimens, the exostoses occurred in both humeri. The other eight humeri (from seven individuals) had exostosis in different points of the diaphysis (Fig. 1a,b). In another humerus, a tumor-like proliferative enlargement in the diaphysis was observed (Fig. 1d).

Radius and ulna

Seventeen anomalous radii and 17 anomalous ulnae were found in 19 individuals (3.4% of the 564 specimens examined). Twelve specimens had abnormalities both in the radius and ulna of one of their limbs. One specimen showed abnormalities in both bones of both limbs. Exostosis in the diaphysis occurred in six radii and four ulnae (in three cases, ulna and radius corresponded to the same specimen). Among these bones, an ulna and a radius of an individual also had suffered a fracture leading to fusion with carpal bones. A radius of another animal also had a tumor-like neof ormation. Consolidated fractures

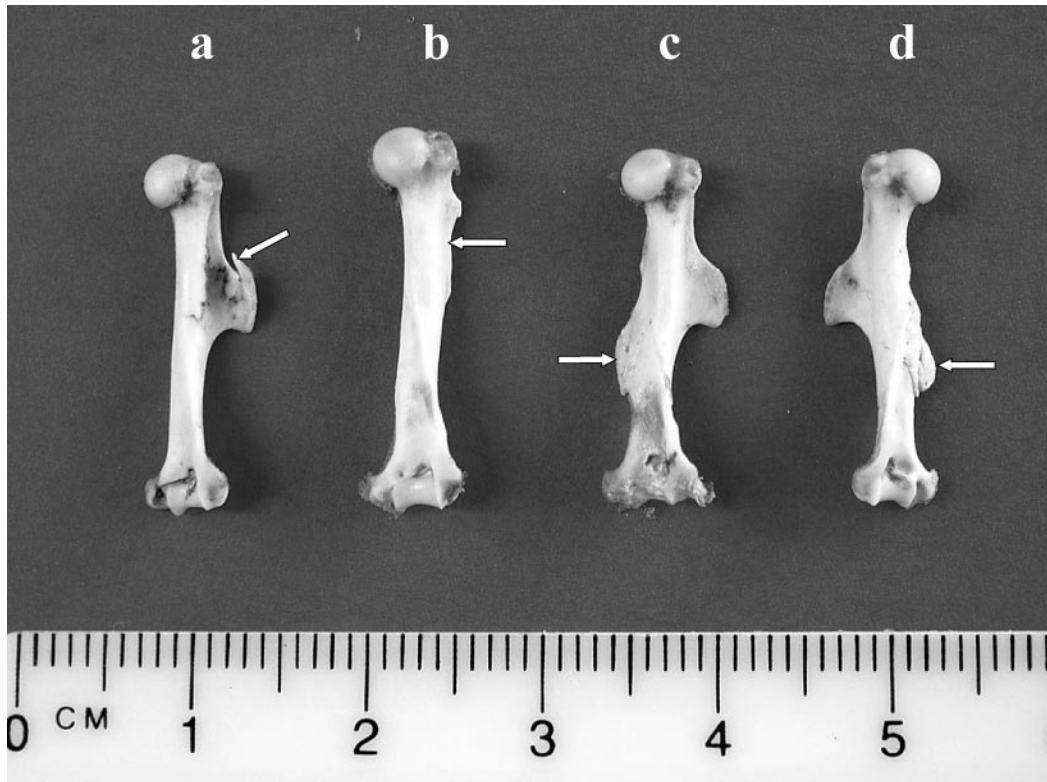


FIGURE 1. Anomalies in humeri of fossorial water voles. (a) Exostosis in the deltoid tuberosity (arrow). (b) Consolidated fracture in the deltoid tuberosity (arrow). (c) Exostosis in the diaphysis (arrow). (d) Tumor-like enlargement in the diaphysis (arrow).

or fissures were recorded in the diaphysis of seven radii and seven ulnae. In six cases, the radius and ulna were both from the same vole. In the other two cases, one animal had a consolidated fracture in the diaphysis of a radius, and the other had a fracture in the olecranon of an ulna.

Ossifications between radius and ulna were detected twice (different specimens), and in one case, both bones were fused with carpal elements. Excluding the radius with a tumor-like neoformation as mentioned above, signs of this pathology also were detected in two ulnae from a specimen and in one radius and an ulna of another animal.

Innominate

Thirty abnormal innominates were found in 25 individuals (4.4% of the 564 specimens examined). We did not consider

the modifications of the pubis shape (narrowing and enlargement) occurring in adult females from pregnancy and parturition (Ventura et al., 1991). Likewise, neither ossifications in the pubic symphysis nor small spines that frequently occur in the margin of the obturator foramen were scored.

Exostoses were observed in 15 bones belonging to 11 animals (2.0% of the 564 specimens examined) (Fig. 2a,b). These anomalies occurred in different points of the innominate, such as the ischium tuberosity ($n=6$, in four animals), caudal pubic ramus ($n=3$, in two specimens), acetabular region ($n=1$), lesser sciatic notch ($n=1$), and the ilium ($n=1$). Likewise, in one innominate, spines in the ischium and a supra-acetabular articular neoformation originating from a fracture was observed (Fig. 2c). In another bone, exostosis in the

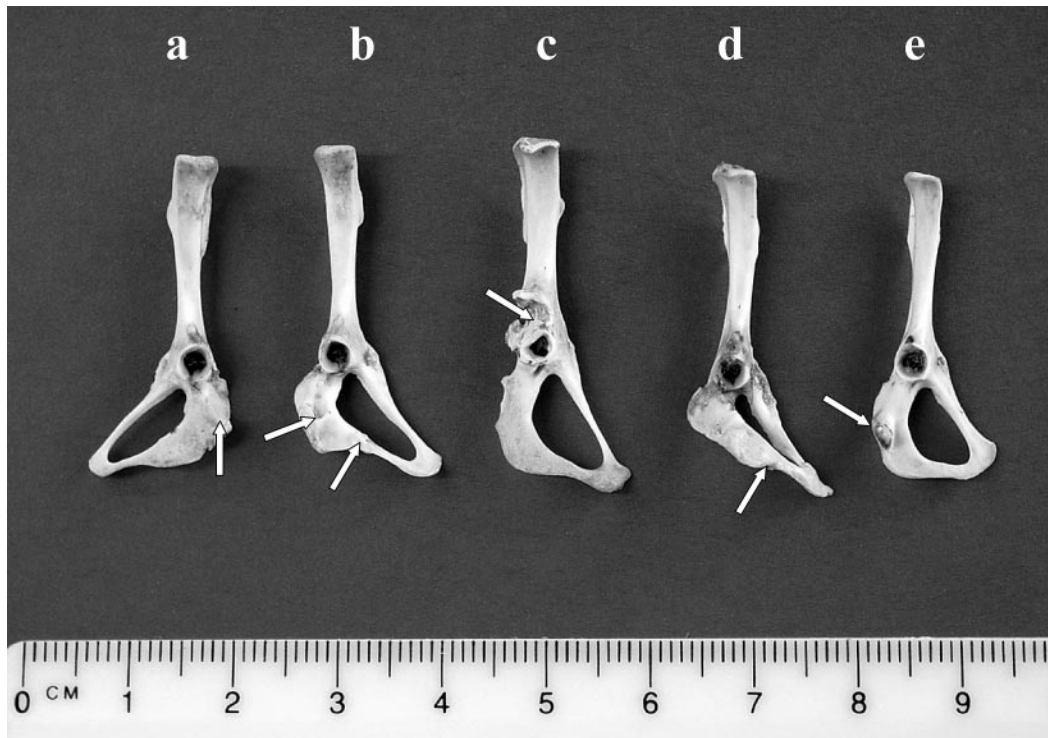


FIGURE 2. Anomalies in innominate of fossorial water voles. (a, b) Exostoses in the ischium (arrows). (c) Supra-acetabular articular neoformation originating from a fracture (arrow). (d) Consolidated fracture in the ischiopubic branch (arrow). (e) Neoformation in the ischial tuberosity (arrow).

sacroiliac region occurred together with an ischial consolidated fracture. Including this last case, consolidated fractures were detected in 17 innominates from 16 voles (2.8% of the 564 specimens examined). Most of these fractures ($n=14$, in 13 specimens) were located in the ischium or the ischiopubic branch (Fig. 2c). The other three fractures occurred in the acetabular region ($n=1$) or the pubis ($n=2$, in two specimens, one of which also had signs of fracture in the ischium). Additionally, in one innominate, a neoformation was observed in the ischial tuberosity (Fig. 2e).

Femur

From the 22 anomalous femurs detected in 22 different animals (3.9% of the 564 specimens examined), 10 showed exostoses in the third trochanter ($n=4$), the diaphysis ($n=5$), or the intertrochanteric crest ($n=1$). The other femurs had con-

solidated fractures at different levels. In five bones, fractures occurred exclusively in the third trochanter. Four bones showed fractures in the diaphysis, which in some cases were associated with a substantial shortening of the bone length. Two animals had signs of fractures at a proximal level of the bone (head, neck, and greater and lesser trochanters).

Tibia and fibula

The tibia and fibula had occasional anomalies. The distal portion of one tibia was modified, probably as a result of a fracture. Four fibulas suffered fractures, which were totally or partially consolidated. Each of these bones belong to different specimens ($n=5$; 0.9% of the 564 specimens examined).

DISCUSSION

The main macroscopic anomalies in the appendicular skeleton of *A. t. monticola*

were observed in adult specimens and corresponded to consolidated fractures and exostoses. Ossifications of ligaments, bony malformations, or tumor-like proliferations were noticeably less frequent. For each bone, the prevalence of these morphologic alterations was similar in both sexes and clearly related to age.

The social organization, spatial distribution, and burrowing kinetics of *A. t. monticola* have not been analyzed, but several studies of neighboring *A. t. scherman* have determined some of these aspects in fossorial water voles. Results obtained with this latter subspecies revealed that adult males and females defend their own territories against other individuals of their own sex (Saucy, 1988). In high-density situations, such as during the breeding season, this pattern probably becomes more pronounced. Likewise, polygyny occurring under several conditions (Saucy, 1988) also can promote social stress and, particularly, fights among males. Territoriality and occasional polygyny also probably is the rule in *A. t. monticola*, and some of the bony fractures and exostoses detected could be related with these ethologic patterns. In particular, in our sample, the prevalence of these bone anomalies was, for most bones, higher (but not significantly so) in males.

Another factor probably related with the origin of several bone anomalies in *A. t. monticola* is their digging activity. The appendicular skeleton of fossorial water voles shows several features connected to adaptive trends to burrow, although they can be considered to be discrete in relation to other hypogeal rodents (Laville, 1990). According to the burrowing pattern reported for fossorial *A. terrestris* (Laville, 1989), the head and thoracic limbs show a more dynamic function and, consequently, are subjected to a higher mechanical stress than the pelvic limbs. This is in agreement with our results, because when comparing the prevalence of anomalies in paired, equivalent long bones of both limbs, we found in all cases that the thoracic bones

showed higher percentages of morphologic alterations.

Another characteristic of the appendicular skeleton associated with burrowing in *A. t. scherman*, which also occurs in other fossorial rodents, is the expansion of the deltopectoral insertion crest of the humerus with respect to the shoulder joint, which increases the efficacy of the deltoid, pectoral, and teres major muscles. This could be related to the push and traction of the head and thoracic limbs (Laville, 1990). In concordance with this observation, the humerus was the long bone with the highest percentage of anomalies in our sample. Most of their fractures and exostoses were observed in the deltoid tuberosity; specifically, exostoses were detected mainly in muscular insertion points. These results suggest that in fossorial water voles, muscles involved in burrowing are related, to a certain degree, to the induction of exostoses. In fact, this is in agreement with the conclusion of Yeager (1985) that tension alone can cause the formation of this bone anomaly in rats.

Morphologic alterations of the girdles also could be affected by ethologic and biomechanical factors, although in the case of the innominate, factors related to sex are involved as well. The scapula of fossorial *A. terrestris* can be considered to be a relay for the thoracic limb musculature, particularly the digging movements, in which these two regions work synergistically (Laville, 1990). Thus, alterations of normal scapula morphology originating from burrowing activity also can be expected. Nevertheless, although the anomalies most frequently observed in this bone were signs of fractures and exostoses, their prevalence can be considered to be moderate.

The prevalence of macroscopic alterations in the innominate was the highest among all bones of both sexes and was not significantly different between males and females. The available information clearly does not explain the relatively high percentage obtained in males. The fragility of

the ischium and pubis, in which most fractures and exostoses were detected, could be related to this result. In females, the pelvis of *A. t. monticola* suffers substantial morphologic changes because of the action of estrogenic hormones during pregnancy and parturition (Ventura et al., 1991). Therefore, the morphologic remodeling occurring in the innominate of multiparous females could enhance the appearance of fractures and exostoses in this structure. On the other hand, we have not considered the prevalence of several modifications of the adult female pubis morphology because of the endocrine factors mentioned above. If these morphologic changes were scored, it would be clear that the differences in the prevalence of the modifications between the innominate and the other structures analyzed here would be increased substantially; accordingly, sexual differences would become significant.

The present results could serve as a basis for future interspecific comparative analyses. In particular, they could be of interest to evaluate the intensity and effect of the factors that constitute the origin of girdle and limb long bone anomalies in other rodent populations.

ACKNOWLEDGMENTS

We thank M. J. López Fuster (Universitat de Barcelona) for criticizing an early version of this report and Rosemary Thwaité for revising the English.

LITERATURE CITED

- AIROLDI, J.-P. 1991. Le terrier de la forme fouisseuse du campagnol terrestre (*Arvicola terrestris* L.): structure et fonction. In *Le rongeur et l'espace*, M. Le Berre and L. Le Guelte (eds). R. Chabaud, Paris, France, pp. 285–297.
- ARRIZABALAGA, A., AND E. MONTAGUT. 1990. Patologia òssia en petits mamífers (Insectívors i Rossegadors). *El Medi Natural*, Annals del CEEM 2: 227–232.
- BECKER, K. 1966. Über das Auftreten von Skelettanomalien bei wildlebenden Muriden. *Sitzungsberichte der Gesellschaft Naturforschender Freunde* 6: 1–5.
- HAMAR, M. 1970. Knochenbrüche und Anomalien am Skelett von Nagetieren aus Raubvogelgewöhlen. *Säugetierkundliche Mitteilungen* 18: 115–117.
- INTERNATIONAL COMMITTEE ON VETERINARY ANATOMICAL NOMENCLATURE. 1994. *Nomina anatomica veterinaria*. 4th Edition. World Association of Veterinary Anatomists, Ithaca, New York, 349 pp.
- KRATOCHVÍL, J. 1983. Variability of some criteria in *Arvicola terrestris* (Arvicolidae, Rodentia). *Acta Scientiarum Naturalium Brno* 17: 1–40.
- LAVILLE, E. 1989. Étude cinématique du fouissage chez *Arvicola terrestris scherman* (Rodentia, Arvicolidae). *Mammalia* 53: 177–189.
- . 1990. Étude morphofonctionnelle comparative des structures osseuses impliquées dans le fouissage d'*Arvicola terrestris scherman* (Rodentia, Arvicolidae). *Canadian Journal of Zoology* 68: 2437–2444.
- NORUSIS, M. J. 1997. *SPSS professional statistics 7.5*. SPSS, Inc., Chicago, Illinois.
- REIG, O. A., C. BUSCH, M. O. ORTELLS, AND J. CONTRERAS. 1990. An overview of evolution, systematics, population biology, cytogenetics, molecular biology, and speciation in *Ctenomys*. In *Evolution of subterranean mammals at the organismal and molecular levels*, E. Nevo and O. A. Reig (eds). Wiley-Liss, New York, New York, pp. 71–96.
- SAUCY, F. 1988. Dynamique de population, dispersion et organisation sociale de la forme fouisseuse du Campagnol terrestre (*Arvicola terrestris scherman* (Shaw), Mammalia, Rodentia). PhD Thesis, Université de Neuchâtel, Neuchâtel, Switzerland, 366 pp.
- . 1994. Density dependence in time series of the fossorial form of the water vole, *Arvicola terrestris*. *Oikos* 71: 381–391.
- VENTURA, J. 1992. Morphometric data on the scapula and limb long bones of *Arvicola terrestris* (Linnaeus, 1758) (Rodentia, Arvicolidae). *Revue Suisse de Zoologie* 99: 629–636.
- , AND J. GOSÁLBEZ. 1990. Reproductive cycle of *Arvicola terrestris* (Rodentia, Arvicolidae) in the Aran Valley, Spain. *Zeitschrift für Säugetierkunde* 55: 383–391.
- , AND ———. 1992. Criterios para la determinación de la edad relativa en *Arvicola terrestris monticola* (Rodentia, Arvicolidae). *Miscel·lània Zoològica* 16: 197–206.
- , ———, AND V. GÖTZENS. 1991. The os coxae of a digging form of the northern water vole, *Arvicola terrestris* (Rodentia, Arvicolidae). *Anatomia, Histologia, Embryologia* 20: 225–236.
- YEAGER, V. L. 1985. Periosteal stimulation by artificial tension. *Journal of Experimental Pathology* 2: 37–40.

Received for publication 3 December 2004.