



AN OUTBREAK OF EASTERN EQUINE ENCEPHALITIS VIRUS IN FREE-RANGING WHITE-TAILED DEER IN MICHIGAN

Authors: Schmitt, Stephen M., Cooley, Thomas M., Fitzgerald, Scott D., Bolin, Steven R., Lim, Ailam, et al.

Source: Journal of Wildlife Diseases, 43(4) : 635-644

Published By: Wildlife Disease Association

URL: <https://doi.org/10.7589/0090-3558-43.4.635>

BioOne Complete (complete.BioOne.org) is a full-text database of 200 subscribed and open-access titles in the biological, ecological, and environmental sciences published by nonprofit societies, associations, museums, institutions, and presses.

Your use of this PDF, the BioOne Complete website, and all posted and associated content indicates your acceptance of BioOne's Terms of Use, available at www.bioone.org/terms-of-use.

Usage of BioOne Complete content is strictly limited to personal, educational, and non - commercial use. Commercial inquiries or rights and permissions requests should be directed to the individual publisher as copyright holder.

BioOne sees sustainable scholarly publishing as an inherently collaborative enterprise connecting authors, nonprofit publishers, academic institutions, research libraries, and research funders in the common goal of maximizing access to critical research.

AN OUTBREAK OF EASTERN EQUINE ENCEPHALITIS VIRUS IN FREE-RANGING WHITE-TAILED DEER IN MICHIGAN

Stephen M. Schmitt,¹ Thomas M. Cooley,¹ Scott D. Fitzgerald,^{2,3} Steven R. Bolin,^{2,3} Ailam Lim,^{2,3} Sara M. Schaefer,⁴ Matti Kiupel,^{2,3} Roger K. Maes,² Stephanie A. Hogle,¹ and Daniel J. O'Brien^{1,5}

¹ Wildlife Disease Laboratory, Michigan Department of Natural Resources, 4125 Beaumont Rd., Room 250, Lansing, Michigan 48910-8106, USA

² Diagnostic Center for Population and Animal Health, Michigan State University, East Lansing, Michigan 48824, USA

³ Department of Pathobiology and Diagnostic Investigation, Michigan State University, East Lansing, Michigan 48824, USA

⁴ Southwestern Management Unit, Wildlife Division, Michigan Department of Natural Resources, 621 N. 10th St., Plainwell, Michigan 49080-1004, USA

⁵ Corresponding author (e-mail: obriend@michigan.gov)

ABSTRACT: Eastern equine encephalitis (EEE) virus has been recognized as affecting horses and humans in the eastern United States for 70 yr. Evidence of exposure with EEE virus has been reported in a variety of free-ranging wild birds and mammals but cases of clinical disease are much less commonly reported. In Michigan, reports of outbreaks of EEE virus in equine species extend back more than a half century. We report diagnosis of EEE virus infection of multiple free-ranging white-tailed deer (*Odocoileus virginianus*) from three Michigan counties during late summer of 2005. Infection was confirmed in seven of 30 deer collected based on reported neurologic signs and results from immunohistochemistry, polymerase chain reaction, and/or virus isolation. One of the deer also was infected with West Nile virus and an eighth deer had microscopic lesions in the cerebrum consistent with those reported for EEE. To our knowledge, this is the first report of multiple cases of EEE in free-ranging white-tailed deer, and highlights several issues of significance to wildlife managers and public health officials.

Key words: Arboviruses, eastern equine encephalitis, neurologic disease, *Odocoileus virginianus*, West Nile virus, white-tailed deer.

INTRODUCTION

Eastern equine encephalitis (EEE), caused by an arthropod-borne Group A *Alphavirus* of the *Togaviridae* family (ICTVdB Management, 2006), has affected horses (Giltner and Shahan, 1933) and humans (Fothergill et al., 1938) in the eastern United States for at least 70 yr. Maintained in nature by infection of wild birds, EEE virus is transmitted among them primarily by the mosquito *Culiseta melanura*, whereas *Aedes* spp. and *Cophillettidia* spp. mosquitoes are bridge vectors responsible for transmission of EEE virus to other species. Principal concerns about the virus derive from its zoonotic character (Acha and Szyfres, 1980). Human infections with EEE virus occur sporadically, but can result in acute onset febrile illness progressing to neurologic signs, with case fatality rates of 35%

to 75% and long-term neurologic sequelae in surviving patients (Stull et al., 2006). Similarly, horses with clinical EEE suffer high mortality, as well as permanent brain damage among some survivors (Acha and Szyfres, 1980).

Evidence of exposure to EEE virus has been reported in a variety of free-ranging wild birds (Hansen and Docherty, 1999) and mammals, particularly rodents (Yuill and Seymour, 2001), although cases of clinical disease are less commonly reported and involve only a few species. In Michigan, reports of sporadic but sometimes large outbreaks of EEE in equine species extend back more than a half century (Brown, 1947). The first human case of EEE was reported in 1980 (Centers for Disease Control, 1980), and since that time, status as a reportable disease has facilitated annual surveillance in humans (Centers for Disease Control,

1992) and horses (Centers for Disease Control, 1993, 1995), as well as captive-raised ring-necked pheasants (*Phasianus colchicus*) (Centers for Disease Control, 1995). The epidemiology and natural history of EEE have been well-described previously (Scott and Weaver, 1989), and epidemiological analyses of recent equine outbreaks (Ross and Kaneene, 1995, 1996) and vector species identification (Shaw, 1976) also have been carried out in Michigan. Limited efforts have been made to identify free-ranging bird and rodent hosts to assess the risk they might pose as reservoirs (McLean et al., 1985). However, little attention has been paid to surveillance of other wild mammals to characterize EEE as an unrecognized source of mortality and potential human exposure. The clinical history, presentation, and detailed pathologic presentation of fatal EEE virus infection was recently described in a free-ranging white-tailed deer (*Odocoileus virginianus*) from Georgia (Tate et al., 2005). A solitary case has also been recorded in white-tailed deer in Wisconsin in 2004 (J. Langenberg, Wisconsin Department of Natural Resources, pers. comm.). We report here a series of cases of EEE diagnosed in free-ranging Michigan white-tailed deer during late summer of 2005.

MATERIALS AND METHODS

Case acquisition

Since 2002, the Michigan Department of Natural Resources (MDNR) has carried out an ongoing surveillance program for chronic wasting disease (CWD) in free-ranging cervids. One component of that program is the targeted testing of cervids displaying clinical signs that could be consistent with CWD, particularly abnormal behavior or other neurologic signs. Acting on reports by the public or local law enforcement agencies, MDNR personnel investigate sightings of symptomatic deer. If confirmed as showing neurologic signs in the field, such animals are euthanized and transported to the MDNR Wildlife Disease Laboratory (WDL) for necropsy and diagnostic workup, in collaboration with the Diagnostic Center for Population and Animal

Health (DCPAH), Michigan State University. The WDL and DCPAH are located together in a building certified by the Centers for Disease Control and Prevention (CDC) for possession and diagnostic testing of EEE virus and other Select Agents, as designated by the United States Departments of Agriculture and Health and Human Services.

Between 19 and 28 August 2005, five sick deer in close proximity to Townsend Park in Kent County (43°03'N, 85°27'W) were reported to local law enforcement agencies by citizens. The deer displayed various combinations of clinical signs, including confusion, ataxia, head tilt, circling, blindness, loss of fear of humans, prostration, dyspnea, ptialism, and emaciation in various combinations. Four of the initial five cases were euthanized by officers and disposed of in landfills. A newspaper article speculated that the deer were affected by CWD (Sharp, 2005). Subsequently, the cases were reported to MDNR, but only one of the initial five carcasses (Case 1, Table 1) could be then be recovered for examination. Over the course of the next 15 wk, 29 additional deer from seven counties (Barry, Ionia, Kalamazoo, Kent, Montcalm, Muskegon, and Ottawa; Fig. 1) were collected by MDNR field staff because of public reports of similar clinical signs and transported to WDL for examination.

Gross and histopathology

Carcasses were aged by tooth eruption and wear (Severinghaus, 1949), and categorized as fawns (young of the year), yearlings (1–1.5 yr old) and adults (≥ 2 yr old). Complete necropsies were conducted on each deer in a Biosafety Level 3 Ag (BL-3) environment (USDA-ARS, 2002) by methods similar to those previously described (Canadian Cooperative Wildlife Health Centre, 1993). Exams were systematic by organ system, and reported on a standard WDL form linked to a relational database (Access 2002, Microsoft Corporation, Redmond, Washington, USA). Samples of medial retropharyngeal lymph node from all deer collected were tested for CWD via a commercially available enzyme-linked immunosorbent assay (ELISA; Hibler et al., 2003) following manufacturer's recommendations (Bio-Rad Laboratories, Inc., Hercules, California, USA). Deer were defined as EEE suspects if they were reported as displaying neurologic signs yet lacked definitive gross lesions which could unequivocally explain the animal's presentation. Brains and eyes were collected from all suspects, fixed in 10% neutral-buffered formalin, and submitted for

TABLE 1. Diagnostic findings for eastern equine encephalitis (EEE) -positive and -suspicious white-tailed deer, Michigan, 2005.

Case No.	Wildlife Disease Laboratory No.	Date collected	County	Latitude Longitude	Age ^a	Sex ^b	Pathology		EEE		WNV ^c	
							Gross	Microscopic	IHC	PCR	IHC	PCR
1	05-352	19 August 2005	Kent	43°03'54" 85°27'38"	Y	M	NL ^d	Encephalitis	+	+	-	-
2	05-446	6 September 2005	Kent	43°04'45" 85°37'09"	A	M	NL	Encephalitis	-	+	-	+
3	05-450	13 September 2005	Kent	43°04'45" 85°30'01"	Y	F	NL	Meningo-encephalitis	+	+	-	-
4	05-470	17 September 2005	Montcalm	43°09'21" 85°08'36"	Y	M	NL	Meningo-encephalitis	+	+	NP	-
5	05-469	18 September 2005	Kent	43°03'53" 85°28'49"	F	F	NL	Encephalitis	-	+	-	-
6	05-543	10 October 2005	Ionia	43°03'59" 85°18'10"	F	F	NL	Meningo-encephalitis	+	+	NP	-
7	05-531	10 October 2005	Kent	42°58'38" 85°33'40"	F	M	NL	Encephalitis	+	+	NP	-
8	05-582	21 October 2005	Kent	42°54'27" 85°19'18"	F	F	NL	Encephalitis	+	-	NP	-

^a F (fawn), Y (yearling), A (adult).

^b F (female), M (male).

^c West Nile virus.

^d No lesions.

^e Not performed.

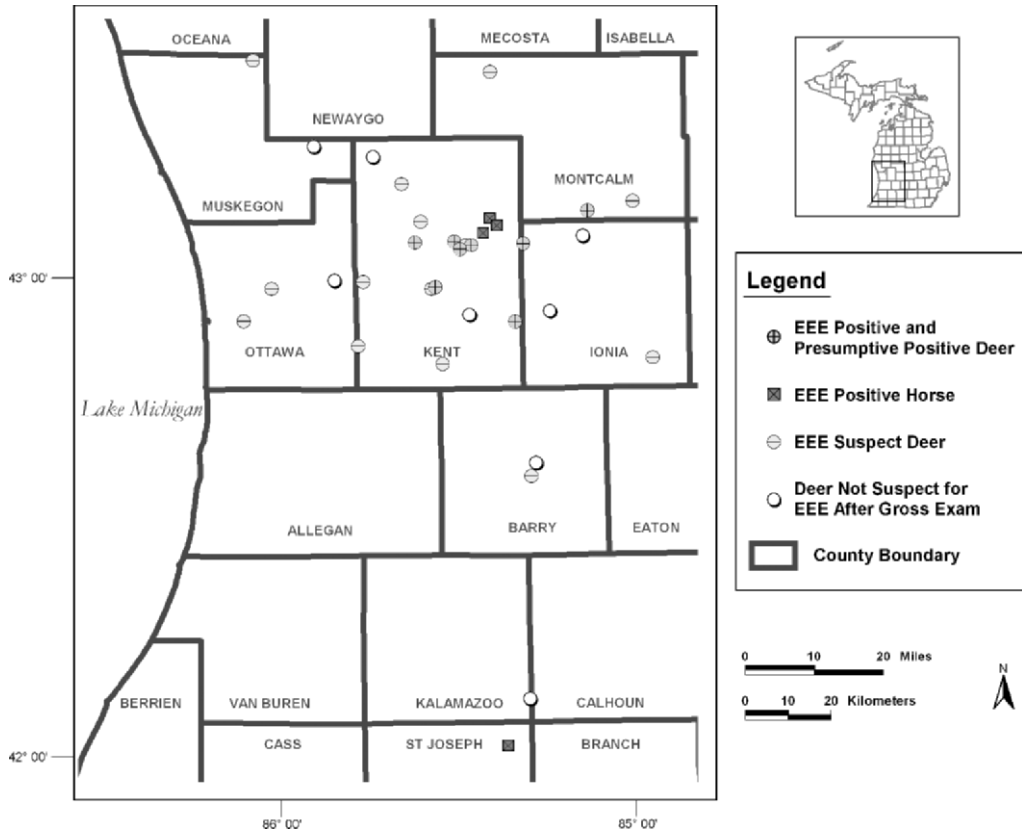


FIGURE 1. Locations of white-tailed deer comprising this case series, Michigan, 2005.

additional diagnostic testing. Representative sections of cerebrum, cerebellum, brain stem, and eye for histopathology were trimmed into cassettes. Samples were paraffin-embedded, sectioned at 5 µm, and routinely stained with hematoxylin and eosin for microscopic examination.

Immunohistochemistry

In addition to CWD, differential diagnoses included West Nile virus (WNV) and EEE; consequently, additional testing for those agents included immunohistochemical staining (IHC) of brain tissue for each deer with microscopic lesions. Formalin-fixed tissues were trimmed, embedded in paraffin, and sectioned at 5 µm. An Enhanced V Red (Alkaline Phosphatase Red) Detection System (Ventana Medical Systems, Inc., Tucson, Arizona, USA), as well as bulk buffers specifically designed for use on the BenchMark Automated Staining System (Ventana Medical Systems), were used for immunolabeling and visualization. Slides were baked in

a drying oven at 60 C for 20 min. The slides were then barcode labeled, and placed in the BenchMark for deparaffinization and heat-induced epitope retrieval. Antigen retrieval was performed using protease. A rabbit-polyclonal anti-EEE antibody (Centers for Disease Control and Prevention, Atlanta, Georgia, USA) at a concentration of 1:500 for 30 min was used as the primary antibody. The slides were counterstained using Ventana hematoxylin (Ventana Medical Systems) and bluing for 2 min each, then dehydrated, cleared, and mounted. Formalin-fixed, paraffin-embedded sections of brain from a horse that had previously tested positive for EEE infection using RT-PCR were used as a positive control.

Preparation of tissues for polymerase chain reaction (PCR)

For all but the first three suspects, fresh brain samples were also collected for virus isolation (VI) and PCR on homogenized cerebrum and brainstem. Fresh tissues were processed in BL-3 facilities using appropriate

personal protective equipment and laboratory practices. Approximately 200 mg each of cerebrum and brain stem were trimmed from recently thawed brain. The trimmed tissues were placed into separate cryovials containing several 0.5 mm glass beads and 1.8 ml of cell culture Medium 199 (Sigma-Aldrich, St. Louis, Missouri, USA) supplemented to 6% with fetal bovine serum (tested free of antibody against West Nile virus). The tissues were homogenized in a bead beater and the homogenates were poured into 1.5 ml microcentrifuge tubes. The homogenates were clarified by centrifugation and a 200 μ l aliquot of clarified supernatant was mixed with 800 μ l of TRIzol ReagentTM (Invitrogen, Carlsbad, California, USA) for extraction of RNA for PCR, following the manufacturer's recommendations. For formalin-fixed paraffin embedded tissue, a 20 μ m section was placed in a cryovial containing a ceramic bead, and pulverized using a FastPrep 100 (Thermo Fisher Scientific, Inc., Waltham, Massachusetts, USA). The pulverized tissue was mixed with 800 μ l of TRIzol, and RNA was extracted for PCR.

Preparation of frozen tissue for virus isolation

A 0.5 ml aliquot of the same clarified brain tissue homogenate was injected through a 0.45 μ m filter into a 25 cm² cell culture flask seeded with Vero cells. The cell cultures were incubated at 38 C and observed daily for cytopathic effect. If cytopathic effect occurred, 0.5 ml of cell culture medium was removed from the flask and used to inoculate a second flask containing freshly seeded Vero cells. After 48 hr of incubation, 200 μ l of cell culture medium was removed from the second flask and mixed with 800 μ l TRIzol ReagentTM for extraction of RNA for PCR.

Polymerase chain reaction

A single tube reverse transcription, polymerase chain reaction (RT-PCR) assay using the SuperScriptTM One-Step RT-PCR with Platinum[®] Taq Kit (Invitrogen) was performed to detect RNA from EEE virus. The primers used produced a 112 base pair amplicon from the viral capsid gene (Vodkin et al., 1993). The reaction conditions were 50 C for 30 min, 94 C for 4 min, 40 cycles of 94 C for 30 sec, 52 C for 30 sec, 72 C for 30 sec, followed by a final extension of 5 min at 72 C. The amplification products were analyzed in ethidium bromide-stained 1.5% agarose gels using a sodium borate buffer (Brody and Kern, 2004).

A TaqMan Reverse Transcriptase-PCR assay was used to detect RNA from WNV (Lanciotti et al., 2000). The reaction mixture

consisted of 0.75 μ M of forward primer, 1.0 μ M of reverse primer, 0.2 μ M of TaqMan probe, 3 μ l of RNA, and TaqMan[®] RT-PCR Master Mix Reagents (Applied Biosystems, Foster City, California, USA) in a 25 μ l reaction volume. The reaction conditions were 48 C for 30 min, 95 C for 10 min, 40 cycles of 95 C for 15 sec, and 60 C for 1 min, performed in an ABI 7000 Prism Sequence Detection System (Applied Biosystems).

Select samples of RNA from cell culture isolates of EEE virus were subjected to a RT-PCR assay that produced an 842 base pair amplicon that spanned the E2, 6 kDa, and E1 proteins of EEE virus. The primers used, ATTATCGGGTTATGCACCTG-forward and GACAGTGGACCTATGATGAG-reverse, were designed from the published sequence of the EEE Georgia-97 strain (GenBank accession number AY705240). First-strand cDNA was synthesized using the reverse primer and SuperScriptTM II Reverse Transcriptase (Invitrogen), following protocols supplied with the enzyme. The PCR was performed using 2 μ l of cDNA and Platinum[®] Taq DNA Polymerase High Fidelity Reagents (Invitrogen). The reaction conditions were 94 C for 4 min, 40 cycles of 94 C for 45 sec, 55 C for 45 sec, 68 C for 1 min, followed by a final extension of 10 min at 68 C. The resulting amplicon was excised from the gel, purified with QIAquick Gel Extraction Kit (Qiagen Inc., Valencia, California, USA), and eluted in 30 μ l of nuclease-free water.

Nucleic acid sequencing

The purified amplicons were submitted to the Research Technology Support Facility, Michigan State University for nucleic acid sequencing. The nucleic acid sequences were edited using Sequencher software (Gene Codes Corporation, Ann Arbor, Michigan, USA), and aligned to available sequences from EEE virus using Clone Manager Suite 7 (Scientific and Educational Software, Cary, North Carolina, USA).

Statistical analysis

A deer was defined as EEE and/or WNV positive if it returned a positive result on RT-PCR and/or VI confirmed by PCR, while also displaying consistent microscopic lesions. A two-tailed Fisher's exact test (Stata, Version 5, Stata Corporation, College Station, Texas, USA) was used to determine whether statistically significant differences by age and sex were present between EEE-positive and -negative deer (Thrusfield, 1995). Significance was considered attained at $P \leq 0.05$.

RESULTS

All 30 deer that were collected based on reported clinical signs were negative for CWD. Eight of these did not meet the criteria for EEE-suspect status because they showed gross lesions at necropsy that could unequivocally explain their reported clinical signs (blunt trauma, cranial abscesses and fractures, spinal fractures, actinomycosis, and chronic pneumonia, pleuritis, and/or peritonitis). No further diagnostic testing was undertaken on these deer. Of the remaining 22 defined as suspects, seven tested positive for EEE by RT-PCR and/or VI with consistent histopathology (Cases 1–7). Five of these seven (Cases 1, 3, 4, 6, and 7) were also positive by IHC. Another deer (Case 8) was considered suspicious for EEE based on histopathology and positive IHC (Table 1). One deer (Case 2) was positive for both EEE and WNV. West Nile virus infection in white-tailed deer has been reported only once previously (Miller et al., 2005). Histopathologic lesions in all EEE-positive deer were similar, generally present in all levels of the brain examined (cerebrum, cerebellum, brain stem), and primarily limited to the gray matter. Lesions common to all were moderate to marked perivascular accumulations of lymphocytes, plasma cells, and lesser numbers of neutrophils. This perivascular infiltrate was present in the Virchow-Robin spaces within the parenchyma, as well as in the meninges. Additional brain lesions in some but not all EEE-positive deer included diffuse gliosis, multifocal glial nodular aggregates, scattered degenerate or necrotic neurons, glial cells surrounding individual neurons (satellitosis), and perivascular hemorrhage. Microscopic examination of tissues from the remaining 14 (EEE-negative) suspect deer showed one nonspecific encephalitis, one with cysts of *Toxoplasma gondii*, and twelve deer that had no diagnostic microscopic lesions that could explain the neurologic signs reported by the public.

Fresh-frozen brain tissue was available from 19 of the 22 EEE suspect deer, and cytopathic virus was isolated from two (Cases 3 and 4, Table 1). The RNA extracts from these isolates were positive for EEE virus and negative for WNV. Similarly, PCR assays done directly on RNA extracts of brain from which viruses were isolated were positive for EEE virus and negative for WNV. The RNA extracted directly from homogenates of fresh-frozen brain from three additional deer were also PCR-positive for EEE virus and negative for WNV. The PCR assays of formalin-fixed brain for three other deer for which frozen brain was not available showed two of three positive for EEE virus and one of three (Case 2, Table 1) positive for WNV.

The nucleic acid sequences from EEE viruses isolated from Cases 3 and 4 were identical to each other and to the sequence from EEE virus isolated concurrently from a Michigan horse. They varied by 1 and 4 bases, respectively, from the sequences from EEE viruses isolated during the same time period from a second Michigan horse and an Ohio pony. Comparison of nucleic acid sequences from deer with sequences from EEE viruses isolated recently in North America (GenBank accessions AY705240, AY705241, NC003899, and AY722102) showed $\geq 98\%$ similarity. The similarity in the corresponding predicted amino acid sequences was $\geq 99\%$.

Among the 22 suspect deer tested for EEE, no statistically significant differences were noted between positive and negative deer by either sex ($P=1.0$) or age ($P=0.47$).

DISCUSSION

Although it occurs only rarely, EEE remains an important zoonotic disease in Michigan from both public health and economic perspectives. During the period 2000–2004, Michigan reported an average of 1.2 human cases per year, the second

highest in the country (Centers for Disease Control and Prevention, 2006). Case fatality rates in humans are high (35–75%). Moreover, lingering severe neurologic effects in survivors have been estimated to accrue lifetime disease-related expenses of US\$3,000,000 per patient (Villari et al., 1995). Although comparable EEE-specific economic data are not available, on a per case basis, management of neurologic conditions in Michigan equines carries the highest median monetary expenditures, labor use, and performance days lost of any health management category (Lloyd and Kaneene, 1997). For these reasons and others, it seems likely that EEE will continue to be scrutinized with interest, regardless of the species in which it occurs.

The geographic expansion of CWD has garnered increased attention for neurologic diseases in free-ranging deer. The major differential diagnoses include bacterial meningitis or abscesses (often originating with antler injuries), toxoplasmosis, *Parelaphostrongylus tenuis* infection, WNV, and EEE. Bacterial disease is characterized by suppurative (neutrophilic) inflammation. *Toxoplasma* and meningeal worm generally cause necrosis of the brain parenchyma, and parasites are frequently present in histologic section. Viral encephalitis is generally nonsuppurative, characterized predominantly by lymphocytes and plasma cells. An unusual feature of both EEE and West Nile virus encephalitis is the frequent presence of small numbers of neutrophils admixed with predominantly mononuclear cell infiltrates. This feature was present in a number of our deer cases, and helped direct initial diagnostic testing toward these two etiologies. As more deer brains are examined as part of targeted CWD surveillance, diagnosticians might find this feature useful, particularly if surveillance relies exclusively upon ELISA or IHC for CWD and basic histopathology.

Four cases of EEE in horses were

diagnosed in Michigan in 2005 in the vicinity of the deer cases (Fig. 1). The equine EEE cases preceded the cervine cases by a few weeks. The diagnostic workup of the horses was also performed at DCPAH. All four equine cases were confirmed positive for EEE on both PCR and VI. No significant variation in histopathology was present when comparing the brain lesions in the four EEE-positive horses to the EEE-positive deer. As in the deer, one of the horses was coinfecting with WNV. Horses, deer, and other mammals are incidental, dead-end hosts of EEE virus. Under natural transmission conditions, they are only infected by bridge vectors, mosquito species that feed both on birds and large mammals (Hansen and Docherty, 1999). Avian epizootics, maintained by these bridging mosquitoes, amplify the virus, and are the route by which EEE virus circulates out of its enzootic cycle in passerines, maintained by *C. melanura*. Palustrine wetlands (Cowardin et al., 1979) used for breeding by *C. melanura* are interspersed throughout the predominantly upland sites in which the EEE cases were found, but not to a markedly greater extent than surrounding areas. It is plausible that increases in numbers or activity of bridge vectors such as *Coquillettidia perturbans* (Crans and Schulze, 1986) and *Aedes vexans* (Cupp et al., 2003) implicated in equine outbreaks of EEE might result in cases in deer as well. Shaw (1976) considered *C. perturbans* to be the most likely major vector in a 1973 equine outbreak in Michigan. Vector activity would plausibly explain the proximity of the cervid and equine cases described here. The greater number of deer cases might simply reflect a greater risk of exposure resulting from their greater use of wetland habitats. If vector activity is actually responsible, models developed to predict outbreaks of EEE in horses based on precipitation (Ross and Kaneene, 1996) also might be useful in predicting EEE occurrence in deer, affording wildlife

agencies the opportunity to expedite surveillance and public education efforts in advance.

This case series highlights several issues of significance to wildlife managers. First, EEE should be considered as a seasonal rule-out for CWD suspects that are reported as part of targeted surveillance. Second, as noted by Tate et al. (2005), it seems likely that exposure to, and sub-clinical infections due to EEE occur more frequently in white-tailed deer than previously realized. Increased surveillance for CWD seems likely to locate additional EEE cases that otherwise would have gone undetected. Although McLean et al. (1985) failed to detect the presence of either EEE virus or neutralizing antibody in wild Michigan mammals, their sample was small (17) and limited to rodents. However, EEE antibodies were detected in a variety of free-ranging birds, and also in horses in that study. The proportion of birds with neutralizing antibody exceeded the proportion from which virus was isolated in 20 of 22 (91%) species sampled. This might reflect the short duration of EEE virus-induced viremia in birds, compared to the persistence of serum antibodies. We conducted a EEE seroprevalence survey in Michigan white-tailed deer in 2005, the results of which are reported separately. Third, white-tailed deer, like horses, might be useful as sentinel animals to alert public health authorities in areas where deer cases occur to potentially increased EEE risks for humans. Finally, wildlife managers should be mindful of the potential for occupational and recreational exposure to EEE among wildlife professionals and hunters. Human EEE infections in lab workers attributable to occupational exposure have been documented (Olitsky and Morgan, 1939; Gold and Hampil, 1942). It is conceivable, although perhaps unlikely, that wildlife professionals could be exposed to comparatively high virus concentrations if exposed to the blood of deer in the early stages of infection. Further,

wildlife professionals or hunters could inhale EEE virus that became aerosolized when sawing through brain tissue while removing antlers, or could self-inoculate by touching their eyes while their hands are contaminated with virus-bearing neural tissues. Consequently, in years when cervid EEE cases have been recorded, outreach efforts should be considered to encourage hunters to wear protective gloves and eyewear when sawing off antlers. Such recommendations were rapidly initiated in our study area once EEE cases were confirmed.

ACKNOWLEDGMENTS

We gratefully acknowledge MDNR field staff (E. Bedford, M. Bishop, W. Fuchs, C. Hanaburgh, D. Jones, G. Kalejs, J. Niewoonder), and conservation officer (D. Rodgers) for collection and transport of specimens, as well as the staff of Townsend Park and the Kent County Sheriff's Department (particularly K. Kazelskis) for cooperation in reporting the initial cases and response to subsequent ones. We thank E. Foster and M. Remick of the Michigan Departments of Community Health and Agriculture, respectively, for providing information on the infected horses, as well as two anonymous reviewers for their insightful comments on an earlier draft. This work was supported by the Federal Aid in Wildlife Restoration Act under Michigan Pittman-Robertson Project W-147-R.

LITERATURE CITED

- ACHA, P. N., AND B. SZYFRES. 1980. Zoonoses and communicable diseases common to man and animals. Pan American Health Organization, Washington, D.C., 701 pp.
- BRODY, J. R., AND S. E. KERN. 2004. Sodium boric acid: a Tris-free, cooler conductive medium for DNA electrophoresis. *Biotechniques* 36: 214–219.
- BROWN, G. C. 1947. Studies on equine encephalomyelitis in Michigan. *Journal of Infectious Diseases* 84: 48–54.
- CANADIAN COOPERATIVE WILDLIFE HEALTH CENTRE. 1993. 11.3 Necropsy of a mammal. In *Wildlife disease investigation manual*, G. WOBESER (ed.). Canadian Cooperative Wildlife Health Centre, Saskatoon, Saskatchewan, pp. 11-7 to 11-10.
- CENTERS FOR DISEASE CONTROL. 1980. Mosquito encephalomyelitis—United States. *Morbidity and Mortality Weekly Report* 29: 457–459.
- . 1992. Arboviral disease—United States,

1991. Morbidity and Mortality Weekly Report 41: 545–548.
- . 1993. Arboviral diseases—United States, 1992. Morbidity and Mortality Weekly Report 42: 467–468.
- . 1995. Arboviral disease—United States, 1994. Morbidity and Mortality Weekly Report 44: 641–644.
- . 2006. Eastern equine encephalitis—New Hampshire and Massachusetts, August–September 2005. Morbidity and Mortality Weekly Report 55: 697–700.
- COWARDIN, L. M., V. CARTER, F. C. GOLET, AND E. T. LAROE. 1979. Classification of wetlands and deepwater habitats of the United States. Office of Biological Services, Fish and Wildlife Service, United States Department of Interior, Washington D.C., 103 pp.
- CRANS, W. J., AND T. L. SCHULZE. 1986. Evidence incriminating *Coquillettia perturbans* (Diptera: Culicidae) as an epizootic vector of eastern equine encephalitis. Isolation of EEE virus from *C. perturbans* during an epizootic among horses in New Jersey. Bulletin of the Society of Vector Ecology 11: 178–184.
- CUPP, E. W., K. KLINGLER, H. K. HASSAN, L. M. VILGUERS, AND T. R. UNNASCH. 2003. Transmission of eastern equine encephalomyelitis virus in Central Alabama. American Journal of Tropical Medicine and Hygiene 68: 495–500.
- FOTHERGILL, L. D., J. H. DINGLE, S. FARBER, AND M. L. CONNERLY. 1938. Human encephalitis caused by the virus of the eastern variety of equine encephalomyelitis. New England Journal of Medicine 219: 411.
- GILTNER, L. T., AND M. S. SHAHAN. 1933. The 1933 outbreak of infectious equine encephalomyelitis in the eastern states. North American Veterinarian 14: 25–27.
- GOLD, H., AND B. HAMPIL. 1942. Equine encephalomyelitis in a laboratory technician with recovery. Annals of Internal Medicine 16: 556–569.
- HANSEN, W., AND D. E. DOCHERTY. 1999. Eastern Equine Encephalomyelitis. In Field manual of wildlife diseases: General field procedures and diseases of birds, M. Friend and J. C. Franson (eds.). U.S. Geological Survey, Washington, D.C. pp. 171–174.
- HIBLER, C. P., K. L. WILSON, T. R. SPRAKER, M. W. MILLER, R. R. ZINK, L. L. DEBUSE, E. ANDERSEN, D. SCHWEITZER, J. A. KENNEDY, L. A. BAETEN, J. F. SMELTZER, M. D. SALMAN, AND B. E. POWERS. 2003. Field validation and assessment of an enzyme-linked immunosorbent assay for detecting chronic wasting disease in mule deer (*Odocoileus hemionus*), white-tailed deer (*Odocoileus virginianus*) and Rocky Mountain elk (*Cervus elaphus nelsoni*). Journal of Veterinary Diagnostic Investigation 15: 311–319.
- ICTVD B MANAGEMENT. 2006. 00.073.0.01.008. Eastern equine encephalitis virus. In ICTVD B—The Universal Virus Database, version 4, C. Büchen-Osmond (ed.). Columbia University, New York, New York. www.ncbi.nlm.nih.gov/ictvdb/ictv/index.htm.
- LANCIOTTI, R. S., A. J. KERST, R. S. NASCI, M. S. GODSEY, C. J. MITCHELL, H. M. SAVAGE, N. KOMAR, N. A. PANELLA, B. C. ALLEN, K. E. VOLPE, B. S. DAVIS, AND J. T. ROEHRIG. 2000. Rapid detection of West Nile virus from human clinical specimens, field-collected mosquitoes, and avian samples by a TaqMan reverse transcriptase-PCR assay. Journal of Clinical Microbiology 38: 4066–4071.
- LLOYD, J. W., AND J. B. KANEENE. 1997. Economics of health management in the Michigan, USA equine industry. Preventive Veterinary Medicine 30: 1–8.
- MCLEAN, R. G., G. FRIER, G. L. PARHAM, D. B. FRANCY, T. P. MONATH, E. G. CAMPOS, A. THERRIEN, AND J. KERSCHNER. 1985. Investigations of the vertebrate hosts of eastern equine encephalitis during an epizootic in Michigan, 1980. American Journal of Tropical Medicine and Hygiene 34: 1190–1202.
- MILLER, D. L., Z. A. RADI, C. BALDWIN, AND D. INGRAM. 2005. Fatal West Nile virus infection in a white-tailed deer (*Odocoileus virginianus*). Journal of Wildlife Diseases 41: 246–249.
- OLITSKY, P. K., AND I. M. MORGAN. 1939. Protective antibodies against equine encephalomyelitis virus in the serum of laboratory workers. Proceedings of the Society of Experimental Biology and Medicine 41: 212–215.
- ROSS, W. A., AND J. B. KANEENE. 1995. A case-control study of an outbreak of eastern equine encephalomyelitis in Michigan (USA) equine herds in 1991. Preventive Veterinary Medicine 24: 157–170.
- , AND ———. 1996. Evaluation of outbreaks of disease attributable to eastern equine encephalitis virus in horses. Journal of the American Veterinary Medical Association 208: 1988–1997.
- SCOTT, T. W., AND S. C. WEAVER. 1989. Eastern equine encephalomyelitis virus: Epidemiology and evolution of mosquito transmission. Advances in Virus Research 37: 277–328.
- SEVERINGHAUS, C. W. 1949. Tooth development and wear as criteria of age in white-tailed deer. Journal of Wildlife Management 13: 195–216.
- SHARP, E. 2005. Deer show symptoms similar to disease. Detroit Free Press, Detroit, MI, September 2, 2005, p. 5D.
- SHAW, D. J. 1976. The determination of the potential vectors of eastern equine encephalitis in Michigan. M.S. Thesis, Michigan State University, East Lansing, Michigan, 76 pp.
- STULL, J. W., E. A. TALBOT, S. MACRAE, J. T. MONTERO, B. MATYAS, F. CANTOR, R. KONOMI,

- A. DEMARIA, E. B. HAYES, T. L. SMITH, R. S. NASCI, J. J. SEJVAR, D. R. O'LEARY, G. L. CAMPBELL, A. J. NOGA, R. S. LANCIOTTI, R. N. PLOTINSKY, S. SCHUMACHER, AND E. C. FARNON. 2006. Eastern equine encephalitis New Hampshire and Massachusetts, August–September 2005 (Reprinted from MMWR 55:697–700, 2006). *Journal of the American Medical Association* 296: 645–646.
- TATE, C. M., E. W. HOWERTH, D. E. STALLKNECHT, A. B. ALLISON, J. R. FISCHER, AND D. G. MEAD. 2005. Eastern equine encephalitis in a free-ranging white-tailed deer (*Odocoileus virginianus*). *Journal of Wildlife Diseases* 41: 241–245.
- THRUSFIELD, M. 1995. *Veterinary epidemiology*, 2nd Edition. Blackwell Science Ltd., Oxford, United Kingdom, 483 pp.
- USDA–ARS. 2002. USDA security policies and procedures for biosafety level-3 facilities. Departmental manual, United States Department of Agriculture—Agricultural Research Service, Washington, D.C., 32 pp.
- VILLARI, P., A. SPIELMAN, N. KOMAR, M. MCDOWELL, AND R. J. TIMPERI. 1995. The economic burden imposed by a residual case of eastern encephalitis. *American Journal of Tropical Medicine and Hygiene* 52: 8–13.
- VODKIN, M. H., G. L. MCLAUGHLIN, J. G. DAY, R. E. SHOPE, AND R. J. NOVAK. 1993. A rapid diagnostic assay for eastern equine encephalomyelitis viral-RNA. *American Journal of Tropical Medicine and Hygiene* 49: 772–779.
- YUILL, T. M., AND C. SEYMOUR. 2001. Eastern equine encephalitis. In *Infectious diseases of wild mammals*, E. S. Williams and I. K. Barker (eds.). Iowa State University Press, Ames, Iowa, pp. 106–107.

Received for publication 13 February 2007.