

FIELD IMPLANTATION OF INTRAPERITONEAL RADIOTRANSMITTERS IN EASTERN WOLF (CANIS LYCAON) PUPS USING INHALATION ANESTHESIA WITH SEVOFLURANE

Authors: Crawshaw, Graham J., Mills, Kenneth J., Mosley, Craig, and Patterson, Brent R.

Source: Journal of Wildlife Diseases, 43(4) : 711-718

Published By: Wildlife Disease Association

URL: <https://doi.org/10.7589/0090-3558-43.4.711>

BioOne Complete (complete.BioOne.org) is a full-text database of 200 subscribed and open-access titles in the biological, ecological, and environmental sciences published by nonprofit societies, associations, museums, institutions, and presses.

Your use of this PDF, the BioOne Complete website, and all posted and associated content indicates your acceptance of BioOne's Terms of Use, available at www.bioone.org/terms-of-use.

Usage of BioOne Complete content is strictly limited to personal, educational, and non - commercial use. Commercial inquiries or rights and permissions requests should be directed to the individual publisher as copyright holder.

BioOne sees sustainable scholarly publishing as an inherently collaborative enterprise connecting authors, nonprofit publishers, academic institutions, research libraries, and research funders in the common goal of maximizing access to critical research.

FIELD IMPLANTATION OF INTRAPERITONEAL RADIOTRANSMITTERS IN EASTERN WOLF (*CANIS LYCAON*) PUPS USING INHALATION ANESTHESIA WITH SEVOFLURANE

Graham J. Crawshaw,^{1,5} Kenneth J. Mills,^{2,4} Craig Mosley,³ and Brent R. Patterson⁴

¹ Toronto Zoo, 361A Old Finch Avenue, Scarborough, Ontario M1B 5K7, Canada

² Watershed Ecosystems Graduate Program, Trent University, 1600 West Bank Drive, Peterborough, Ontario K9J 7B8, Canada

³ Department of Clinical Sciences, College of Veterinary Medicine, Oregon State University, Corvallis, Oregon 97331, USA

⁴ Wildlife Research and Development Section, Ministry of Natural Resources, 2140 East Bank Drive, Peterborough, Ontario K9J 7B8, Canada; current address (Mills)

⁵ Corresponding author (email: gcrawshaw@torontozoo.ca)

ABSTRACT: In a study of wolf pup survival, intraperitoneal radio transmitters were surgically implanted in 53 (27 male and 26 female) 3.5- to 8-wk-old Eastern wolf (*Canis lycaon*) pups at den sites in Algonquin Provincial Park, Ontario, Canada, over two whelping seasons (2004 and 2005). Pups were manually removed from dens and initially injected with butorphanol at a dosage of 0.1 mg/kg for sedation and intra-operative analgesia. Anesthesia was induced and maintained with 3% sevoflurane in oxygen via a face mask. Meloxicam (0.3 mg/kg intramuscularly) was given to provide additional analgesia. All surgeries were completed without complications, and pups were readily accepted back into the packs. No postoperative complications were identified, but two pups from a single litter drowned as a result of being moved by the pack to a flooded den following the surgery. In five pups necropsied following natural deaths, transmitters were found lying free within the peritoneal cavity, and there was no evidence of infection at the surgical site or peritonitis. Inhalation anesthesia provided extremely rapid induction (1 min) and recovery (<3 min) and was completely controllable with no residual anesthetic effects. The equipment for inhalation anesthesia was readily portable in field packs, and it has considerable advantages over injectable drugs for small and very young animals such as wolf pups. The utility of the procedure is demonstrated by the minimal effect it had on subsequent pup survival, the rapid recovery of pups following surgery, and the lack of long-term complications as determined by necropsies of pups following natural deaths.

Key words: Anesthesia, *Canis lycaon*, intraperitoneal implantation, radiotelemetry, sevoflurane, surgery.

INTRODUCTION

There have been few studies into denning ecology and pup survival of wolves (Fritts and Mech, 1981; Ballard and Dau, 1983; Fuller, 1989; Ciucci and Mech, 1992; Boyd et al., 1993). This likely reflects concern over the negative effects of den disturbance and the difficulty in marking and monitoring juvenile carnivores (Mech, 1977; Laurenson and Caro, 1994; Mowat et al., 1996; Fernández et al., 2002; Echols et al., 2004). Investigations of Eastern wolf pup (*Canis lycaon*) survival in Algonquin Provincial Park (APP), Ontario, were initiated in 2004 as part of a broader study examining the population dynamics of park wolves (Patterson et al., 2004). To allow for monitoring, the study

required that pups be individually marked with very-high-frequency (VHF) transmitters in early summer. In previous years, wolf pups in APP had been fitted with padded VHF radiocollars or VHF ear-tag transmitters, but these tended to fail prematurely or were removed by adults.

Early monitoring is essential for determining specific survival rates and cause-specific mortality during the summer. This is particularly important for populations that are prone to diseases, such as canine parvovirus, which can be a significant mortality factor for wolf pups less than 3 mo of age (Meunier et al., 1981; Mech and Goyal, 1993; Johnson et al., 1994; Mech and Goyal, 1995). In order to effectively monitor pups during this early juvenile period, anesthetic and

surgical techniques were developed to implant VHF transmitters in pups during the time that they could still be easily captured in their dens.

The use of implantable VHF transmitters in wildlife is increasing and has been employed principally in species where behavior and/or body morphology restrict the use of external transmitters (Green et al., 1985; Rosatte and Kelly-Ward, 1988; Koehler et al., 2001; Echols et al., 2004). It may be particularly applicable for juveniles where external attachment of transmitters is problematic due to body growth. However, only a few studies highlight the use of implantable transmitters in either canids or juvenile animals, and all of them were conducted in laboratory settings, which required that individuals be captured and transported to a surgical facility (Green et al., 1985; Rosatte and Kelly-Ward, 1988; Way et al., 2001). These techniques are not acceptable for wolf pups because it requires them to be separated from the pack for extensive periods, which might cause abandonment and subsequent pup mortality (Chapman, 1977; Mech, 1977; Laurenson and Caro, 1994; Mowat et al., 1996; Fernández et al., 2002).

Most surgical protocols in wildlife utilize combinations of injectable anesthetics with slow induction and recovery periods. This may be unacceptable for use in juveniles because of lengthened disturbance time at the den site, which would increase the risk of rejection (Thurmon et al., 1996). In addition, the levels of immobilization and relaxation achieved may not be suitable for procedures requiring abdominal surgery. Because wolf pups are usually moved to new den or rendezvous sites immediately following human disturbance (Joslin, 1967; Chapman, 1977), it is important for pups to be fully recovered from the surgical procedure before relocation. Inhalant anesthetics provide smooth and rapid induction and recovery (Mutoh et al., 1995; Johnson et al., 1998), but the standard

equipment is generally not conducive for field studies, especially where manual transportation to a remote surgical site is required. Herein, we report an effective surgical protocol for implanting peritoneal VHF transmitters in wolf pups that can be easily performed under field conditions using inhalation anesthesia.

MATERIALS AND METHODS

Wolf den sites in APP (45°N, 78°W) were located via monitoring of radiocollared adults in spring 2004 and 2005. Wolves began showing signs of affinity for den locations during the last week of April and first week of May in each year, as evidenced by localization of radiocollared adults. Dens were located by searching suspected areas on foot between 28 May and 16 June in each year, roughly 5 wk after animals appeared to localize at a suspected den site. Once the den was found, all pups were captured manually and placed individually in breathable cloth bags in which they were weighed and restrained until surgery. All pups were handled with vinyl gloves to reduce residual scent transmission throughout the handling procedures.

Transmitters (M1235, Advanced Telemetry Systems, Isanti, Minnesota, USA: 7.9-cm length \times 1.7-cm diameter, 17-mo estimated battery life [Fig. 1]; or model IMP/300M, Telonics, Inc., Mesa, Arizona, USA: 8.1-cm length \times 2.3-cm diameter, 13-mo estimated battery life) were individually packaged and previously sterilized with vaporized hydrogen peroxide (Sterrad, Advanced Sterilization Products, Irvine, California, USA). Multiple sets of basic surgical instrument and drapes were packaged individually and sterilized by autoclaving. Surgery was performed at the den site on a lightweight portable camping table, and the surgical "suite" and anesthetic apparatus were enclosed in a mosquito net suspended from a suitable tree (Fig. 2). The oxygen cylinder was affixed to the leg of the table, and the vaporizer was placed on the table. Ambient temperatures varied from 20 C to 28 C. The surgical site was placed in a shaded area to reduce the possibility of hyperthermia of the pups. The time of surgery varied from 11:30 AM to 11:00 PM, although most were carried out between 1:00 PM and 6:00 PM.

Up to 30 min prior to the surgical procedure, pups were removed individually from the bags and given an intramuscular (IM) injection of butorphanol (Torbugesic, Wyeth

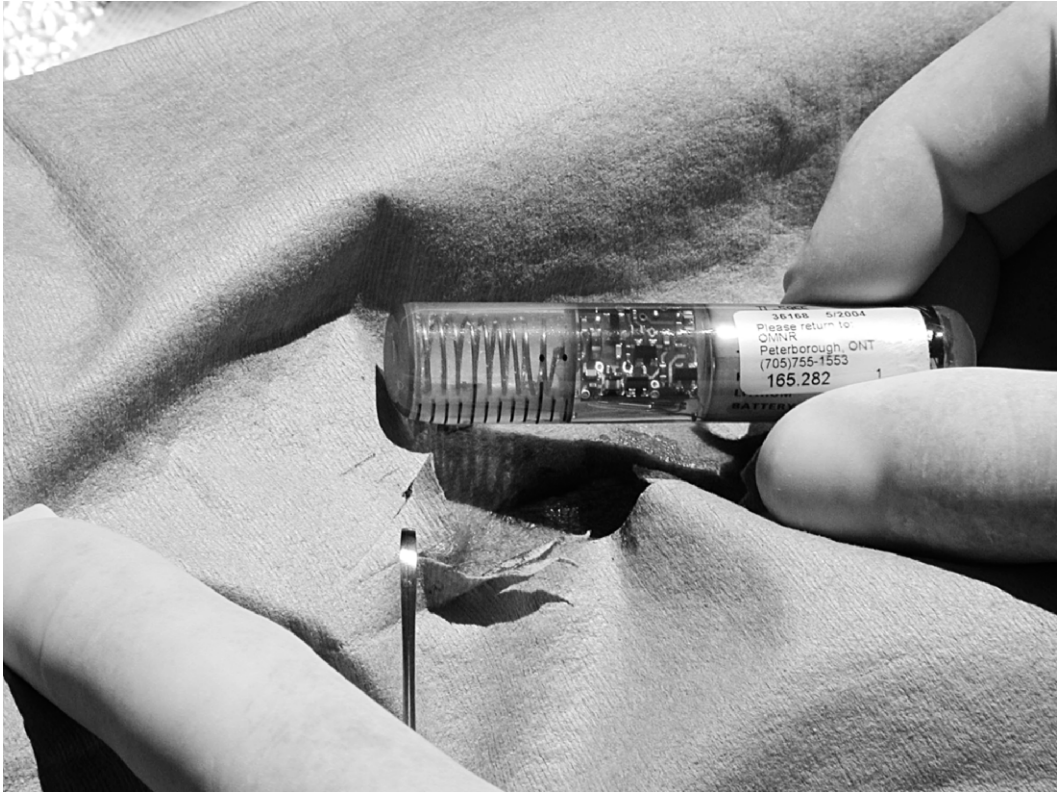

FIGURE 1. A detailed view of an intraperitoneal VHF radio transmitter (7.9-cm length \times 1.7-cm diameter; ATS, Isanti, Minnesota, USA) prior to insertion into the peritoneal cavity of a 5-wk-old wolf pup in Algonquin Provincial Park. The implant consisted of a lithium battery (right), circuit board (middle), and a coiled antenna (left) packaged in a biologically inert resin.

Animal Health, Guelph, Ontario, Canada) (0.1 mg/kg) for sedation and intra-operative analgesia. Anesthesia was then induced with 8% sevoflurane (Sevoflurane, Abbott Laboratories, St. Laurent, Quebec, Canada) in oxygen with a flow rate of 2–3 l/min via a tight-fitting anesthetic face mask. The anesthetic apparatus consisted of a precision sevoflurane vaporizer (Penlon Sigma Delta, Penlon Ltd., Abingdon, Oxon, UK), a D- or E-size aluminum oxygen cylinder, a dial-up combination regulator/flowmeter (Model 3108-L, Inovo Inc., Naples, Florida, USA), a Bain's anesthetic circuit, and a 2-m hose for waste gas. Total weight of the apparatus including the aluminum oxygen cylinder was 11.4 kg with the E-size cylinder, and just 9.7 kg with the smaller D-size cylinder.

Once the pups were relaxed and at a surgical plane of anesthesia, the sevoflurane concentration was reduced to 2–3%, and the oxygen flow was reduced to 1–2 l/min. Anesthetic depth was further adjusted based on the

assessment of reflex responses, heart rate, and respiratory rate, which were monitored continuously throughout the anesthesia. The ventral abdomen was clipped with battery operated clippers and prepared for aseptic surgery with 4% chlorhexidine surgical scrub (Vet Solutions Surgical Scrub and Handwash, Vet Solutions, Fort Worth, Texas, USA) followed by isopropyl alcohol, which was repeated once, and finally with the application of povidone iodine (Betadine, Purdue Pharma, Pickering, Ontario, Canada).

A surgical drape was then applied. A 2-cm incision was made through the skin and ventral abdominal wall ~1 cm caudal to the umbilicus, and the transmitter was placed loosely into the abdominal cavity. The abdominal wall was sutured in a simple interrupted pattern with 4/0 polydioxanone (PDS, Ethicon, Johnson and Johnson, Piscataway, New Jersey, USA) followed by subcuticular suture with the same material, and then by the external application of n-butylcyanoacrylate surgical



FIGURE 2. Surgical setup for field implantation of intraperitoneal VHF transmitters into wolf pups using sevoflurane. The setup included an oxygen cylinder with a dial-up combination regulator/flowmeter, a sevoflurane vaporizer placed on the table with a Bain's anesthetic circuit, the respective hosing, and a tight-fitting anesthetic face mask.

adhesive (VetBond, 3M, London, Ontario, Canada) to the skin wound.

Upon completion of the surgery, the vaporizer was turned off, the mask was removed

after one minute, and the pups were held during the recovery period. A transponder (PIT-tag, Avid Canada, Calgary, Alberta, Canada) was inserted subcutaneously (SC) on

the dorsal midline between the scapulas, and the wound was sealed with surgical glue.

Each pup received an injection of Meloxicam (Metacam, Boehringer, Burlington, Ontario, Canada) at 0.2–0.3 mg/kg SC for longer-lasting postsurgical analgesia, and the antibiotic cefazolin (Cefazolin, Novopharm, Toronto, Ontario, Canada) at 25 mg/kg SC for the prevention of postoperative infection. A blood sample was taken from each pup for complete blood count and pathogen serology, and hair samples were collected for genetic and nutritional studies. Implanted transmitters were not removed at the end of the study because the stress induced by capture and surgical removal of the transmitters would be excessive. In previous studies, transmitters have been left in place without any detectable complications (Davis et al., 1984; Reid et al. 1986). All protocols were approved by the Ontario Ministry of Natural Resources Wildlife Animal Care Committee and the Trent University Animal Care Committee.

We monitored implanted pups for survival via ground or aerial telemetry every 2–3 days after capture until the end of August, and weekly thereafter. The reception range of implanted transmitters was determined during normal aerial and ground monitoring and was measured in a straight line from the location where the signal was first heard to the estimated location of the transmitted pup. We determined the cause of death for each pup using evidence at the mortality site and detailed necropsies conducted by personnel from the Canadian Cooperative Wildlife Health Centre (CCWHC), University of Guelph. CCWHC personnel also investigated the peritoneal cavities of dead pups for adverse reactions (e.g., infection, peritonitis, adhesions) at the surgical site and around the implanted transmitter.

RESULTS

Twenty pups from five litters were captured and implanted in 2004, and 33 pups from eight litters were implanted in 2005. Mean age at capture for both years was 5.5 ± 1.5 wk (SD; range: 3.5–8 wk) and mean weight was 2.9 ± 1.0 kg (range: 1.45–5.1 kg). Ages, which are believed to be accurate within 0.5 wk, were based upon the timing from the date that the tracked pack permanently localized at the den site, as well as pup weight and dentition, which was compared with that of domestic dogs

of known age. All pups were easily removed from the den by hand and were calm enough to handle manually without additional restraint. Actual surgical time took 15 min, and total handling time including surgical preparation, PIT-tag injection, treatment, blood and hair sampling, and recovery was approximately 35 min. Induction of anesthesia to a surgical level with sevoflurane took just 1.5 min (range: 1–2 min). No pups showed signs of physical stress or had difficulty breathing throughout the procedure. Heart rates were in the range of 140–180 beats per min (bpm), and respiratory rates varied from 24 to 100 per min depending upon the ambient temperature. All pups were awake within 4 min of removal of the face mask and were ambulatory and able to walk back into the den within 10 min following surgery without apparent sedative effect or ataxia.

Due to initial technical problems with the oxygen cylinder, the first pup handled was anesthetized with ketamine (Vetalar, Bioniche Animal Health, Belleville, Ontario, Canada) (25 mg/kg) combined with midazolam (Versed, Hoffman-La Roche, Mississauga, Ontario, Canada) (0.25 mg/kg IM). Relaxation and anesthesia occurred within 3 min. However, the addition of butorphanol (0.1 mg/kg IM) was required to reduce response to the surgical procedure and the pup also received some sevoflurane by mask during the procedure. The other 52 pups received butorphanol and sevoflurane only for the anesthetic protocol.

There were no postoperative complications or mortalities associated with surgical procedures. No pups were abandoned after handling, and all packs returned to the den site or relocated the pups to new dens or rendezvous sites within a few hours of the team leaving the site. However, two 3.5-wk-old pups from the same litter died following capture after they were relocated by the pack to a flooded den where they subsequently drowned. Postmortem necropsies for

these two pups confirmed that there was no infection or peritonitis associated with either the surgical incision or the implanted transmitter and that fluid was present in the lungs. Ten additional pups died during the study but only five carcasses (deaths occurred 50–174 days after implants were inserted) were in a condition that allowed for detailed necropsies. For these pups, signs of infection or peritonitis related to the surgery or the implant were absent, and in one case, there were small adhesions of the bowel to itself or the body wall that were apparently unrelated to the transmitter or surgery and were easily broken down. The transmitter was found floating freely in the abdominal ($n=3$) or pelvic cavity ($n=1$) of each pup (the location of the transmitter was not noted for the fifth pup). The remaining five pups were not necropsied because the carcass had been scavenged ($n=4$) or predated ($n=1$), and the transmitter was found lying outside of the body cavity near the carcass.

Twenty-seven pups were known to be alive with functional transmitters at the end of November, approximately 6 mo after deployment (Fig. 3). Of those transmitters that were not functioning at the end of November, three malfunctioned (i.e., the transmitter entered mortality mode while the pup was still living, causing accelerated battery failure; occurrences on 28 October, 3 November, and 23 November), 11 pups died, and 12 either malfunctioned or were lost to follow-up after dispersal. Signals tended to weaken and contact was lost with most pups from the following February (8 mo after deployment) through May (12 mo after deployment). Monitoring contact was lost with all pups implanted with ATS transmitters by 21 May the following year (approximately 12 mo after deployment; $n=28$). Four of nine Telonics transmitters implanted in pups that did not die were operational >12 mo after deployment, and one lasted >20 mo. Effective reception range for aerial telemetry was

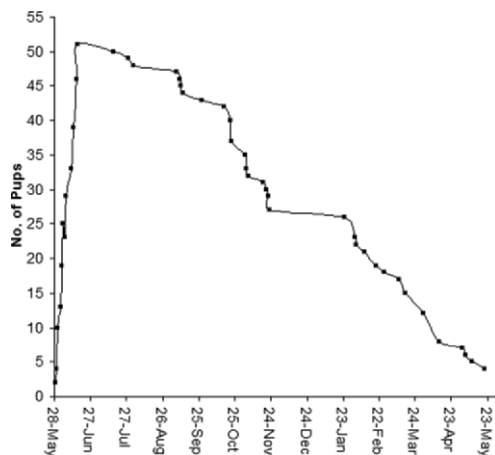


FIGURE 3. Sample size of transmitted wolf pups through the first year of deployment (2004 and 2005 field seasons combined). All captures were conducted from 29 May to 16 June. Pups were removed from the sample following loss of contact due to mortality, transmitter malfunction, transmitter battery expiration, and in some cases dispersal.

1.5–11.0 km, depending on flight altitudes, which were generally from 600–1200 m. The range for ground telemetry was approximately 0.5–2.0 km and was strongly affected by the topography between the transmitter and receiver (i.e., large hills were capable of significantly obstructing the signal).

DISCUSSION

This protocol describes a surgical procedure using inhalation anesthesia equipment that was designed to be used in remote locations. The advantages of inhalation anesthesia are the rapid and smooth induction and recovery, the high degree of controllability without the need for additional injectable anesthetic if the procedure is prolonged, and minimal residual drug effects once the anesthetic is discontinued. Sevoflurane is an inhalant anesthetic that results in shorter induction times and more rapid recoveries than the more commonly used agent, isoflurane. Inhalants produce anesthesia with dose-dependent unconsciousness and good muscle relaxation compared with the

injectable dissociative anesthetics, such as tiletamine, ketamine, or ketamine combinations. Ketamine alone provides inadequate relaxation for surgery, and anesthesia is short-lived. The addition of alpha-2 agonists, such as xylazine and medetomidine, to ketamine increases the depressant effects on cardiovascular function and causes potentially longer recovery periods. As a general rule, the administration of alpha-2 agonists to pediatric animals is not advised (Lemke, 2004). Rapid return of the pups' normal behavior without sedation or other side effects is particularly important to reduce the risk of maternal rejection or aggression and increase the chance of acceptance by siblings. Overall, this protocol was designed to minimize handling times and stress while providing high levels of anesthetic care and a surgical technique in a field situation.

The safety of the protocol was demonstrated by the fact that there were no postoperative mortalities due directly to surgical procedures, and no pups were abandoned by adults following capture. The two pups that died soon after capture drowned after the parents moved them to a flooded den. The age of these pups at the time of capture suggests that captures should be focused on pups older than 3.5 wk old, when they would be more mobile and independent (Packard, 2003). No other pup mortalities occurred within 30 days after surgery in either year. All pups ($n=5$) necropsied lacked inflammation or infection in the abdominal cavity or other adverse effects related to surgical procedures or the implanted transmitter. In addition, the transmitter was found lying freely in the peritoneal cavity in each case. Sterilization of surgical implants was absolutely critical. The use of vaporized hydrogen peroxide with delicate components provides for safe, effective, and residue-free surgical sterilization unlike liquid chemicals or other methods.

The low effective range of the transmitters hindered our ability to relocate individuals that ranged widely (Koehler

et al., 2001), such as pups that had dispersed, but it was highly effective when pups were located within their natal territory. Despite the range limitations, implanted transmitters are the only described method that can be used to effectively monitor wolves during the early juvenile period. If further monitoring is required, implanted pups could be recaptured and fitted with VHF collars in autumn to monitor survival and dispersal during the remainder of the year (Van Ballenberghe and Mech, 1975; Mech, 1977).

Inhalation anesthesia has been used successfully for field procedures and surgery in wildlife, including marmots, beavers, and pinnipeds. The anesthetic and surgical techniques employed here were safe and effective for VHF transmitter deployment in juvenile wolves in a true field setting. This protocol may also be appropriate for implanting other mammals with transmitters where injectable techniques and/or external transmitters are either undesirable or ineffective. The required anesthetic and surgical equipment was highly effective, easy to use, and could be carried in backpacks to remote locations by two or more field personnel.

ACKNOWLEDGMENTS

We thank J. McLeod and the staff of the Algonquin Animal Hospital for preparation and sterilization of the equipment, D. Smith for assistance in developing surgical protocols, A. Dame, D. McLelland, and R. Olberg for performing some of the implantations, and R. Benke for assistance with anesthesia. Primary field assistance was provided by A. Argue, J. Condon, L. Crawshaw, K. Loveless, J. Mills, M. Ouellette-D'amours, P. Shalla, S. Shalla, and numerous staff from Algonquin Provincial Park. The work was supported by grants from Algonquin Provincial Park, Algonquin Forest Authority, Friends of Algonquin, and the Ontario Ministry of Natural Resources' Wildlife Research and Development Section.

LITERATURE CITED

- BALLARD, W. B., AND J. R. DAU. 1983. Characteristics of gray wolf, *Canis lupus*, den and rendezvous

- sites in southcentral Alaska. *Canadian Field-Naturalist* 97: 299–302.
- BOYD, D. K., R. R. REAM, D. H. PLETSCHER, AND M. W. FAIRCHILD. 1993. Variation in denning and parturition dates of a wild gray wolf, *Canis lupus*, in the Rocky Mountains. *Canadian Field-Naturalist* 107: 359–360.
- CHAPMAN, R. C. 1977. The effects of human disturbance on wolves (*Canis lupus L.*). M.Sc. Thesis University of Alaska, Department of Wildlife Biology, 209 pp.
- CIUCCI, P., AND L. D. MECH. 1992. Selection of wolf dens in relation to winter territories in northeastern Minnesota. *Journal of Mammalogy* 73: 899–905.
- DAVIS, J. R., A. F. VON RECUM, D. D. SMITH, AND D. C. GUYNN, JR. 1984. Implantable telemetry in beaver. *Wildlife Society Bulletin* 12: 322–324.
- ECHOLS, K. M., M. R. VAUGHAN, AND H. D. MOLL. 2004. Evaluation of subcutaneous implants for monitoring American black bear cub survival. *Ursus* 15: 172–180.
- FERNÁNDEZ, N., F. PALOMARES, AND M. DELIBES. 2002. The use of breeding dens and kitten development in the Iberian lynx (*Lynx pardinus*). *Journal of Zoology* 258: 1–5.
- FRITTS, S. H., AND L. D. MECH. 1981. Dynamics, movements, and feeding ecology of a newly protected wolf population in northwestern Minnesota. *Wildlife Monographs* 80: 79.
- FULLER, T. K. 1989. Denning behavior of wolves in north-central Minnesota. *The American Midland Naturalist* 121: 184–188.
- GREEN, J. S., R. T. GOLIGHTLY, S. LYNDAKER LINDSEY, AND B. R. LEAMASTER. 1985. Use of radio transmitter implants in wild canids. *Great Basin Naturalist* 45: 567–570.
- JOHNSON, M. R., D. K. BOYD, AND D. H. PLETSCHER. 1994. Serologic investigations of canine parvovirus and canine distemper in relation to wolf (*Canis lupus*) pup mortalities. *Journal of Wildlife Diseases* 30: 270–273.
- JOHNSON, R., E. STRILER, D. SAWYER, AND D. BRUNSON. 1998. Comparison of isoflurane with sevoflurane for anesthesia induction and recovery in adult dogs. *American Journal of Veterinary Research* 59: 487–491.
- JOSLIN, P. W. B. 1967. Movements and home sites of timber wolves in Algonquin Park. *American Zoologist* 7: 279–288.
- KOEHLER, G. M., P. B. GRIGGS HALL, M. H. NORTON, AND D. J. PIERCE. 2001. Implant- versus collar-transmitter use on black bears. *Wildlife Society Bulletin* 29: 600–605.
- LAURENSEN, M. K., AND T. M. CARO. 1994. Monitoring the effects of non-trivial handling in free-living cheetahs. *Animal Behaviour* 47: 547–557.
- LEMKE, K. A. 2004. Perioperative use of selective alpha-2 agonists and antagonists in small animals. *Canadian Veterinary Journal* 45: 475–479.
- MECH, L. D. 1977. Productivity, mortality, and population trends of wolves in northeastern Minnesota. *Journal of Mammalogy* 58: 559–574.
- , AND S. M. GOYAL. 1993. Canine parvovirus effect on wolf population change and pup survival. *Journal of Wildlife Diseases* 29: 330–333.
- , AND ———. 1995. Effects of canine parvovirus on gray wolves in Minnesota. *Journal of Wildlife Management* 59: 565–570.
- MEUNIER, P. C., L. T. GLICKMAN, M. J. APPEL, AND S. J. SHIN. 1981. Canine parvovirus in a commercial kennel: Epidemiologic and pathologic findings. *Cornell Veterinarian* 71: 96–110.
- MOWAT, G., B. G. SLOUGH, AND S. BOUTIN. 1996. Lynx recruitment during a snowshoe hare population peak and decline in southwest Yukon. *Journal of Wildlife Management* 60: 441–452.
- MUTOH, T., R. NISHIMURA, H. KIM, S. MATSUNAGA, T. KADOSAWA, M. MOCHIZUKI, AND N. SASAKI. 1995. Rapid inhalation induction of anesthesia by halothane, enflurane, isoflurane and sevoflurane and their cardiopulmonary effects in dogs. *Journal of Veterinary Medicine and Science* 57: 1007–1013.
- PACKARD, J. M. 2003. Wolf behavior: Reproductive, social, and intelligent. In *Wolves: Behavior, conservation, and ecology*, L. D. Mech and L. Boitani (eds.). University of Chicago Press, Chicago, Illinois, USA, pp. 35–65.
- PATTERSON, B. R., N. W. S. QUINN, E. F. BECKER, AND D. B. MEIER. 2004. Estimating wolf densities in forested areas using network sampling of tracks in snow. *Wildlife Society Bulletin* 32: 938–947.
- REID, D. G., W. E. MELQUIST, J. D. WOOLINGTON, AND J. M. NOLL. 1986. Reproductive effects of intraperitoneal transmitter implants in river otters. *Journal of Wildlife Management* 50: 92–94.
- ROSATTE, R. C., AND P. M. KELLY-WARD. 1988. A surgical procedure for implanting radio transmitters in striped skunks, *Mephitis mephitis*. *The Canadian Field-Naturalist* 102: 713–715.
- THURMON, J. C., W. J. TRANQUILLI, AND G. J. BENSON. 1996. Anesthesia of wild, exotic, and laboratory animals. In *Lumb and Jones' Veterinary Anesthesia*, 3rd Edition, J. C. Thurmon, W. J. Tranquilli and G. J. Benson (eds.). Williams and Wilkins, Toronto, Ontario, pp. 713.
- VAN BALLEMBERGHE, V., AND L. D. MECH. 1975. Weights, growth, and survival of timber wolf pups in Minnesota. *Journal of Mammalogy* 56: 44–63.
- WAY, J. G., P. J. AUGER, I. M. ORTEGA, AND E. G. STRAUSS. 2001. Eastern coyote denning behavior in an anthropogenic environment. *Northeast Wildlife* 56: 18–30.

Received for publication 24 November 2006.