



SKELETAL LESIONS IN A POPULATION OF VIRGINIA OPOSSUMS (DIDELPHIS VIRGINIANA) FROM BALDWIN COUNTY, GEORGIA

Authors: Mead, Alfred J., and Patterson, David B.

Source: Journal of Wildlife Diseases, 45(2) : 325-332

Published By: Wildlife Disease Association

URL: <https://doi.org/10.7589/0090-3558-45.2.325>

BioOne Complete (complete.BioOne.org) is a full-text database of 200 subscribed and open-access titles in the biological, ecological, and environmental sciences published by nonprofit societies, associations, museums, institutions, and presses.

Your use of this PDF, the BioOne Complete website, and all posted and associated content indicates your acceptance of BioOne's Terms of Use, available at www.bioone.org/terms-of-use.

Usage of BioOne Complete content is strictly limited to personal, educational, and non - commercial use. Commercial inquiries or rights and permissions requests should be directed to the individual publisher as copyright holder.

BioOne sees sustainable scholarly publishing as an inherently collaborative enterprise connecting authors, nonprofit publishers, academic institutions, research libraries, and research funders in the common goal of maximizing access to critical research.

SKELETAL LESIONS IN A POPULATION OF VIRGINIA OPOSSUMS (*DIDELPHIS VIRGINIANA*) FROM BALDWIN COUNTY, GEORGIA

Alfred J. Mead,^{1,2} and David B. Patterson¹

¹ Department of Biological and Environmental Sciences, Georgia College & State University, Milledgeville, Georgia

² Corresponding author (email: al.mead@gcsu.edu)

ABSTRACT: Antemortem skeletal lesions were analyzed in 61 Virginia opossums (*Didelphis virginiana*) collected as roadkill from Baldwin County, Georgia, USA. As evidenced by bridging fracture calluses, misalignments, bone-surface depressions, perforations, localized superficial calluses, periosteal proliferations, and bony bridges across intervertebral disk spaces, 64% of the individuals had signs of one or more healed injuries. Within the subset of skeletons with bone lesions, 54% had healed rib fractures and 23% had scapular, 21% pelvic, 18% fibular, 18% vertebral, 13% dentary, 10% tibial, and 10% podial lesions. Bone lesions occurred most frequently in the cranial portion of the skeletons and averaged approximately four per individual. The majority of the skeletal injuries appeared to be inconsistent with those caused by falls or automobile collisions. The nature and position of the bone lesions suggested that nonfatal predator attacks, possibly from domestic dogs, may be a significant contributor to bodily injury in this species.

Key words: Bone lesions, *Didelphis virginiana*, skeletal fractures, Virginia opossum.

INTRODUCTION

Healed bone lesions serve as a persistent record of bone trauma and of some diseases. For example, macroscopic analysis of mammal skeletons can reveal antemortem fractures, indicated by a bridging fracture callus with or without angular deformity of damaged elements. Although bone abnormalities may not always indicate the specific cause of damage (Ortner and Putschar, 1981), they may provide a record of nonlethal injuries sustained by members of the population. Accordingly, large skeletal collections should allow the analysis of the frequencies of bone lesions within defined populations. Furthermore, an understanding of the frequency and nature of healed fractures in extant species is vital for the interpretation of skeletal lesions in fossil taxa.

Antemortem bone damage in nonhuman primates has been studied to facilitate an understanding of bone lesions in early human remains which, in anthropologic studies, have been used to infer conditions in both individuals and general populations (Ackerknecht, 1953). Initial studies of nonhuman primates (e.g. Duckworth, 1911) were purely descriptive and

recorded the occurrence of the natural healing of primate limb fractures. Subsequent studies have been more interpretive; they have included samples from wild populations and noted frequencies, patterns, and causes of bone lesions. For example, Schultz (1939) described bone lesions in wild primates from Asia and suggested that arboreal primates should have higher frequencies of healed fractures. In his skeletal collection of 118 wild adult gibbons (multiple species, mostly *Hylobates lar*), 36% demonstrated healed fractures. Bramblett (1967) analyzed 60 skeletons of the Darajani baboon (*Papio cynocephalus*) and concluded that the high frequency of healed fractured digits and lower limb bones was likely related to falls from trees. Buikstra (1975) analyzed the incidence of skeletal lesions in 126 rhesus macaques (*Macaca mulatta*) and concluded differently that the frequency and pattern of healed fractures does not directly correlate to the degree of arboreality. Lovell (1990) found trauma-related lesions in 19% of the skeletal remains from 31 free-ranging mountain gorillas (*Gorilla gorilla beringei*) and concluded that skeletal fractures were most likely the result of falls and intraspecific combat.

DeGusta and Milton (1998) described skeletal lesions found in 23% of their study sample and attributed the presence of healed cranial fractures to intraspecific fighting in Howler monkeys (*Alouatta palliata*) from Panama. More recently, Nakai (2003) documented a 53% incidence of skeletal lesions in wild Japanese macaques (*Macaca fuscata*) and concluded that a high frequency of clavicle, scapular, vertebral, rib, and hip fractures resulted from falls as well.

The occurrence of skeletal lesions in wild, nonprimate, mammal populations is not as well documented, which is surprising considering the frequency with which bone lesions in fossil vertebrates are used to infer aspects of paleoecology (e.g. Bjotvedt and Turner, 1977; Bjorkengren et al., 1987; Tanke and Currie, 1998; McCall et al., 2003; Farke, 2007; Farke and O'Connor, 2007). In one of the earlier studies, Fox (1939) analyzed 1,700+ skeletons of various wild mammal taxa, but limited his report to the occurrence of arthritis. Taylor (1971) found skeletal lesions in approximately 15% of 308 skeletons of African viverrids (*Atilax*, *Bdeogale*, *Civettictis*, *Genetta*, *Helogale*, *Herpestes*, *Ichneumia*, *Mungos*, and *Nandinia* spp.) collected through trapping and roadkill salvage. He reasoned that a high incidence of tibial and pedal injuries was likely related to falls in the arboreal species. In white-tailed deer (*Odocoileus virginianus*) collected from Saskatchewan, Wobeser and Runge (1975) found degenerative skeletal conditions in 20 of 128 (16%) individuals, but did not link the conditions to aspects of life history. Similarly, Peterson et al. (1982) recorded evidence of degenerative joint disease and periodontal infection in moose (*Alces alces*) populations in Alaska and Michigan. More recently, Ventura and Götzens (2005) analyzed 564 skeletons of water voles (*Arvicola terrestris monticola*) and concluded that a higher frequency of bone lesions in the thoracic region was related to intraspecific combat and a fossorial life history.

In the present study, skeletal lesions were analyzed within a population of Virginia opossums (*Didelphis virginiana* Kerr 1792) from Baldwin County, Georgia (33°5.27'N, 83°14.00'W). This species is common throughout Georgia (Golley, 1962) and, despite its abundance and relative ease of capture or collection, has been the focus of few ecologic or morphologic studies in the state (McKeever, 1958; Allen et al., 1985; Patterson and Mead, 2008). The opossum is an omnivorous small mammal (approximately 1–4 kg adult weight) found throughout the eastern half, and along the western coast, of the United States (McManus, 1974; Gardner, 1982). Besides Black (1935), who briefly commented on the evidence of healed ribs and scapulae within a sample of 95 skeletons from Kansas, published studies of bone lesions in opossums are lacking. Allen (1901) and Lowrance (1949) mentioned the occurrence of supernumerary teeth in the species, and Fox (1939) reported no evidence of arthritis in the 24 opossums in his sample. Extensive ecologic studies of opossums have been completed throughout its range including Texas (Lay, 1942), Missouri (Reynolds, 1945), Iowa (Wiseman and Hendrickson, 1950), Kansas (Fitch and Sandidge, 1953), New York (Hamilton, 1958), Maryland (Llewellyn and Dale, 1964), Illinois (Holmes and Sanderson, 1965), Virginia (Stout and Sonenshine, 1974), Pennsylvania (Blumenthal and Kirkland, 1976), Wisconsin (Gillette, 1980), and Florida (Ryser, 1995). Only Lay (1942) and Fitch and Sandidge (1953) reported that live opossums commonly had physical injuries including broken legs, tails, and teeth. Reynolds (1945), Wiseman and Hendrickson (1950), Hamilton (1958), McManus (1969), and Blumenthal and Kirkland (1976) reported soft-tissue damage and distal caudal vertebrae loss due to frostbite. Hamilton (1958) also indicated distal caudal vertebrae loss due to self-mutilation. However, no corresponding analyses of skeletal lesions were performed in these studies.

TABLE 1. Summary of the observed skeletal lesions in the Baldwin County, Georgia, population of the Virginia opossum (*Didelphis virginiana*). Bridging calluses and bone misalignments indicated healed fractures. Visible bone surface depressions and perforations indicated bone punctures. Periosteal proliferations were recorded as general bone damage. Bony bridges across intervertebral disk spaces indicated vertebral fusion. GCM = Georgia College Mammal Collection. F = female, M = male.

GCM	Sex	Observed skeletal lesions
2367	?	Fractured ribs (2)
2389	?	Fractured ribs (2)
2329	F	Punctured left scapula; fractured right ilium; superficial callus left ilium
2331	F	Fused caudal vertebrae (2)
2347	F	Fractured left ulna
2361	F	Right dentary eroded posterior to m3
2368	F	Superficial callus right dentary
2376	F	Fused cervical vertebrae (2); superficial callus thoracic vertebra (1); fractured ribs (2)
2385	F	Fractured right pubis; superficial callus left acetabulum
2330	M	Fractured left fibula
2335	M	Fractured ribs (2)
2336	M	Calcified nasal rugosity; fractured right ilium; superficial callus right acetabulum
2338	M	Fractured right tibia and fibula; fractured ribs (6)
2339	M	Fractured rib (1)
2340	M	Superficial callus right scapula; fractured ribs (3)
2341	M	Fractured left fibula; fractured left ischium and pubis; fractured ribs (5)
2342	M	Superficial callus left acetabulum
2343	M	Fractured right and left ischia; superficial callus left and right acetabula
2348	M	Fractured rib (1)
2349	M	Fractured left tibia and fibula
2350	M	Fractured left scapula
2352	M	Fractured right ilium; fractured left ischium and pubis; bone proliferation on left epipubic; fractured right fibula; fractured metapodial; fractured rib (1)
2354	M	Fractured left scapular spine
2355	M	Fractured right ulna; fractured right fibula; fractured ribs (3)
2356	M	Bone proliferation on left tibia, fibula and tarsals; fractured right proximal phalanx 1; fractured ribs (5)
2357	M	Fractured right proximal metacarpal 1
2363	M	Superficial callus right dentary; bone proliferation on right radius, ulna, and carpals; fused thoracic vertebrae (4); fractured ribs (10)
2365	M	Fractured right dentary; superficial callus left scapula; fractured ribs (3)
2366	M	Fractured left pubis; superficial callus left acetabulum; decalcified thoracic vertebrae (4); fractured rib (1)
2370	M	Fractured right scapular spine; fractured ribs (3)
2373	M	Fractured right femur
2374	M	Fused caudal vertebrae (4); fractured ribs (5)
2379	M	Superficial callus right femur; enlarged, deformed epipubic
2380	M	Fused thoracic vertebrae (2); superficial callus lumbar vertebra (1); fractured ribs (2)
2381	M	Premaxilla perforated at right I1 root; punctured left scapula; fused lumbar vertebrae (2); fractured ribs (3)
2383	M	Fractured rib (1)
2386	M	Superficial callus right dentary; fractured right scapular spine; fractured ribs (8)
2387	M	Fractured left scapula
2388	M	Premaxilla perforated at left I2 root; fractured right tibia

MATERIALS AND METHODS

Sixty-one opossums (47 males, 12 females, two sex undetermined) were collected during 2002 and 2004 as roadkill in Baldwin County, Georgia, located along the southern edge of the Piedmont Physiographic Province (Patterson and Mead,

2008). The sex of each individual was recorded at the time of collection. All individuals were considered adults (10+ mo, age classes 5 and 6 of Gardner, 1973) based on molar eruption (Petrides, 1949). No flattened specimens were included in the analysis. Each specimen was analyzed macroscopically for evidence of skele-

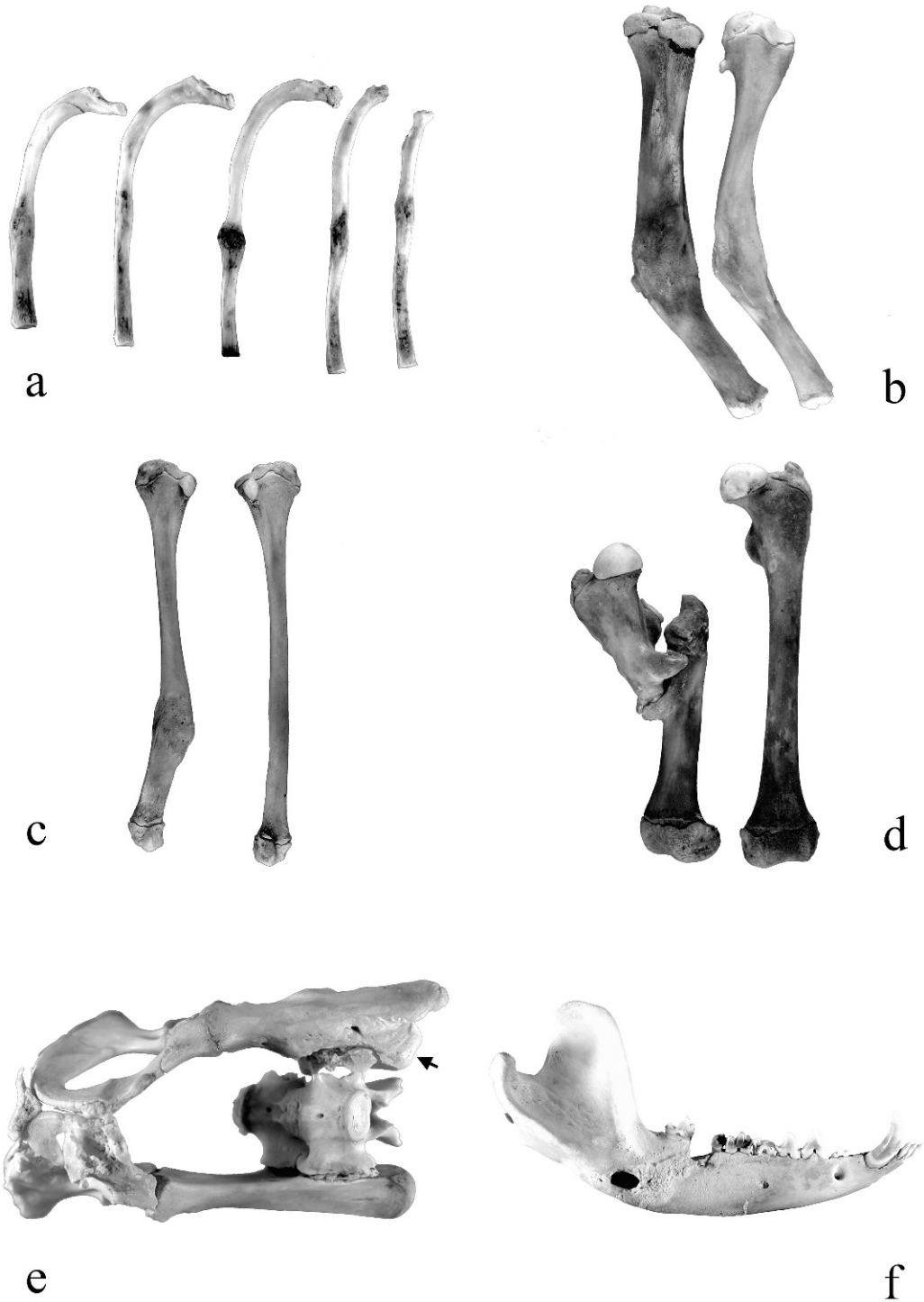


FIGURE 1. Observed skeletal lesions in the Baldwin County, Georgia population of the Virginia opossum (*Didelphis virginiana*): a) bridging fracture calluses evident on multiple ribs from GCM 2338, average rib length approximately 6.5 cm; b) fracture calluses and misalignments on the left tibia and fibula from GCM 2349, tibia length approximately 8.0 cm; c) bridging fracture callus on the right fibula of GCM 2352,

tal lesions. Due to the high frequency of bone breakage occurring at the time of death, only skeletal injuries that clearly had signs of healing were recorded. As proposed by Ortner and Putschar (1981), bridging calluses and bone misalignments were interpreted as indications of healed fractures. Visible bone surface depressions and perforations were interpreted as bone punctures. Periosteal proliferations were recorded as general bone damage. Vertebral fusion was indicated by bony bridges across intervertebral disk areas (ankylosis).

In addition to bone lesions, each skeleton was examined for fresh bone breakage. In instances where the skull was shattered, the minimum number of breaks was recorded as one-half of the number of skull pieces identified. The number of rib fragments with only one broken end was also halved. Rib fragments with two broken ends, and each fracture on scapulae, pelvises, and limb bones, were recorded as single breaks.

References to the cranial portion of the skeleton refer to all bones, including ribs, cranial to the first lumbar vertebra. The caudal portion of the skeleton refers to all bones caudal to the last thoracic vertebra. All skeletons are housed in the Georgia College and State University Recent Mammal Collection (GCM).

RESULTS

The observed skeletal lesions for the Baldwin County population of opossums are described in Table 1. Sixty-four percent of the individuals (30/47 males [64%], 7/12 females [58%], 2/2 sex undetermined [100%]) had evidence of one or more healed injuries. Within the group with bone lesions, most individuals had healed ribs (54%) followed by scapulae (23%), pelvises (21%), fibulae (18%), vertebrae (18%), dentaries (13%), tibiae (10%), podials (10%), ulnae (8%), and femora (5%). Lesions in other parts of the skeleton occurred in <5% of the animals. The number of skeletal lesions per animal

was variable: 41% had only one, 21% two, 8% three, and 31% had four or more. The position of skeletal damage also varied: 51% had cranial damage only, 23% had caudal damage only, and 26% had both cranial and caudal damage. The average number of fresh breaks was approximately 19 per skeleton.

Ribs: The number of healed broken ribs per individual varied from one to ten. Fractures were indicated by bridging calluses and were most often located mid-shaft (58%) and proximally (36%) along the rib shaft. GCM 2338 had six ribs fractured at approximately the same position along the shaft (Fig. 1a).

Scapulae: Scapulae had damage indicating broken scapular spines, fractured scapular blades, and punctured scapular blades. GCM 2350 had the most severe scapular damage with complete mid-shaft scapular blade fracture, overlapping misalignment, and excessive fracture callus.

Longbones: Fibulae were the most-commonly observed damaged longbones. Fibulae had bridging calluses and misalignments both with (Fig. 1b) and without (Fig. 1c) corresponding damage to the associated tibia. Only one damaged tibia was not associated with a damaged corresponding fibula. The two fractured ulnae were not associated with damaged corresponding radii. Extreme femoral damage in GCM 2373 included femoral fracture with displacement, 45° mesial misalignment, bony spurs, and fracture callus (Fig. 1d). No humeral lesions were observed.

Pelvises: Damaged pelvises were identified by bridging calluses at fracture sites on the

←

uninjured left fibula for comparison, length approximately 8.0 cm; d) excessive fracture callus and misalignment of the right femur from GCM 2373, uninjured left femur for comparison, length approximately 8.0 cm; e) fracture calluses on the left ischium and pubis, and fracture callus and misalignment of the right ilium from GCM 2352 (ventral view); note proper position (arrow) of the right iliac crest, mesial to anteriorly displaced bone, length approximately 7.5 cm; f) fracture callus, tooth loss, and misalignment of the right dentary from GCM 2365, length approximately 10 cm.

pubes, ischia, and ilia. Superficial callus on the acetabular suture was associated with most fractures. A severely damaged pelvis was observed in GCM 2352 (Fig. 1e). In this specimen, the right ilium was fractured near the midpoint of the bone, displaced cranially approximately 1.5 cm, misaligned, and secured with bridging callus. The right iliac crest remained attached in the proper position at the sacrum. The left pubis and ischium were fractured and the left epipubic was rotated caudally.

Vertebrae: Fusion of cervical, thoracic, lumbar, and caudal vertebrae was observed. The majority of the damaged vertebrae displayed bony bridges (ankylosis) across the intervertebral disk areas.

Dentaries: Damaged dentaries had superficial calluses, bone erosion, and bridging calluses. The most severely damaged dentary, the right ramus of GCM 2365, had bridging fracture callus, bone erosion, misalignment, and tooth loss (Fig. 1f).

Podials: Damage to the fore- and hindfeet was indicated by bridging fracture calluses and osteophytes. Bone proliferation around the right carpus of GCM 2363 and the left tarsus of GCM 2356 was extensive and limited the range of motion.

DISCUSSION

The high frequency of bone lesions found indicates that skeletal fractures are common and implies that opossums often survive traumatic injury. The Baldwin County sample of opossums exhibited a 25% higher incidence of healed damage when compared to the opossum population from near Lawrence, Kansas (Black, 1935). However, the two populations showed similar frequencies for healed ribs (54% in both samples) and scapulae (23% in Georgia and 31% in Kansas). The incidence of healed injuries in opossums is comparable to that observed in the Japanese macaques (Nakai, 2003). Yet, when compared to the other nonhuman

primates, viverrids, and water voles analyzed in previous studies, the Baldwin County opossums had a considerably greater frequency of healed fractures.

Nakai (2003) suggested that a high frequency of damage to the anterior portion of the skeleton indicated falls for arboreal primate species. Bramblett (1967) and Taylor (1971) reasoned that a high incidence of lower-limb bone and pedal injuries suggested falls in arboreal baboons and viverrids, respectively. The high frequency of rib and scapular damage in opossums is congruent with falls; however, the relative lack of radial, tibial, and pedal injuries does not support this conclusion. In addition, discussions of opossum life history and ecology do not mention falls as commonly observed phenomena (McManus, 1970; Gardner, 1982). Hamilton (1958) indicated that opossums do not spend a high percentage of their time in trees and generally climb only to obtain fruit and avoid predators.

Gardner (1982) listed automobile collisions as the primary cause of mortality for opossums. Hamilton (1958) found opossums to be the most common road-killed predators in New York, with more males than females being hit during the reproductive season. Caro et al. (2000) reported opossums as the third most common road-killed species along rural and suburban roads in Yolo County, California. Taylor (1971) reasoned that multiple fractures of the pelvis in the white-tailed mongoose resulted from automobile strikes to the hindquarters. The Baldwin County opossums with severe damage to the posterior portion of the skeleton may have survived an automobile collision. However, all of the specimens in the study were collected as roadkill and generally had far more death-related bone fractures than antemortem skeletal lesions (19 versus 4 per skeleton, respectively). Even though no flattened specimens were used in this study, the possibility exists that some of the individuals were hit more than once. Adult opossums exhibit head and body

lengths of approximately 40 cm, and automobile tires are generally greater than 20 cm wide. It is difficult to imagine how a tire hit would break one or two ribs without severely damaging other parts of the skeleton. If contact with the vehicle's undercarriage occurred, damage to the dorsal portions of the skeleton would be expected. However, over half of the rib fracture lesions are midshaft, not proximally (dorsally), positioned.

Gardner (1982) concluded that the domestic dog is the primary predator of opossums in suburban areas, and its close presence or attack often elicits opossum death-feigning (Gardner, 1982). Citing broken ribs and scapulae, Keefe (1967) concluded that "playing opossum" made opossums susceptible to injuries when mauled by dogs. General observations indicate that many domestic dog attacks do not result in the consumption of the prey. Opossums can maintain their catatonic state for several hours and, once the dog loses interest in its "kill," may escape to safety with nonfatal injuries. The high frequency of mid-shaft rib fractures, fractured scapular spines, and punctured scapular blades in the Baldwin County opossums appears consistent with damage caused by bites to the trunk.

The bone lesions documented in this sample of Baldwin County opossums serve as a record of nonfatal bone trauma. The nature and position of the bone lesions suggest that opossums may sustain substantial injuries while death-feigning during a predator attack. The high frequency of bone lesions indicates that the ability to survive severe injury is not uncommon in this species and may serve as a reference for similar studies of bone lesions in extant small mammals and fossil taxa.

ACKNOWLEDGMENTS

We thank the students enrolled in the 2002 and 2004 mammalogy classes at Georgia College and State University for their work in collecting and processing the roadkill opossum carcasses. We appreciate the valuable comments provided by Heidi Mead, Dennis Parmley, and Bill Wall who read

earlier drafts of this manuscript. Bob Chandler kindly lent his photographic expertise. We thank Elizabeth Howerth and two anonymous reviewers for their insightful comments.

LITERATURE CITED

- ACKERKNECHT, E. H. 1953. Paleopathology. In *Anthropology today: An encyclopedic inventory*, A. L. Kroeber (ed.). University of Chicago Press, Chicago, Illinois, pp. 120–126.
- ALLEN, C. H., R. L. MARCHINTON, AND W. M. LENTZ. 1985. Movement, habitat use and denning of opossums in the Georgia Piedmont. *American Midland Naturalist* 113: 408–412.
- ALLEN, J. A. 1901. A preliminary study of the North American opossums of the genus *Didelphis*. *Bulletin of the American Museum of Natural History* 14: 149–192.
- BJORKENGREN, A. G., D. J. SARTORIS, S. SHERMIS, AND D. RESNICK. 1987. Patterns of paravertebral ossification in the prehistoric saber-toothed cat. *American Journal of Roentgenology* 148: 779–782.
- BJOTVEDT, G., AND C. G. TURNER. 1977. Mandibular lesions of prehistoric Aleutian sea mammals. *Journal of Wildlife Diseases* 13: 360–365.
- BLACK, J. D. 1935. Vitality of the Virginia opossum as exhibited in the skeleton. *Journal of Mammalogy* 16: 223.
- BLUMENTHAL, E. M., AND G. L. KIRKLAND, JR. 1976. The biology of the opossum, *Didelphis virginiana*, in southcentral Pennsylvania. *Proceedings of the Pennsylvania Academy of Science* 50: 81–85.
- BRAMBLETT, C. A. 1967. Pathology in the Darajani baboon. *American Journal of Physical Anthropology* 26: 331–340.
- BUIKSTRA, J. E. 1975. Healed fractures in *Macaca mulatta*: Age, sex, and symmetry. *Folia Primatologica* 23: 140–148.
- CARO, T. M., J. A. SHARGEL, AND C. J. STONER. 2000. Frequency of medium-sized mammal road kills in an agricultural landscape in California. *American Midland Naturalist* 144: 62–69.
- DEGUSTA, D., AND K. MILTON. 1998. Skeletal pathologies in a population of *Alouatta palliata*: Behavioral, ecological, and evolutionary implications. *International Journal of Primatology* 19: 615–650.
- DUCKWORTH, W. L. H. 1911. On the natural repair of fractures, as seen in the skeletons of anthropoid apes. *Journal of Anatomy and Physiology* 46: 81–85.
- FARKE, A. A. 2007. Reexamination of paleopathology in plesiosaurs and implications for behavioral interpretations. *Journal of Vertebrate Paleontology* 27: 724–726.
- , AND P. M. O'CONNOR. 2007. Pathology in *Majungasaurus crenatissimus* (Theropoda: Abe-

- lisauridae) from the Late Cretaceous of Madagascar. *Journal of Vertebrate Paleontology*, Memoir 8: 180–184.
- FITCH, H. S., AND L. L. SANDIDGE. 1953. Ecology of the opossum on a natural area in northeastern Kansas. University of Kansas Publications, Museum of Natural History 7: 305–338.
- FOX, H. 1939. Chronic arthritis in wild mammals. *Transactions of the American Philosophical Society* 31: 73–124.
- GARDNER, A. L. 1973. The systematics of the genus *Didelphis* (Marsupialia: Didelphidae) in North and Middle America. Special Publications 4, The Museum, Texas Tech University, Lubbock, Texas, 81 pp.
- . 1982. Virginia opossum: *Didelphis virginiana*. In *Wild mammals of North America: Biology, management, and economics*, J. A. Chapman and G. A. Feldhamer (eds.). John Hopkins University Press, Baltimore, Maryland, pp. 3–36.
- GILLETTE, L. N. 1980. Movement patterns of radio-tagged opossums in Wisconsin. *American Midland Naturalist* 104: 1–12.
- GOLLEY, F. B. 1962. *Mammals of Georgia: A study of their distribution and functional role in the ecosystem*. University of Georgia Press, Athens, Georgia, 218 pp.
- HAMILTON, W. J. JR. 1958. Life history and economic relations of the opossum (*Didelphis marsupialis virginiana*) in New York State. *Memoirs Cornell University Agricultural Experimental Station* 354: 1–48.
- HOLMES, A. C. V., AND G. C. SANDERSON. 1965. Populations and movement of opossums in east-central Illinois. *Journal of Wildlife Management* 29: 287–295.
- KEEFE, J. F. 1967. *The world of the opossum*. J. B. Lippincott Co., Philadelphia, Pennsylvania, 144 pp.
- LAY, D. W. 1942. Ecology of the opossum in eastern Texas. *Journal of Mammalogy* 23: 147–159.
- LLEWELLYN, L. M., AND F. H. DALE. 1964. Notes on the ecology of the opossum in Maryland. *Journal of Mammalogy* 45: 113–122.
- LOVELL, N. C. 1990. Skeletal and dental pathology of free-ranging mountain gorillas. *American Journal of Physical Anthropology* 81: 399–412.
- LOWRANCE, E. W. 1949. Variability and growth of the opossum skeleton. *Journal of Morphology* 85: 569–593.
- MCCALL, S., V. NAPLES, AND L. MARTIN. 2003. Assessing behavior in extinct animals: Was *Smilodon* social? *Brain, Behavior and Evolution* 61: 159–164.
- MCKEEVER, S. 1958. Reproduction in the opossum in southwestern Georgia and northwestern Florida. *Journal of Wildlife Management* 22: 303.
- MCMANUS, J. J. 1969. Temperature regulation in the opossum, *Didelphis marsupialis virginiana*. *Journal of Mammalogy* 50: 550–558.
- . 1970. Behavior of captive opossums, *Didelphis marsupialis virginiana*. *American Midland Naturalist* 84: 144–169.
- . 1974. *Didelphis virginiana*. *Mammalian Species* 40: 1–6.
- NAKAI, M. 2003. Bone and joint disorders in wild Japanese macaques from Nagano Prefecture, Japan. *International Journal of Primatology* 24: 179–195.
- ORTNER, D. J., AND W. G. J. PUTSCHAR. 1981. Identification of pathological conditions in human skeletal remains. *Smithsonian Contributions to Anthropology* 28: 1–479.
- PATTERSON, D. B., AND A. J. MEAD. 2008. Osteological variation within the Baldwin County, Georgia, population of *Didelphis virginiana*. *Southeastern Naturalist* 7: 125–134.
- PETERSON, R. O., J. M. SCHEIDLER, AND P. W. STEPHENS. 1982. Selected skeletal morphology and pathology of moose from the Kenai Peninsula, Alaska, and Isle Royale, Michigan. *Canadian Journal of Zoology* 60: 2812–2817.
- PETRIDES, G. A. 1949. Sex and age determination in the opossum. *Journal of Mammalogy* 30: 364–378.
- REYNOLDS, H. C. 1945. Some aspects of the life history and ecology of the opossum in central Missouri. *Journal of Mammalogy* 26: 361–379.
- RYSER, J. T. 1995. Activity, movement and home range of Virginia opossum (*Didelphis virginiana*) in Florida. *Bulletin of the Florida Museum of Natural History* 38: 177–194.
- SCHULTZ, A. H. 1939. Notes on diseases and healed fractures of wild apes and their bearing on the antiquity of pathological conditions in man. *Bulletin of the History of Medicine* 12: 571–582.
- STOUT, I. J., AND D. E. SONENSHINE. 1974. Ecology of an opossum population in Virginia, 1963–69. *Acta Theriologica* 19: 235–245.
- TANKE, D. H., AND P. J. CURRIE. 1998. Head-biting behavior in theropod dinosaurs: Paleopathological evidence. *GAIA* No. 15: 167–184.
- TAYLOR, M. E. 1971. Bone diseases and fractures in East African Viverridae. *Canadian Journal of Zoology* 49: 1035–1042.
- VENTURA, J., AND V. GÖTZENS. 2005. Prevalence of anomalies in the appendicular skeleton of a fossorial rodent population. *Journal of Wildlife Diseases* 41: 728–734.
- WISEMAN, G. L., AND G. O. HENDRICKSON. 1950. Notes on the live history and ecology of the opossum in southeast Iowa. *Journal of Mammalogy* 31: 331–337.
- WOBESER, G., AND W. RUNGE. 1975. Arthropathy in white-tailed deer and a moose. *Journal of Wildlife Diseases* 11: 116–121.

Received for publication 21 May 2008.