

## **INCLUSION BODY HEPATITIS IN A PRAIRIE FALCON**

Authors: WARD, F. PRESCOTT, FAIRCHILD, DAVID G., and VUICICH, JEANNE V.

Source: Journal of Wildlife Diseases, 7(2) : 120-124

Published By: Wildlife Disease Association

URL: <https://doi.org/10.7589/0090-3558-7.2.120>

---

BioOne Complete ([complete.BioOne.org](https://complete.BioOne.org)) is a full-text database of 200 subscribed and open-access titles in the biological, ecological, and environmental sciences published by nonprofit societies, associations, museums, institutions, and presses.

Your use of this PDF, the BioOne Complete website, and all posted and associated content indicates your acceptance of BioOne's Terms of Use, available at [www.bioone.org/terms-of-use](https://www.bioone.org/terms-of-use).

Usage of BioOne Complete content is strictly limited to personal, educational, and non - commercial use. Commercial inquiries or rights and permissions requests should be directed to the individual publisher as copyright holder.

---

BioOne sees sustainable scholarly publishing as an inherently collaborative enterprise connecting authors, nonprofit publishers, academic institutions, research libraries, and research funders in the common goal of maximizing access to critical research.

## INCLUSION BODY HEPATITIS IN A PRAIRIE FALCON

F. PRESCOTT WARD, DAVID G. FAIRCHILD, and JEANNE V. VUICICH

Veterinary Medicine Department, Medical Research Laboratory, Edgewood Arsenal, Maryland 21010

**Abstract:** Intranuclear inclusion bodies, typical of the developmental stages of herpesvirus inclusions, were observed in cells of the liver, spleen, bone marrow, and small intestine from a prairie falcon (*Falco mexicanus*). Inoculations of a suspension of liver tissue produced lesions on the chorioallantoic membranes of 12-day old chicken embryos. Three sparrow hawks (*Falco sparverius*) were fatally infected by intramuscular or crop inoculations of suspensions of prairie falcon liver or chorioallantoic membrane.

A male prairie falcon, about 10 days old, was taken from an eyrie in late May 1970, and was raised in a South Dakota home for 4 weeks. A new owner then took the falcon to southeastern Pennsylvania.

The second owner and a friend had two prairie falcon nest mates succumb the preceding year to pulmonary aspergillosis.<sup>1\*</sup> This new bird was therefore treated prophylactically with the antifungal drug amphotericin-B\*. One ml of a solution (5 mg/ml) of the drug was administered as an aerosol for 10-15 minutes daily, and the falcon inhaled the mist inside a plastic-lined box. Pigeon meat was the primary item in the diet.

About 2 weeks after it was moved to Pennsylvania, the bird suddenly became ill. It regurgitated a meal, then refused food and became listless. About 36 hours after the onset of these signs the falcon was presented for examination.

It was depressed, shivered occasionally, and slept intermittently. No parasite ova were seen when a fecal specimen was examined microscopically, and a mouth swab did not contain trichomonads. The lungs appeared normal on a radiograph of the thorax and abdomen, but the liver seemed to be enlarged. An intramuscular injection of chloramphenicol\*\* was given (50 mg/kg), but the falcon died within a few hours. It was necropsied immediately.

The most striking finding at necropsy was the enlarged liver studded with yellow lesions (Figure 1). These foci were randomly distributed throughout the liver parenchyma, and varied from 0.5 to 1.0 mm in diameter. Similar but fewer lesions were also found in the spleen and bone marrow. Other organs appeared normal.

### MATERIALS AND METHODS

The liver was cultured on Sabouraud's dextrose agar, on salmonella-shigella agar, and on trypticase soy agar with 5% sheep's blood added. Representative tissues from most organs were fixed in 10% neutral buffered formalin, sectioned at 6 $\mu$ , and stained with hematoxylin and eosin. Additional sections of liver were stained using the nucleal Feulgen technique.

A portion of the prairie falcon's liver was frozen at -70° F for 3 months. Approximately 0.5 gram of liver was then ground with sand and 2.5 ml saline. Antibiotics were added to the following final concentrations: 100 Units/ml penicillin; 100 mcg/ml streptomycin; and 0.25 mcg/ml amphotericin-B. The mixture was centrifuged at 2,500 rpm for 15 minutes, and the supernatant fluid was used for inoculation.

\*Fungizone Intravenous; E. R. Squibb & Sons, Incorporated, New York, New York.

\*\*Chloromycetin Sodium Succinate Parke, Davis & Company, Detroit, Michigan.



FIGURE 1. Photograph of the liver of a juvenile male prairie falcon with inclusion body hepatitis. Disseminated necrotic foci appear as pale dots on the surface of the liver.

Chicken embryos (12-days old) were inoculated on the chorioallantoic membrane (CAM) with either 0.2 ml of supernatant (6 eggs) or 0.2 ml of a 10-fold dilution of the supernatant (8 eggs). One egg was inoculated with saline and another was not inoculated. When growth was obtained in the infected eggs (after 5 days at 37 C), a similar inoculum was prepared with saline and antibiotics from the CAM.

Four wild sparrow hawks were captured. One was inoculated in the pectoral muscle with 0.05 ml of liver suspension; it was released in a large room, and was fed mice daily. Later, an uninoculated hawk was released into the room. The third hawk was inoculated with 0.05 ml of liver suspension into the crop, and the fourth with 0.1 ml of CAM suspension injected into the pectoral muscle.

Tissues from all infected eggs and all infected hawks were fixed, sectioned, and stained with hematoxylin and eosin as described for histopathologic examination.

## RESULTS

No growth was obtained on any of the media on which the liver was cultured.

Lesions were observed microscopically in sections of prairie falcon liver, spleen,

and bone marrow, and occasionally in the lamina propria of the small intestine. Foci of coagulation necrosis in these tissues contained few residual parenchymal cells and small numbers of infiltrating inflammatory cells. Numerous intranuclear inclusion bodies were seen in parenchymal cells surrounding the necrotic tissue.

Many affected nuclei contained pale, slightly granular, acidophilic bodies that were separated from marginated nuclear chromatin by a space or halo (Figure 2). These resembled the "type A" inclusions described by Cowdry.<sup>5</sup> Other nuclear inclusions were basophilic and homogeneous. They filled the nucleus, were surrounded by marginated nuclear chromatin, and resembled Cowdry's "type B" inclusions (Figure 3).

When sections of liver tissue were stained by the nucleal Feulgen technique, the type B inclusions stained less intensely for DNA than did the type A bodies.

All chicken embryos that were inoculated with prairie falcon liver suspension had gross lesions on the CAM when sacrificed after 5 days. The CAM were cloudy and thickened, with white areas scattered over the membranes. Infected embryos were smaller than the controls; many tissues contained large areas of hemorrhage and appeared to be edema-

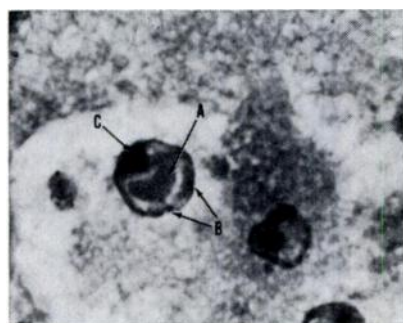


Figure 2

FIGURE 2. A Cowdry type A inclusion body in the nucleus of an hepatocyte. The inclusion body (A) is separated from marginated nuclear chromatin (B) and nucleolus (C) by a clear zone or halo.

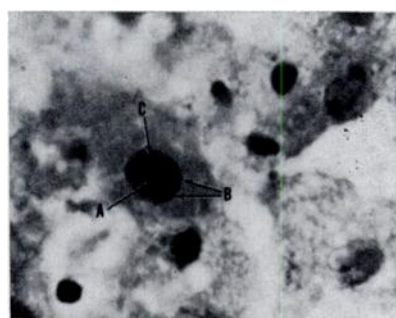


Figure 3

FIGURE 3. A Cowdry type B inclusion body in the nucleus of an hepatocyte. The inclusion body (A) fills the nucleus and is in contact with the marginated nuclear chromatin (B) and nucleolus (C).

tous. Microscopically the infected embryos were edematous and contained focal or diffuse areas of hemorrhage and necrosis in most tissues. The CAM were also edematous, hemorrhagic, and necrotic. Numerous intranuclear inclusion bodies were observed in cells in and around the necrotic tissues.

The first sparrow hawk, inoculated intramuscularly with liver suspension, died suddenly less than 5 days later. At necropsy the liver appeared slightly enlarged, but there were no circumscribed necrotic foci as in the prairie falcon. Large areas on the surface of the liver were slightly yellow. Other organs appeared grossly normal. Microscopically, hepatic necrosis was massive with numerous type A and type B intranuclear inclusion bodies; lesions were not seen in other organs (the spleen was not sectioned).

The third sparrow hawk, inoculated in the crop with liver suspension several weeks later, died suddenly 6 days following inoculation. Typical inclusion bodies were seen in cells of the liver and spleen.

Later another male sparrow hawk was inoculated intramuscularly with CAM suspension, and it died within 4 days. Again typical lesions were seen in the liver and spleen. Eight additional chicken embryos were inoculated with a suspension of this hawk's liver tissue, and all developed typical lesions on the CAM and in tissues of the embryos after 5 days' incubation.

These transmission experiments were conducted during a period of 6 weeks; the hawk that was not inoculated was released into the room one day after the first hawk died. It remained healthy while inhabiting the same room and sharing the same perches with the last two fatally infected hawks.

## DISCUSSION

Inclusion bodies are a common feature of viral diseases, but may also have non-viral etiologies.<sup>15</sup> The production of CAM lesions and the transmissibility of this disease to other hawks support the diagnosis of a viral etiology. In addition, the morphology and staining characteristics

of the inclusion bodies are identical to those of developmental stages of inclusions caused by herpesviruses;<sup>6</sup> here the type B is an early stage which later shrinks to cause the "halo", becomes Feulgen negative and eosinophilic, and is then designated as type A.

Although this disease has never before been reported in falconiform birds, an identical syndrome has been described several times in owls. Green and Shillinger<sup>8</sup> reported a virus disease from a great horned owl (*Bubo virginianus*) found dead in the wild; they then experimentally transmitted the disease to other species of owls.

Recently Burtscher published a series of articles describing an identical disease in owls which he named hepatosplenitis infectiosa strigum.<sup>1,2</sup> He demonstrated a virus by electron microscopy in various organs of an infected owl and in tissues of inoculated chicken embryos.<sup>4</sup> He also described methods of cultivating the owl virus in chicken embryos, and attempted unsuccessfully to infect several other species of birds.<sup>3</sup> Burtscher stated that the virus probably belongs to the herpesvirus group, and appears to be specific for owls.

Similar acute, hepatic, inclusion body diseases have been reported from a wide variety of birds and animals including chickens,<sup>10,12</sup> chinchillas,<sup>6</sup> parrots,<sup>7</sup> and pigeons.<sup>13,14</sup> Wild prairie falcons prey on many species of birds and animals, and interspecific transmission is possible.

The potential of this virus to cause disease in wild populations of raptors seems to be great; results of subsequent studies on host range and mode of infection would permit more definitive conclusions. However, there may be a more significant danger to captive birds of prey. Because many raptor populations have experienced unprecedented declines since the late 1940's,<sup>11</sup> several federal agencies and private institutions have initiated captive breeding programs for endangered species of birds of prey. We believe that in programs such as these, where perhaps the only surviving members of a species are aggregated for a final attempt to preserve the species, an epidemic of inclusion body hepatitis could be devastating.

**Acknowledgements**

We are grateful to Dr. D. O. Trainer, Department of Veterinary Science, University of Wisconsin for his generous advice, and to Mr. James E. Roelle and Mr. Roy S. Slack for trapping the experimental kestrels.

**LITERATURE CITED**

1. BURTSCHER, H. 1965. Die virusbedingte Hepatosplenitis infectiosa strigorum. I. Mitteilung: Morphologische Untersuchungen. Path. vet. 2: 227-255.
2. BURTSCHER, H. 1965. Viral inclusion body hepatitis and splenitis in owls. Zentbl. allg. Path. path. Anat. 107: 96.
3. BURTSCHER, H. 1968. Die virusbedingte Hepatosplenitis infectiosa strigum: II. Kultur- und Infektionsversuche. Zentbl. Veterinarmed Reihe B 15: 540-554.
4. BURTSCHER, H., and A. SCHUMACHER. 1966. Morphologische Untersuchungen zur Virusätiologie der Hepatosplenitis infectiosa strigum. Path. vet. 3: 506-528.
5. COWDRY, E. V. 1934. The problem of intranuclear inclusions in virus diseases. Arch. Path. 18: 527-542.
6. FENNER, F. J. 1968. *Biology of Animal Viruses*. Vol. 1. Academic Press, New York, page 305.
7. FINDLAY, G. M. 1933. Pacheco's parrot disease. Vet. J. 89: 12.
8. GOUDAS, P., and J. S. GILROY. 1970. Spontaneous herpes-like viral infection in a chinchilla (*Chinchilla laniger*). J. Wildl. Dis. 6: 175-179.
9. GREEN, R. G., and J. E. SHILLINGER. 1936. A virus disease of owls. Amer. J. Path. 12: 405-410.
10. HELMBOLDT, C. F., and M. N. FRAZIER. 1963. Avian hepatic inclusion bodies of unknown significance. Avian Dis. 7: 446-450.
11. HICKEY, J. J., and J. E. ROELLE. 1969. Conference summary and conclusions. In *Peregrine Falcon Populations. Their Biology and Decline*. J. J. Hickey, ed. Univ. Wisconsin Press, Madison, pages 553-567.
12. HOWELL, J., D. W. MacDONALD, and R. G. CHRISTIAN. 1970. Inclusion body hepatitis in chickens. Can. Vet. J. 11: 99-101.
13. LEHNER, N. M. D., B. C. BULLOCK, and T. B. CLARKSON. 1967. Intranuclear inclusion disease of pigeons. J. Amer. Vet. Med. Assoc. 151: 939-941.
14. SMADEL, J. E., E. B. JACKSON, and J. W. HARMAN. 1945. A new virus disease of pigeons. I. Recovery of the virus. J. Exper. Med. 81: 385-398.
15. SOBEL, H. J., R. SCHWARZ, and E. MARQUET. 1969. Nonviral nuclear inclusions. I. Cytoplasmic invaginations. Arch. Path. 87: 179-192.
16. WARD, F. P., D. G. FAIRCHILD, and J. V. VUICICH. 1970. Pulmonary aspergillosis in prairie falcon nest mates. J. Wildl. Dis. 6: 80-83.

Received for publication December 21, 1970