



Cranial Osteochondroma in a White-tailed Deer (*Odocoileus Virginianus*)

Authors: Williams, E. S., Thorne, E. T., and Yorgason, I. J.

Source: Journal of Wildlife Diseases, 25(2) : 258-261

Published By: Wildlife Disease Association

URL: <https://doi.org/10.7589/0090-3558-25.2.258>

BioOne Complete (complete.BioOne.org) is a full-text database of 200 subscribed and open-access titles in the biological, ecological, and environmental sciences published by nonprofit societies, associations, museums, institutions, and presses.

Your use of this PDF, the BioOne Complete website, and all posted and associated content indicates your acceptance of BioOne's Terms of Use, available at www.bioone.org/terms-of-use.

Usage of BioOne Complete content is strictly limited to personal, educational, and non - commercial use. Commercial inquiries or rights and permissions requests should be directed to the individual publisher as copyright holder.

BioOne sees sustainable scholarly publishing as an inherently collaborative enterprise connecting authors, nonprofit publishers, academic institutions, research libraries, and research funders in the common goal of maximizing access to critical research.

SHORT COMMUNICATIONS

Journal of Wildlife Diseases, 25(2), 1989, pp. 258-261
© Wildlife Disease Association 1989

Cranial Osteochondroma in a White-tailed Deer (*Odocoileus virginianus*)

E. S. Williams,¹ E. T. Thorne,² and I. J. Yorgason,³ ¹ Department of Veterinary Sciences, University of Wyoming, Laramie, Wyoming 82070, USA; ² Wyoming Game and Fish Department, Research Laboratory, Box 3312 University Station, Laramie, Wyoming 82071, USA; ³ Wyoming Game and Fish Department, 2820 State Highway 120, Cody, Wyoming 82414, USA

ABSTRACT: A large osteochondroma of the skull was diagnosed in a young adult free-ranging white-tailed deer (*Odocoileus virginianus*) from Wyoming. The 4.8-kg neoplasm primarily involved the left frontal bone with extension into the cranial cavity. Microscopically, the neoplasm was composed of well differentiated trabecular bone and islands of cartilage. This neoplasm is rare in domestic species and has not been reported in cervids. Though benign in morphology, the location and size of the neoplasm was probably responsible for debilitation of the deer.

Key words: *Odocoileus virginianus*, white-tailed deer, osteochondroma, neoplasia, pathology, case report.

Benign tumors of bony, cartilaginous, or fibro-osseous origin are rare in animals (Misdorp and Van Der Heul, 1976; Pool, 1978). Classification of these neoplasms is contentious and their biology is poorly understood (Pool, 1978; Jubb et al., 1985). Benign skeletal neoplasms have been described infrequently from free-ranging animals (Williams and Thorne, 1988). Surveys of captive wild animals in zoological gardens do not report these neoplasms in the Cervidae (Lombard and Witte, 1959; Effron et al., 1977; Montali, 1980; Griner, 1983).

A 3½-yr-old free-ranging female white-tailed deer (*Odocoileus virginianus*) with a large mass protruding from the top of her head was observed in Park County, Wyoming (44°40'N, 109°10'W) by several ranch families during the summer and fall of 1984. The growth first became apparent in June. She raised two fawns during the summer and then progressively lost weight

to a state of emaciation when she was shot, frozen, and submitted to the Wyoming State Veterinary Laboratory (Laramie, Wyoming 82070, USA) for necropsy. A large, hard, generally spherical mass (16 × 21 × 22 cm; 4.8 kg) protruded from the left side of the head above the eye (Fig. 1). The mass was covered by lightly haired, focally traumatized skin.

The bony mass involved the left frontal bone with extension into the cranial cavity causing indentation of the left cerebral cortex (Fig. 2). The left zygomatic arch was destroyed, a bony protrusion extended into the socket of the left eye, and there was focal involvement of the squamous temporal bone and mastoid process. The

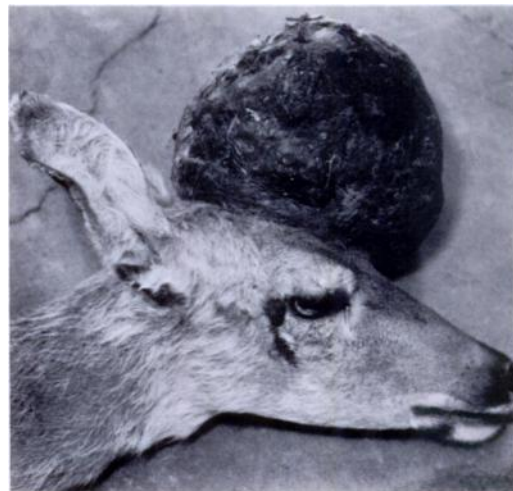

FIGURE 1. Large osteochondroma protruding from the skull of a white-tailed deer.

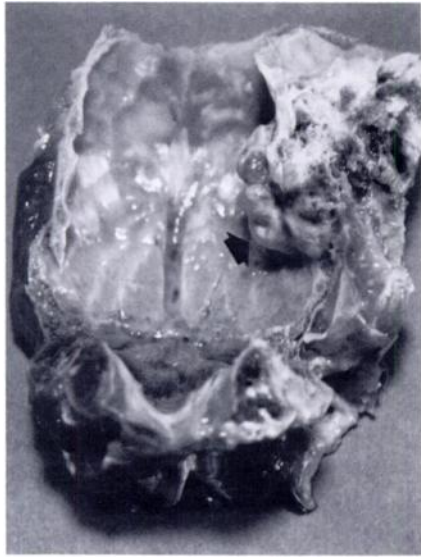

FIGURE 2. Extension of the osteochondroma (arrow) into the cranial cavity of a white-tailed deer.

cut surface of the mass contained areas of hemorrhage, necrosis, dense bone and fine bone spicules. Other organs in the deer appeared grossly normal.

Seven sections of different regions of the neoplasm and other tissues were fixed in 10% buffered formalin, embedded in paraffin, cut at 6 μm , and stained with hematoxylin and eosin. In densely mineralized areas of the neoplasm, the tissue was decalcified (DECAL, Chemical Corporation, Pomona, New York 10970, USA) prior to sectioning.

Microscopically, the neoplasm was composed primarily of bone trabeculae lined by well differentiated osteoblasts and osteoclasts (Fig. 3). Cartilage was most abundant near the surface of the neoplasm and endochondral bone formation was present (Fig. 4). Mitotic figures in neoplastic cells were rare. A light meshwork of fibrovascular tissue was present between bone spicules. Metastases were not found in regional lymph nodes or other organs.

The neoplasm was considered to be an osteochondroma based on the gross appearance and the presence of well differentiated bone and cartilage though a clearly defined cartilage cap was not apparent.




FIGURE 3. Bone spicules lined by well differentiated osteoblasts in a representative section of the osteochondroma. H&E.

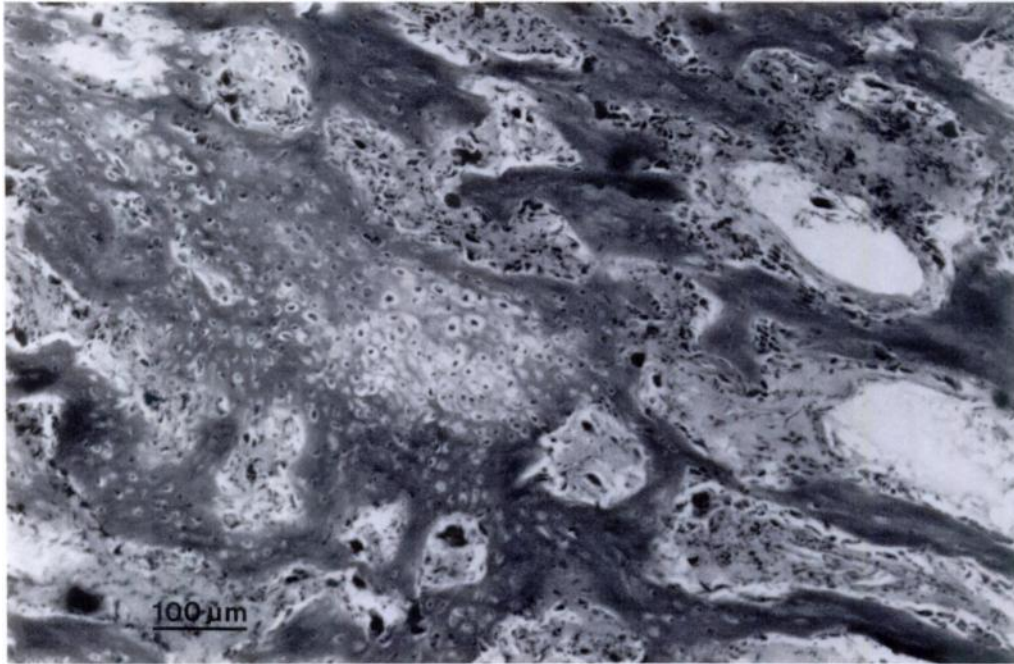


FIGURE 4. Bone spicules and cartilage in a representative section of the osteochondroma. H&E.

Osteochondromas occur in a variety of domestic species (Pool, 1978; Jubb et al., 1985) and frequently involve endochondral bone. In some species, they may be multicentric, heritable, and are often considered malformations rather than neoplasms (Pool, 1978; Jubb et al., 1985). The cause of solitary osteochondromas, such as occurred in this deer, is not known.

This neoplasm also had features that resemble those described for osteoma. Osteomas are rare benign neoplasms of bone that usually arise from cortical surfaces of the skull and facial bones (Pool, 1978; Jones and Hunt, 1983). Two osteomas have been reported in free-ranging white-tailed deer (Cosgrove et al., 1981).

The weight and bulk of the mass, its location on the head, as well as compression of the cerebral cortex was no doubt responsible for the progressive loss of weight of the deer. Bone neoplasms appear to be quite rare in cervids and they are of no consequence to deer populations.

Representative sections of the neoplasm

described in this report have been deposited in the Registry of Comparative Pathology (Armed Forces Institute of Pathology, Washington, D.C. 20306, USA; Accession Number 2174008-9).

We wish to acknowledge the assistance of Dave Jones, Wyoming Game and Fish Department Research Laboratory, for determining the age of the deer and Robert Dahlgren and Stanley Snyder for discussion of the histology. This case report was supported by Federal Aid to Wildlife Restoration, Wyoming Project FW-17-P and the Department of Veterinary Sciences, University of Wyoming.

LITERATURE CITED

- COSGROVE, G. E., L. C. SATTERFIELD, AND V. F. NETTLES. 1981. Neoplasia. *In* Diseases and parasites of white-tailed deer, W. R. Davidson, F. A. Hayes, V. F. Nettles, and F. E. Kellogg (eds.). Tall Timbers Research Station, Miscellaneous Publication, Tallahassee, Florida, pp. 62-71.
- EFFRON, M., L. GRINER, AND K. BENERSCHKE. 1977. Nature and rate of neoplasia found in captive

- wild mammals, birds, and reptiles at necropsy. *Journal of the National Cancer Institute* 59: 185-198.
- GRINER, L. A. 1983. Pathology of zoo animals. Zoological Society of San Diego, San Diego, California, 608 pp.
- JONES, T. C., AND R. D. HUNT. 1983. Veterinary pathology, 5th ed. Lea and Febiger, Philadelphia, Pennsylvania, 1,792 pp.
- JUBB, K. V. F., P. C. KENNEDY, AND N. PALMER. 1985. Pathology of domestic animals, Vol. 1, 3rd ed. Academic Press, New York, New York, 574 pp.
- LOMBARD, L. S., AND E. J. WITTE. 1959. Frequency and types of tumors in mammals and birds of the Philadelphia Zoological Gardens. *Cancer Research* 19: 127-141.
- MISDORP, W., AND R. O. VAN DER HEUL. 1976. Tumors of bones and joints. International histological classification of tumors of domestic animals, Part 2. *Bulletin of the World Health Organization* 53: 265-282.
- MONTALI, R. J. 1980. An overview of tumors in zoo animals. *In* The comparative pathology of zoo animals, R. J. Montali and G. Migaki (eds.). Smithsonian Institution Press, Washington, D.C., pp. 531-542.
- POOL, R. R. 1978. Tumors of bone and cartilage. *In* Tumors in domestic animals, 2nd ed., J. D. Moulton (ed.). University of California Press, Berkeley, California, pp. 92-107.
- WILLIAMS, E. S., AND E. T. THORNE. 1988. Spontaneous tumors of free-ranging terrestrial mammals of North America. *In* Cancer growth and progression, comparative aspects of tumor development, Vol. 5, H. E. Kaiser (ed.). Kluwer Academic Publishers, Boston, Massachusetts, pp. 214-225.

Received for publication 6 January 1986.