

TWO NOVEL ALPHAHERPESVIRUSES ASSOCIATED WITH FATAL DISSEMINATED INFECTIONS IN ATLANTIC BOTTLENOSE DOLPHINS

Authors: Blanchard, Terrell W., Santiago, Nancy T., Lipscomb, Thomas P., Garber, Richard L., McFee, Wayne E., et al.

Source: Journal of Wildlife Diseases, 37(2) : 297-305

Published By: Wildlife Disease Association

URL: <https://doi.org/10.7589/0090-3558-37.2.297>

BioOne Complete (complete.BioOne.org) is a full-text database of 200 subscribed and open-access titles in the biological, ecological, and environmental sciences published by nonprofit societies, associations, museums, institutions, and presses.

Your use of this PDF, the BioOne Complete website, and all posted and associated content indicates your acceptance of BioOne's Terms of Use, available at www.bioone.org/terms-of-use.

Usage of BioOne Complete content is strictly limited to personal, educational, and non - commercial use. Commercial inquiries or rights and permissions requests should be directed to the individual publisher as copyright holder.

BioOne sees sustainable scholarly publishing as an inherently collaborative enterprise connecting authors, nonprofit publishers, academic institutions, research libraries, and research funders in the common goal of maximizing access to critical research.

TWO NOVEL ALPHAHERPESVIRUSES ASSOCIATED WITH FATAL DISSEMINATED INFECTIONS IN ATLANTIC BOTTLENOSE DOLPHINS

Terrell W. Blanchard,^{1,7} Nancy T. Santiago,¹ Thomas P. Lipscomb,¹ Richard L. Garber,² Wayne E. McFee,³ and Susan Knowles⁴

¹ Department of Veterinary Pathology, Armed Forces Institute of Pathology, Washington, DC 20306, USA

² PathoGenesis Corporation, Seattle, Washington 98119, USA

³ NOAA, National Ocean Service, Center for Coastal Environmental Health and Biomolecular Research, Charleston, South Carolina 29412, USA

⁴ Department of Natural Resources, Cooperative Oxford Laboratory, Oxford, Maryland 21654, USA

⁷ Corresponding author (e-mail: terrell.blanchard@na.amedd.army.mil)

ABSTRACT: Two immature female bottlenose dolphins (*Tursiops truncatus*) were found stranded on the Atlantic coast of the USA. Necropsy and histopathologic examination of both dolphins demonstrated acute necrotizing lesions in multiple organ systems. Commonly seen in these lesions were cells with enlarged nuclei that contained single 4 to 6 μm diameter homogeneous eosinophilic inclusion bodies that were often surrounded by a clear halo. Ultrastructural examination revealed that intranuclear inclusions contained 90 to 110 nm diameter viral particles with electron-dense cores and hexagonal profiles. Viral particles were also present in the cytoplasm, and these were surrounded by variably electron-dense envelopes. Enveloped virions were 140 nm in diameter. Polymerase chain reactions targeting the DNA polymerase and terminase genes of herpesviruses were carried out on unfixed tissues of both animals, and analysis of the DNA products indicated the presence of two novel alphaherpesviruses. The gross, histologic, ultrastructural, and molecular genetic findings indicate disseminated herpesviral infections, and support the conclusion that the alphaherpesviruses caused the deaths of the two dolphins. This is the first report of disseminated herpesviral infection in cetaceans.

Key words: Bottlenose dolphin, heart, herpesvirus, inclusions, lymphoid necrosis, syncytial cells, thymus, *Tursiops truncatus*.

INTRODUCTION

Herpesviruses cause a wide range of pathologic responses, from inapparent infections to fatal disseminated disease (Cheville, 1994). Herpesviral infections have been documented in most types of vertebrates; however, only a few cases of herpesviral infection have been reported in cetaceans. Herpesviral encephalitis was reported in a harbor porpoise (*Phocoena phocoena*) in Sweden (Kennedy et al., 1992), and we have diagnosed similar cases in this species (T. P. Lipscomb and T. W. Blanchard, unpubl. obs.). There are two reports of herpesvirus-like dermatitis in beluga whales (*Delphinapterus leucas*) in Canada (Barr et al., 1989; Martineau et al., 1988). Herpesvirus-like particles were documented in skin lesions in four dusky dolphins (*Lagenorhynchus obscurus*) caught in Peruvian coastal waters (Van Bresse et al., 1994). The purpose of this

report is to document disseminated herpesviral infection, based on histological, ultrastructural, and molecular evidence, in two stranded bottlenose dolphins (*Tursiops truncatus*).

MATERIALS AND METHODS

Animals

Two juvenile bottlenose dolphins were found stranded on the Atlantic coast of the USA. Case 1, a 161 cm-long female, was found dead on Hilton Head Island (Beaufort County, South Carolina, USA; 32°6'N and 80°49'W) on 10 December, 1995. The dolphin's age was estimated to be 9 or 10 mo based on tooth analysis using the methods of Hohn (1980) and Perrin and Myrick (1980). A complete necropsy was performed at the National Ocean Service Laboratory (Charleston, South Carolina, USA). Case 2, a 150 cm-long female, was found alive and died shortly thereafter on Prime Hook Beach (Sussex County, Delaware, USA; 38°52'N and 75°15'W) on 26 August, 1999. Necropsy of this dolphin was performed at the Cooperative Oxford Laboratory (Oxford, Maryland, USA). Representative tissue samples from

each case were fixed in 10% neutral buffered formalin and submitted to the Department of Veterinary Pathology [Armed Forces Institute of Pathology (AFIP), Washington DC, USA] for histopathologic evaluation [AFIP accession numbers 2525781 (case 1) and 2696797 (case 2)].

Histology and electron microscopy

Formalin-fixed tissue specimens were embedded in paraffin, sectioned at 5 μ m, and stained with hematoxylin and eosin and examined by light microscopy. Selected sections were stained with Brown and Brenn Gram's stain (Luna, 1968), Brown and Hopps Gram's stain (Luna, 1968), and by Grocott's methenamine silver nitrate method for fungi (Luna, 1968). For ultrastructural studies, selected tissues were deparaffinized, hydrated and post-fixed in 1% osmium tetroxide, dehydrated, cleared and embedded in epoxy resin (Steele et al., 1997). One micron sections were cut and stained with toluidine blue for preliminary light microscopic examination. Thin sections (80 to 90 nm) were cut and stained with uranyl acetate and lead citrate for electron microscopy (Steele et al., 1997).

Morbilliviral infection, which caused extensive epizootics that affected bottlenose dolphins along the Atlantic coast of the USA and in the Gulf of Mexico, results in severe immunosuppression and may lead to opportunistic infections (Schulman et al., 1997; Lipscomb et al., 1996). Therefore, we searched carefully for histologic lesions of morbillivirus infection, including bronchointerstitial pneumonia; nonsuppurative encephalitis; lymphoid depletion and lymphocytolysis; and 3 to 8 μ m diameter eosinophilic intracytoplasmic and intranuclear inclusions in lung, lymphoid and central nervous system tissues or epithelium of multiple organs (Kennedy, 1998).

Molecular analyses

Two lines of molecular analysis were pursued to investigate possible involvement of viruses in these disseminated infection cases. Initially, formalin-fixed, paraffin-embedded sections of affected lymph node from case 1, and lung from case 2, were tested for the presence of morbilliviral RNA by reverse-transcriptase polymerase chain reaction (RT-PCR) as previously described (Krafft et al., 1995).

Subsequently, DNA was extracted from sections of frozen, unfixed lung tissue from case 1 and heart tissue from case 2, and consensus primer PCR was performed in reactions designed to amplify conserved internal regions of herpesviral DNA polymerase and terminase

genes (Van Devanter et al., 1996; Hargis et al., 1999). The reaction products were sequenced directly and compared to published herpesvirus sequences contained in GenBank using BLASTP software on the National Center for Biotechnology Information (Bethesda, Maryland, USA) website (www.ncbi.nlm.nih.gov). Phylogenetic trees showing the sequence similarity relationships between herpesviral species were constructed using CLUSTAL followed by a tree algorithm in the DNASTar MegAlign program (DNASTAR, Inc., Madison, Wisconsin, USA).

RESULTS

Necropsy

The most striking gross necropsy finding in case 1 was a markedly enlarged thymus, which was approximately ten times its expected size. The pleural cavity contained abundant clear, red-tinged fluid, and there was hemorrhage in the pericardial sac. Generalized icterus was apparent, most notably in the blubber, which was of normal thickness. The liver was brown but contained several irregularly-defined, variably-sized foci with purple discoloration. Both kidneys appeared fatty, and multiple small black-speckled foci lined the mucosal surface of the urinary bladder. Hemorrhage was present in the periuterine region of the caudal abdominal cavity.

Gross necropsy findings in case 2 included a total of seven 0.5 to 2 cm diameter ulcerated lesions on the snout. The right cranial side of the dorsal fin contained a 0.75 cm diameter ulcerative lesion, and the left side contained a similar 1 cm diameter lesion. The pleural cavity contained 500 ml of clear fluid. The lungs were mottled red and tan and contained three 2 cm diameter white foci. The liver had blunted edges and was mottled red and tan.

Histopathology

Histologic changes in case 1 were most prominent in the thymus and spleen. Thymic lobules were partially effaced by abundant hemorrhage. Hemorrhage, fibrin, and edema expanded the interlobular septal connective tissue. There was extensive ne-

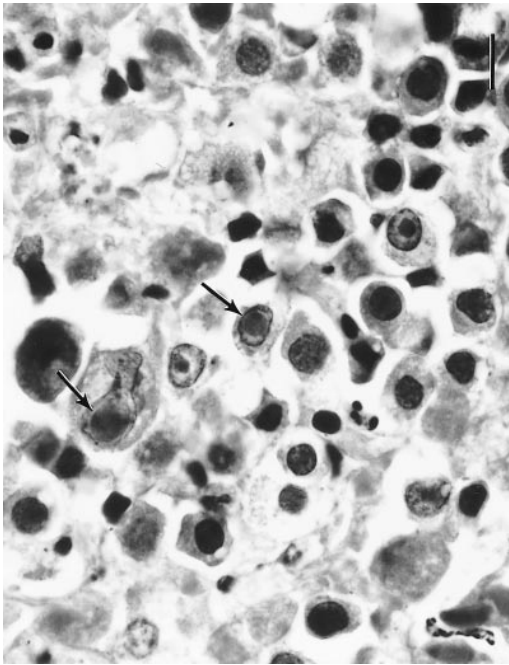


FIGURE 1. Case 1. Thymus of bottlenose dolphin with disseminated herpesvirus infection. Note enlarged lymphocyte nuclei containing inclusion bodies (arrows). H&E. Bar = 10 μ m.

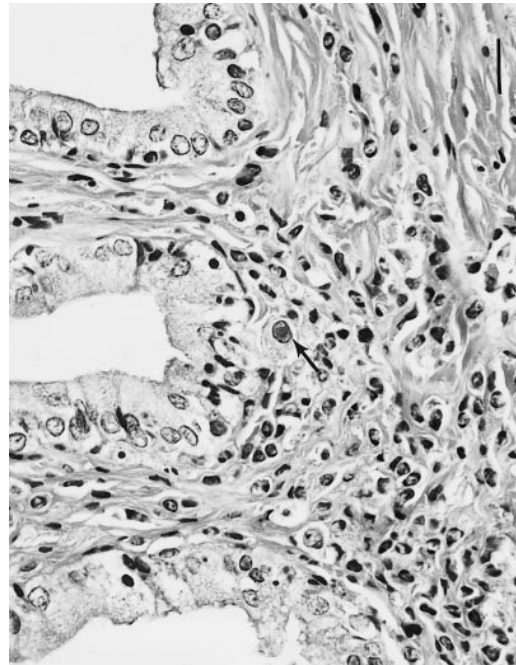


FIGURE 2. Case 1. Necrosis and inflammatory cell infiltrate in uterus of bottlenose dolphin. Note mononuclear cell containing an intranuclear inclusion body (arrow). H&E. Bar = 20 μ m.

crosis of thymic lymphocytes, characterized by loss of cellular detail and accumulation of karyorrhectic and eosinophilic cellular debris. Multifocally, predominantly within and near areas of necrosis, lymphocytes had enlarged nuclei which often contained single, 4 to 6 μ m diameter, homogeneous, pale, eosinophilic inclusion bodies. Inclusion bodies were often surrounded by a 1 to 2 μ m clear space (Fig. 1). There were small numbers of syncytial cells with moderate amounts of eosinophilic cytoplasm and two to five nuclei. Some syncytial cell nuclei contained similar inclusion bodies.

Within the spleen and multiple visceral and peripheral lymph nodes, there were numerous necrotic lymphocytes. Randomly scattered throughout splenic red and white pulp areas, and throughout lymph nodes, were numerous large, 16 to 20 μ m diameter, round to polygonal cells with abundant eosinophilic cytoplasm and round to oval nuclei. Nuclei of these cells

were often enlarged and occasionally distorted by eosinophilic inclusion bodies.

There was diffuse interstitial pneumonia. Alveolar septa were expanded by macrophages and lymphocytes admixed with scattered karyorrhectic debris. Alveoli were often lined by hyperplastic type II pneumocytes; rarely, unidentified cells within the alveolar interstitium contained eosinophilic intranuclear inclusion bodies.

In the adrenal cortex, there were few scattered foci of necrosis accompanied by small numbers of neutrophils. Within these foci, adrenal cortical cells with eosinophilic intranuclear inclusion bodies were present. In the uterus, there was multifocal infiltration of the stroma by histiocytes and fewer lymphocytes; these mononuclear inflammatory cells sometimes contained intranuclear inclusions (Fig. 2). There was scattered necrosis of uterine epithelial cells and small amounts of necrotic debris within inflamed stromal areas. Within the heart muscle, there was mild lymphocytic

and histiocytic inflammation. Rare enlarged cardiomyocyte nuclei contained inclusion bodies. A few renal glomerular tufts contained cells with similar intranuclear inclusions.

Inflammatory lesions were present in several tissues in which neither viral inclusion bodies nor other etiologic agents were identified. These lesions included an acute, focally extensive, hemorrhagic and necrotizing dermatitis of the mid-dorsal area, and mild, lymphohistiocytic esophagitis, bronchitis, and cystitis. In the liver, there was diffuse centrilobular vacuolar change, degeneration, and necrosis. A section of skeletal muscle had mild degeneration with multifocal necrosis. There was mild to moderate lymphoid depletion in gut-associated lymphoid tissue and in a pulmonary hilar lymph node.

Histologic changes in case 2 were most prominent in the myocardium, skin, and tongue. There was abundant cardiomyocyte necrosis, characterized by fragmentation of cells, loss of cross-striations, sarcoplasmic hypereosinophilia and accumulation of karyorrhectic and eosinophilic cellular debris. Necrosis was accompanied by moderate lymphoplasmacytic inflammation. Numerous cardiomyocyte nuclei, predominantly in and near necrotic areas, were enlarged and each contained a 4 to 6 μm diameter, homogeneous, pale eosinophilic inclusion body.

As in case 1, there was diffuse interstitial pneumonia, with alveolar septa expanded by macrophages, lymphocytes, scattered karyorrhectic debris, fibrin and edema. Few unidentified cells within the alveolar interstitium contained eosinophilic intranuclear inclusion bodies. Simultaneously, there was diffuse, severe bronchopneumonia associated with numerous adult and larval nematodes, present in both bronchioles and alveoli, and scattered gram-negative bacilli.

The epidermis of the snout and dorsal fin was multifocally ulcerated, and in some areas was markedly hyperplastic, with anastomosing rete ridges. Ulcerated foci

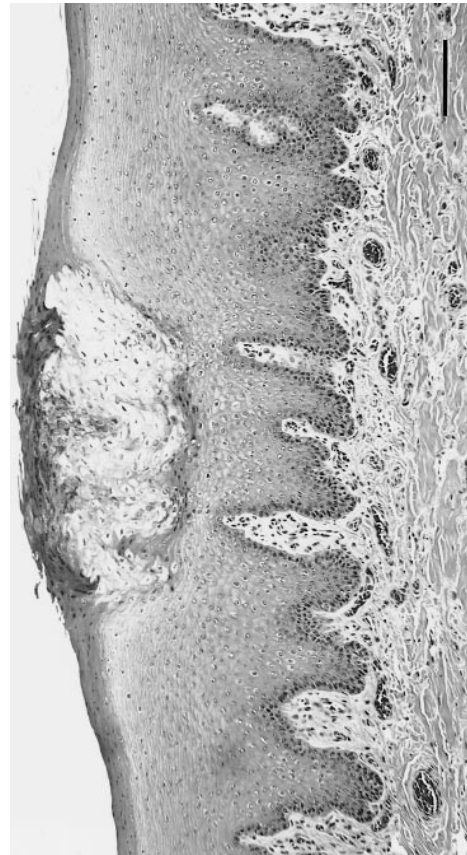

FIGURE 3. Case 2. Focal ballooning degeneration of glossal epithelium in herpesvirus-infected bottlenose dolphin. H&E. Bar = 125 μm .

contained karyorrhectic and eosinophilic cellular debris, viable and degenerate neutrophils, macrophages, hemorrhage and congestion, along with numerous gram-positive and gram-negative bacilli, ciliated protozoa, and few fungal hyphae. These organisms were interpreted to represent secondary opportunistic infections. Similar ciliated protozoa have been previously reported in bottlenose dolphins (Schulman and Lipscomb, 1999). Multiple epidermal epithelial cells, primarily in and near ulcers, contained eosinophilic intranuclear inclusion bodies.

Within the tongue there was disruption of the glossal epithelium. Multifocally, squamous epithelial cells were enlarged and contained abundant cleared cytoplasm (ballooning degeneration) (Fig. 3). Nu-

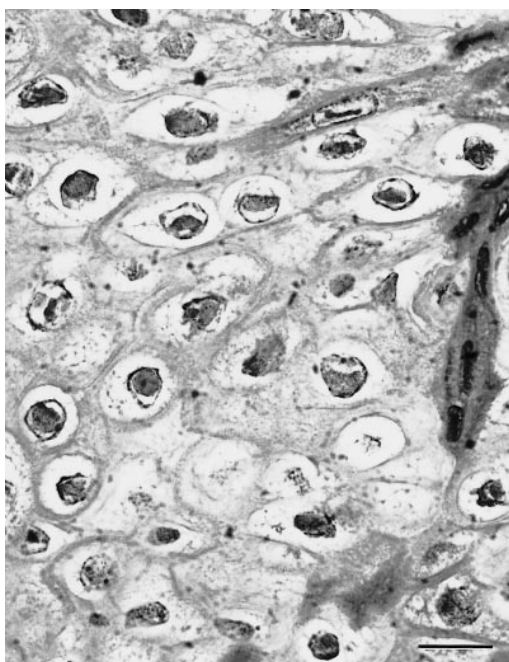


FIGURE 4. Case 2. Higher magnification of area of epithelial ballooning degeneration in figure 3. Most nuclei contain distinct inclusion bodies. H&E. Bar = 20 μ m.

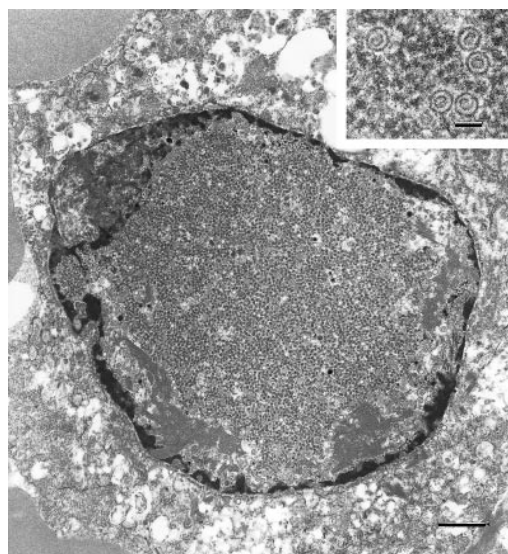


FIGURE 5. Case 1. Ultrastructural appearance of thymus of bottlenose dolphin with disseminated herpesvirus infection. Chromatin is displaced peripherally; the nucleus is filled by a granular inclusion containing numerous viral particles. Uranyl acetate and lead citrate. Bar = 1 μ m. *Inset*: Higher magnification of intranuclear viral nucleocapsids. Uranyl acetate and lead citrate. Bar = 100 nm.

merous nuclei were enlarged, with peripheralized chromatin and similar inclusion bodies (Fig. 4).

Inflammatory and necrotizing lesions were present in several tissues in which neither viral inclusion bodies nor other etiologic agents were identified. There was multifocal lymphoid necrosis in the spleen, mild lymphoplasmacytic tracheitis and focally extensive suppurative colitis.

Ultrastructure

Electron microscopic examination of thymus from case 1, and of heart, snout and tongue from case 2, revealed nuclei in which heterochromatin was at the periphery adjacent to the nuclear membrane, and which contained large inclusion bodies consisting of numerous viral nucleocapsids with hexagonal profiles, admixed with abundant finely granular electron-dense material. Between the inclusions and peripheralized chromatin there were often aggregates of moderately electron-dense fil-

amentous protein material. Nucleocapsids contained electron-dense cores and had icosahedral symmetry; they were 90 to 110 nm in diameter (Fig. 5). Virions were present in the cytoplasm; variably electron dense envelopes surrounded them (Fig. 6). Enveloped virions were approximately 140 nm in diameter.

Molecular virology

In both cases, RT-PCR testing for morbillivirus yielded negative results. Because the observed intranuclear inclusion bodies and ultrastructural findings were consistent with herpesviruses, consensus primer PCR procedures capable of detecting the presence of most herpesviruses were followed. Using primers specific for a highly conserved region of herpesviral DNA polymerase genes, products were obtained from both dolphin cases. Case 1 yielded a 189 bp product and case 2 yielded a 180 bp product. DNA sequencing revealed that both DNA polymerase partial gene sequences

[illegible]

at various positions. Therefore, even with only a partial amino acid sequence, it is possible to place most new viruses into one of these three groups.

Terminase

ACCAACACCGGGAAAGCTAGCACCAAGTCTCTCTTCAACCTCAAGTACTCTCGGAC
 T N T T G C A K S T S F L F N L K Y S S D
 GACCTTGCTCAATGTGGTGCAGTATATCTGGCAAGGACACATGGATCGGTGGCGCGTG
 D L L N V V T Y I C D E H M D R V R V
 CACACGAAGCCACGGCCTGTTCGTGTACGTGCTGAACACAGCGGTGTTCATCAG
 H T N T A T A C S C Y V L N K P V F I T
 ATGGACGGCTGCATGCGAAACCGCGAGATGTCTCTGCGGAACCTGTTCTACGAG
 M D A S M R N T A E E M F L P N S G F M Q
 GAGATCATCGGCGCGCTCCGGCGGACCCGGCGCGCGGCGCGCCGCTGCTTC
 E I I G G G A D A F A G D G P V F
 ACAAAAGGCTCGGGCGACCAAGTTCTGCTCTACCGCCCTCCACCACCAGCGCGCA
 T K G A A A D Q F L L Y R S T T T R R
 GCGCGAATGGCGAGGAAGCTGTTTCGTGACGTG
 G A M A E E L F V Y V

were different from any published sequences in GenBank (www.ncbi.nlm.nih.gov) and were different from each other (Fig. 7). Consistent with the results for the DNA polymerase gene, a herpesviral terminase partial gene product was amplified from the case 1 dolphin sample (Fig. 8). Its sequence was also different than any other herpesviral terminase gene sequence published in GenBank, thus confirming the uniqueness of this putative herpesvirus.

Downloaded From: <https://bioone.org/journals/Journal-of-Wildlife-Diseases> on 28 Apr 2024
Terms of Use: <https://bioone.org/terms-of-use>

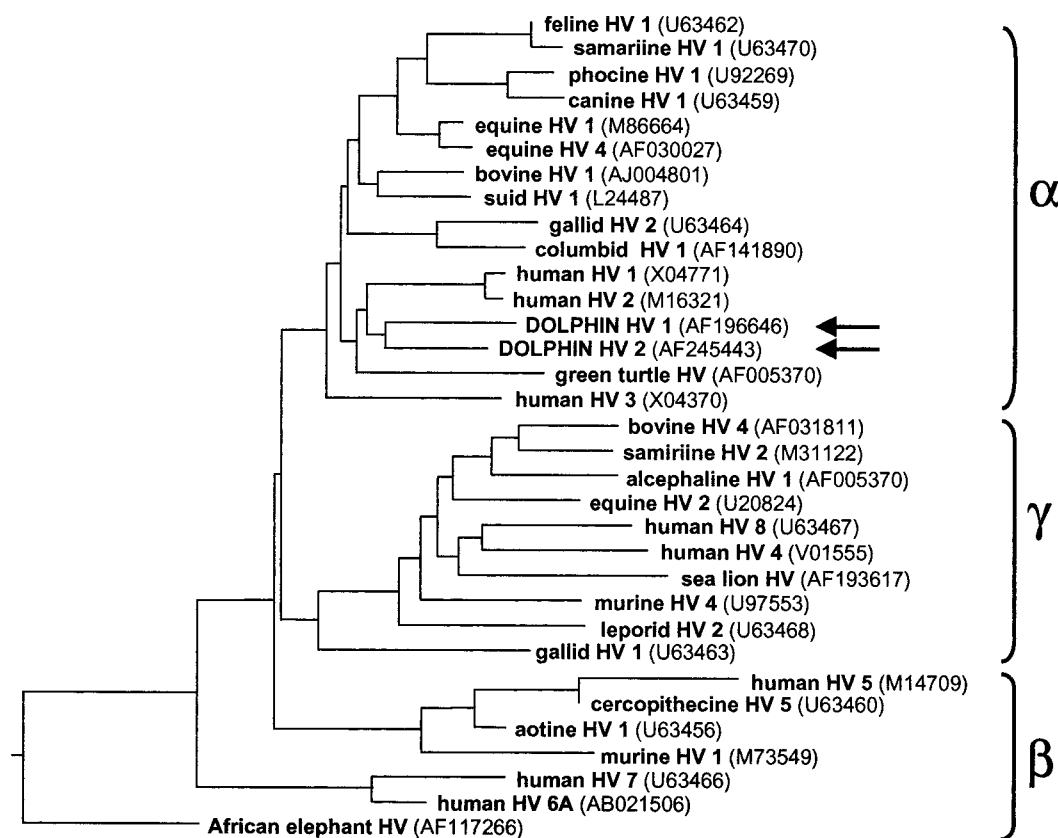


FIGURE 9. Phylogenetic tree relating amino acid sequences of herpesviral DNA polymerases. The two dolphin cases are indicated by arrows. The other sequences were obtained from GenBank. The sequences group into the known alpha-, beta-, and gammaherpesvirus subfamilies.

tity). In addition, note that the dolphin herpesvirus DNA polymerases differ in length from each other by three amino acids (Fig. 7).

DISCUSSION

The gross and histologic findings in both bottlenose dolphins, consisting predominantly of necrotizing lesions and intranuclear inclusion bodies in multiple organ systems, are consistent with disseminated viral infections. Syncytial cells, intranuclear inclusion bodies and lymphoid depletion are characteristic of both herpesvirus and morbillivirus infections; however, the absence of intracytoplasmic inclusion bodies and the prominence of necrosis in these dolphins are more consistent with herpesvirus infection. The ultrastructural

findings of herpesvirus-like particles and molecular evidence of herpesviral genes present within affected tissues, and the lack of evidence of any other primary pathogens, strongly support the conclusion that novel but distinct alphaherpesviruses were the cause of the lesions and were the primary cause of death in each case. Molecular tests did not demonstrate the presence of morbillivirus, a known cause of immunosuppressive disease in bottlenose dolphins.

This is the first report of disseminated herpesviral infection in cetaceans. Results of PCR and nucleic acid sequencing analysis indicate the presence of two novel alphaherpesviruses, the origin and natural host(s) of which are unknown. Traditionally, the Herpesviridae family has been

subclassified into three subfamilies, the alpha-, beta-, and gammaherpesvirinae. Members of the alphaherpesvirinae subfamily, which includes herpes simplex and varicella viruses, as well as bovine herpesvirus 1 and feline herpesvirus 1, typically grow rapidly and lyse infected cells, and often establish latent infections primarily in sensory nerve ganglia (Fenner et al., 1993). Generalized alphaherpesvirus infections are usually characterized by foci of necrosis in multiple organs and tissues, as seen in the bottlenose dolphin cases reported here, and these are most often seen in young animals lacking the protection of maternal antibody (Fenner et al., 1993). The present cases may represent immunologically naive animals overwhelmed by initial infections with previously undiscovered herpesviruses that are endemic and usually subclinical in bottlenose dolphins. Alternatively, they may represent recrudescence of latent herpesviral infections secondary to physiologic stress or immunosuppression. Another possibility is that the natural host(s) of these viruses could be a species other than bottlenose dolphins, and these cases represent atypical infections in an aberrant host. Neither of the dolphin herpesviruses described here are closely related to herpesviruses found in other marine animals, namely harbor seals (*Phoca vitulina*) (GenBank U92269), sea lions (*Zalophus californianus*) (GenBank AF193617) or green sea turtles (*Chelonia mydas*) (GenBank AF035003). Testing of additional bottlenose dolphins for the presence of similar herpesviruses, including investigation of ganglia, is needed to begin to understand the significance of this type of pathogen to dolphin populations.

ACKNOWLEDGEMENTS

This study was partially funded by the National Marine Fisheries Service. The authors thank the members of the South Carolina and Delaware Marine Mammal Stranding Networks. We also thank J. Jenkins and R. A. V. Ferris for electron microscopic and photomicrographic support, respectively. The opinions

or assertions contained herein are the private views of the authors and are not to be construed as official or as reflecting the views of the Department of the Army or the Department of Defense.

LITERATURE CITED

- BARR, B., J. L. DUNN, M. D. DANIEL, AND A. BARNFORD. 1989. Herpes-like viral dermatitis in a beluga whale (*Delphinapterus leucas*). *Journal of Wildlife Diseases* 25: 608–611.
- CHEVILLE, N. F. 1994. Ultrastructural pathology. An introduction to interpretation. Iowa State University Press, Ames, Iowa, 946 pp.
- FENNER, F. J., E. P. J. GIBBS, F. A. MURPHY, R. ROTT, M. J. STUDDERT, AND D. O. WHITE. 1993. *Veterinary Virology*, 2nd Edition. Academic Press, Inc., San Diego, California, 666 pp.
- HARGIS, A. M., P. E. GINN, J. E. K. L. MANSELL, AND R. L. GARBER. 1999. Ulcerative facial and nasal dermatitis and stomatitis in cats associated with feline herpesvirus 1. *Veterinary Dermatology* 10: 267–274.
- HOHN, A. A. 1980. Age determination and age related factors in the teeth of western North Atlantic bottlenose dolphins. *Scientific Reports of the Whales Research Institute* 32: 39–66.
- KENNEDY, S. 1998. Morbillivirus infections in aquatic mammals. *Journal of Comparative Pathology* 119: 201–225.
- , I. J. LINDSTEDT, M. M. MCALISKEY, S. A. MCCONNELL, AND S. J. MCCULLOUGH. 1992. Herpesviral encephalitis in a harbor porpoise (*Phocoena phocoena*). *Journal of Zoo and Wildlife Medicine* 23: 374–379.
- KRAFFT, A., J. H. LICHY, T. P. LIPSCOMB, B. A. KLAUNBERG, S. KENNEDY, AND J. K. TAUBENBERGER. 1995. Postmortem diagnosis of morbillivirus infection in bottlenose dolphins (*Tursiops truncatus*) in the Atlantic and Gulf of Mexico epizootics by polymerase chain reaction-based assay. *Journal of Wildlife Diseases* 31: 410–415.
- LIPSCOMB, T. P., S. KENNEDY, D. MOFFETT, A. KRAFFT, B. A. KLAUNBERG, J. H. LICHY, G. T. REGAN, G. A. J. WORTHY, AND J. K. TAUBENBERGER. 1996. Morbilliviral epizootic in bottlenose dolphins of the Gulf of Mexico. *Journal of Veterinary Diagnostic Investigation* 8: 283–290.
- LUNA, L. G. (EDITOR). 1968. *Manual of Histologic Staining Methods of the Armed Forces Institute of Pathology*, 3rd Edition. McGraw-Hill Book Company, New York, New York, 258 pp.
- MARTINEAU, D., A. LAGACI, P. BELAND, R. HIGGINS, D. ARMSTRONG, AND L. R. SHUGART. 1988. Pathology of stranded beluga whales (*Delphinapterus leucas*) from the St. Lawrence Estuary, Quebec, Canada. *Journal of Comparative Pathology* 98: 287–311.

- PERRIN, W. F., AND A. C. MYRICK (EDITORS). 1980. Age determination of toothed whales and sire-nians. International Whaling Commission. Special Issue 3. Cambridge, UK, 230 pp.
- SCHULMAN, F. Y., T. P. LIPSCOMB, D. MOFFETT, A. E. KRAFFT, J. H. LICHY, M. M. TSAI, J. K. TAU-BENBERGER, AND S. KENNEDY. 1997. Histolog-ic, immunohistochemical, and polymerase chain reaction studies of bottlenose dolphins from the 1987–1988 United States Atlantic coast epizoot-ic. *Veterinary Pathology* 34: 288–295.
- , AND ———. 1999. Dermatitis with invasive ciliated protozoa in dolphins that died during the 1987–1988 Atlantic bottlenose dolphin morbilli-viral epizootic. *Veterinary Pathology* 36: 171–174.
- STEELE, K. E., F. Y. SCHULMAN, H. MENA, AND E. O. STRIMPLE. 1997. Rhabdoid tumor in the brain of a dog. *Veterinary Pathology* 34: 359–363.
- VAN BRESSEM, M. F., K. VAN WAEREBEEK, A. GAR-CIA-GODOS, D. DEKEGEL, AND P. P. PASTORET. 1994. Herpes-like virus in dusky dolphins, *La-genorhynchus obscurus*, from coastal Peru. *Ma-rine Mammal Science* 10: 354–359.
- VAN DEVANTER, D. R., P. WARRENER, L. BENNETT, E. R. SCHULTZ, S. COULTER, R. L. GARBER, AND T. M. ROSE. 1996. Detection and analysis of di-verse herpesviral species by consensus primer PCR. *Journal of Clinical Microbiology* 34: 1666–1671.

Received for publication 19 April 2000.