



Two Distinct Carcinomas of Mammary Gland Origin in a California Sea Lion

Authors: Matsuda, Michiko, Hashiura, Shinichiro, Une, Yumi, Sirouzu, Hiroshi, and Nomura, Yasuo

Source: Journal of Wildlife Diseases, 39(1) : 241-243

Published By: Wildlife Disease Association

URL: <https://doi.org/10.7589/0090-3558-39.1.241>

BioOne Complete (complete.BioOne.org) is a full-text database of 200 subscribed and open-access titles in the biological, ecological, and environmental sciences published by nonprofit societies, associations, museums, institutions, and presses.

Your use of this PDF, the BioOne Complete website, and all posted and associated content indicates your acceptance of BioOne's Terms of Use, available at www.bioone.org/terms-of-use.

Usage of BioOne Complete content is strictly limited to personal, educational, and non - commercial use. Commercial inquiries or rights and permissions requests should be directed to the individual publisher as copyright holder.

BioOne sees sustainable scholarly publishing as an inherently collaborative enterprise connecting authors, nonprofit publishers, academic institutions, research libraries, and research funders in the common goal of maximizing access to critical research.

Two Distinct Carcinomas of Mammary Gland Origin in a California Sea Lion

Michiko Matsuda,^{1,3,4} Shinichiro Hashiura,¹ Yumi Une,¹ Hiroshi Sirouzu,² and Yasuo Nomura^{1,1} Department of Veterinary Pathology, School of Veterinary Medicine, Azabu University, 1-17-71 Fuchinobe, Sagamihara, Kanagawa 229-8501, Japan; ² Taiji Whale Museum, 2934-2 Jyodo, Taiji-Cho, Higashimuro-Gun, Wakayama 649-5171, Japan; ³ Current address: National Veterinary Assay Laboratory, 1-15-1 Tokura, Kokubunji, Tokyo, 185-8511 Japan; ⁴ Corresponding author (email: matsuda@nval.go.jp)

ABSTRACT: Two histologic types of mammary cancer were encountered in an aged captive California sea lion (*Zalophus californianus*). A cancer with myoepithelial cell proliferation, which had metastasized to distant viscera, was located in the left cranial mammary region. Another cancer without myoepithelial cell proliferation was located in the right posterior mammary region, formed secondary nodules, and had metastasized to a regional lymph node. The presence of two different neoplasms in this sea lion is unusual.

Key words: California sea lion, cancer, case report, mammary gland, myoepithelium.

Reports of neoplasia in pinnipeds have been increasing recently (Brown, 1975; Moore and Stackhouse, 1978; Brown et al., 1980; Joseph and Cornell, 1986; Gulland et al., 1996; Sato et al., 1998; Acevedo-Whitehouse et al., 1999; Lipscomb et al., 2000). But few describe mammary tumors in California sea lions (*Zalophus californianus*; Simpson and Gardner, 1972; Landy, 1980). This report describes a case of two different histologic types of mammary carcinomas in a California sea lion.

The affected sea lion was a female estimated to be about 28 yr of age. It had been kept for >23 yr in a whale museum in Taiji-Machi, Wakayama Prefecture (33°35'55"N, 135°56'55"E) on the Pacific coast of Japan. Gradually it developed clinical signs including inappetence, depression, and emaciation. Several subcutaneous masses were present in the left thoracic and right inguinal regions. In the terminal stage, the sea lion coughed up white phlegm. Antibiotics and fluid therapy were not effective. The animal died 1.5 mo after the onset of clinical disease.

Necropsy revealed two mammary tumors. One of them, 9 cm in diameter, was

located in the left anterior mammary region (thoracic cancer) with a metastasis in the left axillary lymph node. Another neoplasm, 5 cm in diameter, was present in the right posterior mammary region (inguinal cancer) with metastatic nodules up to 1 cm in diameter in the right inguinal lymph node. Many distended ducts containing yellow greasy material were present surrounding the affected mammary regions. Numerous metastatic tumors, up to 1 cm in diameter, were scattered in lungs, pleura, mediastinum, and both kidneys.

Samples collected at necropsy were fixed in 10% formalin. Three micrometer-thick paraffin sections were cut and stained with hematoxylin and eosin (HE), Masson's trichrome, Watanabe's silver impregnation for reticulin, periodic acid Schiff reaction (PAS), and phosphotungstic acid hematoxylin (PTAH) stains. Frozen sections cut from formalin fixed tissue were stained with oil red O. Serial paraffin sections were also examined immunohistochemically using monoclonal antibodies to cytokeratin AE1/AE3 (Clones AE1, AE3 Boehringer Mannheim Biochemica, Mannheim, Germany), alpha-smooth muscle actin (alpha-SMA, Clone No.1A4, SIGMA Chemical Company, St. Louis, Missouri, USA), and vimentin (Clone V9, Dakopatts, Denmark). Reactions were visualized with peroxidase-conjugated streptavidin (Histofine SAB-PO Kit, Nichirei Corp., Tokyo, Japan), using diaminobenzidine as a substrate.

Surrounding both tumor masses were distended mammary ducts and acini that contain proteinaceous secretion. The thoracic cancer had solid nests, which consisted of varying ratios of epithelial to myo-

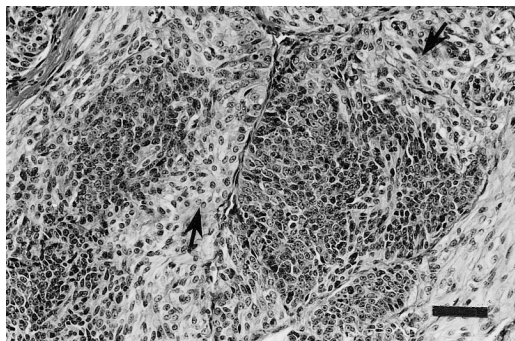


FIGURE 1. Photomicrograph of the complex carcinoma from the left anterior mammary region of a California sea lion. The nests consist of epithelial cell in the central area surrounded by spindle-shaped myoepithelium-like cells (arrows). HE stain. Scale bar=50 μ m.

epithelium-like cells (Fig. 1). Nests consisting entirely of myoepithelium-like cells were present. Within some nests, epithelial cells were clustered and surrounded by myoepithelium-like cells (Fig. 1). Epithelial cells formed a few incomplete glandular structures.

Epithelial tumor cells had moderately basophilic cytoplasm, a large round or ovoid nucleus with one or two prominent nucleoli and coarse granular chromatin. A high mitotic index (six mitotic figures/ten high power fields) was seen. Epithelial cells were positive for keratin, but negative for alpha-SMA (Fig. 2) and vimentin.

The myoepithelium-like cells were mainly short spindle-shaped and occasionally arranged in a stellate or reticulate pattern. They had vacuolated slightly eosinophilic cytoplasm and an ovoid or round nucleus with a small nucleolus and granular chromatin. One mitotic figure was seen per 10 high power fields. Filamentous material within the cytoplasm stained with PTAH. Cell cytoplasm was negative for PAS and oil red O stain. Most of the myoepithelium-like cells were positive for vimentin and less than half of them were positive for alpha-SMA (Fig. 2). All neoplastic nodules seen in the viscera had the same histologic features as the thoracic cancer with myoepithelium-like cell com-

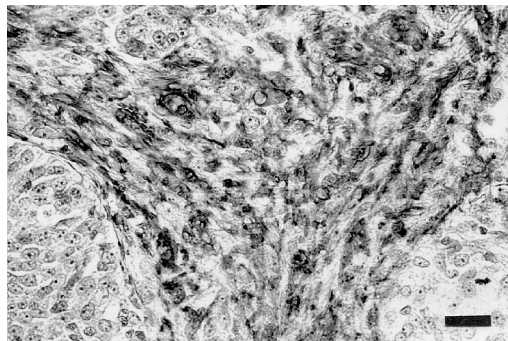


FIGURE 2. Photomicrograph of the complex carcinoma from the left anterior mammary region of a California sea lion. Myoepithelium-like cells were positive for alpha-SMA. Immunohistochemistry (alpha-SMA). Scale bar=30 μ m.

ponents. The thoracic cancer was diagnosed as complex carcinoma of mammary gland.

The inguinal cancer consisted of solid nests of epithelial cells with moderately basophilic cytoplasm (Fig. 3). Cells had a large round or ovoid nucleus with one or two nucleoli and coarse granular chromatin. Mitosis averaged four mitotic figures per 10 high power fields. The inguinal cancer cells were positive for keratin but negative for alpha-SMA and vimentin. The nodules and metastatic growth in the right inguinal lymph node showed the same histologic features as the inguinal cancer. The inguinal cancer was diagnosed as a simple mammary carcinoma.

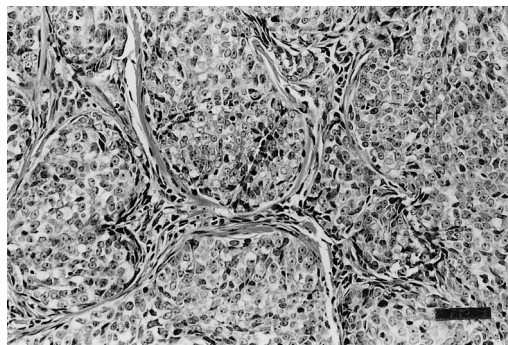


FIGURE 3. Photomicrograph of the carcinoma from the right posterior mammary region. The nests consist only of epithelial cells. HE stain. Scale bar=50 μ m.

There have been several reports of metastatic carcinoma of undetermined origin in California sea lions (Brown et al., 1980; Joseph and Cornell, 1986; Gulland et al., 1996). A recent report described the origin of the metastatic carcinomas as genital epithelium and that these were associated with a gammaherpesvirus (Lipscomb et al., 2000). The tumors in the present case were diagnosed as mammary carcinomas because the neoplastic growths were located in the subcutaneous tissues and surrounded by normal mammary glands. A few reports have described mammary tumors in California sea lions (Simpson and Gardner, 1972; Landy, 1980) with brief descriptions on histopathologic features.

The thoracic cancer metastasized to an axillary lymph node and distant visceral organs. The inguinal cancer formed secondary nodules locally and metastasized to a neighboring lymph node. Both types of mammary carcinomas of this case had only a small number of tubular or glandular structures. These two carcinomas were diagnosed as independent primary neoplasms because they had different morphologic characteristics, particularly regarding the myoepithelial component. Myoepithelial cell proliferation often occurs in canine mammary tumors (Moulton, 1990; Misdorp et al., 1999). The thoracic cancer with myoepithelial cell proliferation was similar to complex mammary cancer in the dog (Misdorp et al., 1999). However, thick layers of proliferating myoepithelial cells were found in metastatic lesions as well as in the primary tumor, which is in contrast to infrequent occurrence of myoepithelial proliferation in metastatic lesions in dogs. Diagnosis of multiple primary mammary carcinomas is unusual.

LITERATURE CITED

- ACEVEDO-WHITEHOUSE, K. A., F. CONSTANTINO-CASAS, D. AURIOLES-GAMBOA, H. A. RODRIGUEZ-MARTINEZ, AND C. R. GODINEZ-REYES. 1999. Hepatic carcinoma with spleen metastasis in a California sea lion from the Gulf of California. *Journal of Wildlife Diseases* 35: 565–568.
- BROWN, R. J. 1975. Renal fibrosarcoma in the northern fur seal. *Journal of Wildlife Diseases* 11: 23–25.
- , A. W. SMITH, G. V. MOREJOHN, AND R. L. DELONG. 1980. Metastatic adenocarcinoma in two California sea lions, *Zalophus c. californianus*. *Journal of Wildlife Diseases* 16: 261–266.
- GULLAND, F. M., J. G. TRUPKIEWICZ, T. R. SPRAKER, AND L. J. LOWENSTINE. 1996. Metastatic carcinoma of probable transitional cell origin in 66 free-living California sea lions (*Zalophus californianus*), 1979 to 1994. *Journal of Wildlife Diseases* 32: 250–258.
- JOSEPH, E. B., AND L. H. CORNELL. 1986. Metastatic squamous cell carcinoma in beached California sea lions (*Zalophus californianus*). *Journal of Wildlife Diseases* 22: 281–283.
- LANDY, R. B. 1980. A review of neoplasia in marine mammals. *In* The comparative pathology of zoo animals, R. J. Montali and G. Migaki (eds.). Smithsonian Institution Press, Washington, D.C., pp. 579–584.
- LIPSCOMB, T. P., D. P. SCOTT, R. L. GARBER, A. E. KRAFT, M. M. TSAI, J. H. LICHY, J. K. TAUBENBERGER, F. Y. SCHULMAN, AND F. M. GULLAND. 2000. Common metastatic carcinoma of California sea lions (*Zalophus californianus*): Evidence of genital origin and association with novel gammaherpesvirus. *Veterinary Pathology* 37: 609–617.
- MISDORP, W., R. W. ELSE, E. HELLMEN, AND T. P. LIPSCOMB. 1999. Histologic classification of mammary tumors of the dog and cat, 2nd Edition. Armed Forces Institute of Pathology Press, Washington, D.C., pp. 1–56.
- MOORE, J. J., AND L. L. STACKHOUSE. 1978. Pancreatic duct adenoma and strangulation of the small intestine in California sea lions. *Journal of Wildlife Diseases* 14: 445–446.
- MOULTON, J. E. 1990. Tumors of the mammary gland. *In* Tumors in domestic animals, 3rd Edition., University of California Press, Berkeley, pp. 544–545.
- SATO, S., H. KITAMURA, M. MORI, M. FUKAZAWA, M. TAKEDA, AND K. KADOTA. 1998. Adenocarcinoma of the lung in a Steller sea lion. *The Journal of Veterinary Medical Science* 60: 1349–1351.
- SIMPSON, J. G., AND M. B. GARDNER. 1972. Comparative microscopic anatomy of selected marine mammals. *In* Mammals of the sea—Biology and medicine, S. H. Ridgway (ed.). Charles C. Thomas, Springfield, Illinois, pp. 298–413.

Received for publication 3 December 2000.