



Pulmonary Mycoplasmosis in Farmed White-tailed Deer (*Odocoileus virginianus*)

Authors: Dyer, N. W., Krogh, D. F., and Schaan, L. P.

Source: Journal of Wildlife Diseases, 40(2) : 366-370

Published By: Wildlife Disease Association

URL: <https://doi.org/10.7589/0090-3558-40.2.366>

BioOne Complete (complete.BioOne.org) is a full-text database of 200 subscribed and open-access titles in the biological, ecological, and environmental sciences published by nonprofit societies, associations, museums, institutions, and presses.

Your use of this PDF, the BioOne Complete website, and all posted and associated content indicates your acceptance of BioOne's Terms of Use, available at www.bioone.org/terms-of-use.

Usage of BioOne Complete content is strictly limited to personal, educational, and non - commercial use. Commercial inquiries or rights and permissions requests should be directed to the individual publisher as copyright holder.

BioOne sees sustainable scholarly publishing as an inherently collaborative enterprise connecting authors, nonprofit publishers, academic institutions, research libraries, and research funders in the common goal of maximizing access to critical research.

Pulmonary Mycoplasmosis in Farmed White-tailed Deer (*Odocoileus virginianus*)

N. W. Dyer,¹ D. F. Krogh, and L. P. Schaen¹ Veterinary Diagnostic Laboratory, Veterinary Diagnostic Services Department, Van Es Laboratories, North Dakota State University, Fargo, North Dakota 58105, USA; ¹ Corresponding author (email: neil.dyer@ndsu.nodak.edu)

ABSTRACT: An outbreak of respiratory disease at a farmed cervid facility resulted in isolation and identification of *Mycoplasma bovis* in four affected white-tailed deer (*Odocoileus virginianus*) fawns. Microscopically, pulmonary lesions similar to those associated with *M. bovis* infections in calves, including lymphoplasmacytic peribronchiolar cuffing and caseonecrotic bronchiectasis, were present. *Arcanobacterium pyogenes* was recovered from lung tissue as well. This report indicates that *M. bovis* can be associated with respiratory disease in white-tailed deer.

Key words: Cervid, *Mycoplasma bovis*, *Odocoileus virginianus*, pneumonia, respiratory disease, white-tailed deer.

Four dead, 10-wk-old white-tailed deer (*Odocoileus virginianus*) fawns in good flesh were submitted to the North Dakota State University Veterinary Diagnostic Laboratory, Fargo, North Dakota, USA, from a farmed cervid facility near Brainerd, Minnesota (46°24'N, 94°8'W), USA, in October of 2002. The facility raises deer for the purposes of marketing urine as hunting bait. Approximately 300 animals were maintained on the grounds, and fawns were born on site. The fawns were maintained on pasture and a mixed ration (corn, oats, soybeans, peanuts, barley, sunflower seeds, and a vitamin/mineral mix). On the day of death, the fawns had been treated for parasites as part of a larger group. Deer were caught in box stalls and given oral albendazole (Valbazen®, Pfizer Animal Health, New York, New York, USA) and injectable ivermectin (Ivomec®, Merial, Duluth, Georgia, USA). Animals with clinical signs of respiratory disease (rales, dyspnea) were given tilmicosin (Micotil®, Elanco Animal Health, Indianapolis, Indiana, USA) injections. The herd had been treated with tetracycline (Terramycin®, Pfizer Animal Health) in the water

for the previous week due to signs of respiratory disease. Fawns were held in a box stall for a few minutes following treatment and then released. Within 10 min of their release, the fawns began to collapse with signs of respiratory distress and died.

At necropsy, all fawns had severe, bilateral, cranioventral pulmonary consolidation with disseminated miliary abscesses and fibrinous pleuritis (Fig. 1). Gross lesions in these four animals were confined to the lungs. Lung and other tissues from all four fawns were placed in 10% neutral buffered formalin, sectioned at 5 µm and stained routinely with hematoxylin and eosin. Significant microscopic changes included a severe, subacute to chronic, diffuse, purulent bronchopneumonia with multiple caseonecrotic foci (bronchiectasis). Most affected bronchioles lacked recognizable epithelium and were surrounded by prominent lymphoplasmacytic cuffs (Fig. 2). In addition to neutrophils, alveoli contained moderately increased numbers of macrophages, plasma cells, and lymphocytes. Interlobular septa were variably expanded by fibrinous exudate and mixed inflammatory cells. Alveolar walls were frequently expanded by congested capillaries, proteinic material, and mixed inflammatory cells. Parenchyma adjacent to foci of bronchiectasis was atelectatic. One lung had marked interstitial fibrosis.

Fluorescent antibody examination of frozen sections of lung (Hsiung, 1982) from the four fawns with pneumonia was negative for bovine adenovirus (BAV-5), infectious bovine rhinotracheitis virus (IBRV), bovine respiratory syncytial virus (BRSV), bovine viral diarrhea virus (BVDV), and parainfluenza (PI3V) virus antigens. Antibodies were from VMRD



FIGURE 1. Severe bronchopneumonia in a white-tailed deer (*Odocoileus virginianus*) fawn. Note the line of demarcation (arrows) between the consolidated and non-consolidated lung. H = heart.

(Pullman, Washington, USA; BAV-5) and USDA (National Veterinary Services Laboratory, Reagents Office, Ames, Iowa, USA; BRSV, BVDV, IBRV, PI3V, and BRSV). Lung tissue from these four fawns was submitted for bacterial culture. Samples were placed on TSA II 5% sheep blood (Becton Dickinson, Sparks, Maryland, USA) at O₂, 5% CO₂ and 15% CO₂, and MacConkey II (Becton Dickinson) at O₂, brain heart infusion broth (Becton Dickinson) at O₂ and *Mycoplasma* agar (Myco Plate, Vet Med Biological Media Services, UCD, Davis, California, USA) at 5% CO₂. Plates and broth were incubated in a moist chamber at 37 C. *Arcanobacterium pyogenes* (high numbers) and *Escherichia coli* (low numbers) were recovered from all four deer after 24 hr of incubation. At 48 hr, *Mycoplasma* plates examined under an inverted microscope (10×) showed typical fried-egg colonies. The *Mycoplasma* organism was submitted to a reference laboratory (California Ani-

mal Health and Food Safety Laboratory System, Tulare, California, USA) for speciation and was subsequently identified (immunofluorescence; Baas and Jasper, 1972) as *M. bovis*. Replicate sections of lung tissue from each fawn examined with *M. bovis*-specific antibody by immunohistochemistry (Haines et al., 2001) at a reference laboratory (Prairie Diagnostic Services, Saskatoon, Saskatchewan, Canada) were found to be positive.

Mycoplasma bovis is a recognized cause of calf pneumonia worldwide. Lesions in naturally affected calves are described as an exudative bronchopneumonia with foci of coagulative necrosis that are surrounded by mixed inflammatory cells, whereas experimentally infected calves had purulent bronchitis with peribronchiolar mononuclear cell cuffs (Brys et al., 1989; Rodriguez et al., 1996). In naturally infected calves, antigen was demonstrated around foci of coagulation necrosis, in necrotic exudate, and within phagocytic cells, while

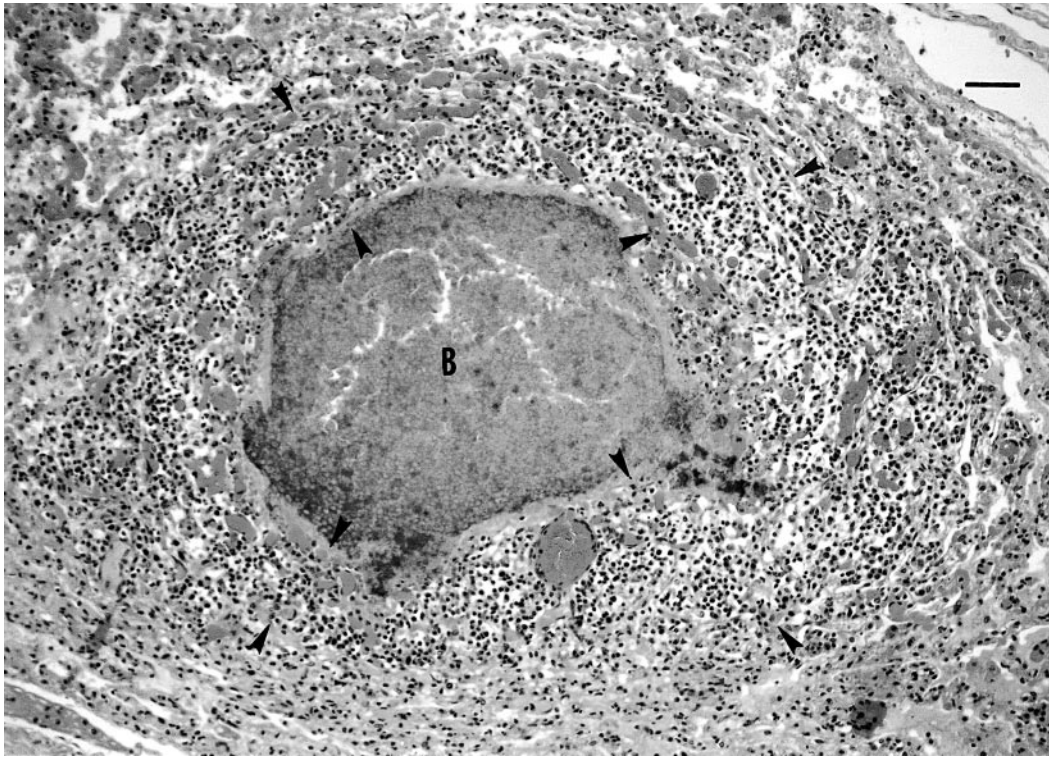


FIGURE 2. *Mycoplasma bovis* pneumonia in a white-tailed deer (*Odocoileus virginianus*) fawn. Note the caseonecrotic bronchiectasis (B) and lymphoplasmacytic peribronchiolar cuff (zone between arrows) surrounding the affected airway. Bar=200 μ m.

in experimentally infected animals antigen was found in airway epithelial cells, inflammatory cells, and alveolar walls (Adeboye et al., 1995). In the fawns, *M. bovis* antigen was detected in caseonecrotic foci associated with bronchiectasis, both in luminal exudate and remaining epithelial cells, which is consistent with findings in naturally infected calves.

Pyogranulomatous synovitis, tenosynovitis, periartthritis, and otitis have been associated with *M. bovis* pneumonia in calves and feedlot cattle (Adeboye et al., 1996; Walz et al., 1997; Haines et al., 2001); however, such lesions were not observed in these deer. Studies in calves experimentally infected with both *M. bovis* and BRSV found no increase in the severity of lesions in coinfecting calves (Thomas et al., 1986). A coinfection with *Mannheimia hemolytica* induced a moderate increase in lesion severity (Gourlay and

Houghton, 1995) but only when calves were infected with *M. bovis* 24 hr prior to infection with *M. hemolytica*. *Mycoplasma bovis* pneumonia in calves is typically more severe when multiple pathogens, particularly *M. hemolytica*, *Pasteurella multocida*, and *Hemophilus somnus*, are involved (Bucharova and Vesselinova, 1989). Studies using *Mycoplasma dispar* indicate the pathogenesis of *Mycoplasma* pneumonia in calves involves degeneration and impairment of ciliated respiratory epithelial cells, thereby predisposing the lung to secondary infection with additional pathogens (Almeida and Rosenbusch, 1994).

Pneumonia caused by *M. bovis* has not previously been reported in white-tailed deer (Whithear, 2001). A report of *Mycoplasma* pneumonia in a Thomson's gazelle (*Gazella thomsoni*) described the microscopic changes as a "cuffing pneumonia" (Watson and Slocombe, 1986). *Arcanobac-*

terium pyogenes has been associated with disease in white-tailed deer and was isolated from animals with intracranial abscesses and meningoencephalitis (Davidson et al., 1990; Bauman et al., 2001). A recent case report of *A. pyogenes* septicemia in white-tailed deer detailed similar but more severe lung lesions than were seen in these fawns (Turnquist and Fales, 1998). Studies in calves have associated *M. bovis* with respiratory disease outbreaks of increased severity (Gourlay et al., 1989). Based on the characteristic *Mycoplasma*-associated lesions seen in these fawns, it is likely the pneumonia was more severe due to the synergistic effect of *M. bovis* and *A. pyogenes*. The peracute death of the fawns can be attributed to the severe pulmonary lesions and stress associated with handling. Even though FA examinations for viruses were negative, a possible predisposing viral infection cannot be eliminated. Sero-surveys for bovine viral agents conducted on North American white-tailed deer (Ingebrigtsen et al., 1986; Sadi et al., 1991) report seroconversion, but provide little information on actual disease caused by these agents. Systemic adenovirus infection is well-described in mule deer (*Odocoileus hemionus*) (Woods et al., 1996), black-tailed deer (*Odocoileus hemionus columbianus*) (Woods et al., 1999), and white-tailed deer (Sorden et al., 2000; Woods et al., 2001); however, the reported lesions of pulmonary edema, hemorrhagic enteropathy, and vasculitis along with typical viral inclusion bodies were not observed in these fawns. Immunohistochemistry and virus isolation for adenovirus was not attempted. A definitive means of exposure to the *Mycoplasma* organism was not established. The premises are fully fenced, but nose-to-nose contact with wild deer is possible. The nearest cattle are separated by a gravel road. Certainly, any animals introduced to the herd could represent sources of *M. bovis* infection. This case indicates that *M. bovis* can be associated with severe respiratory disease in white-tailed deer and should be a patho-

gen of consideration in wildlife and the farmed cervid industry.

LITERATURE CITED

- ADEBOYE, D. S., P. G. HALBUR, D. L. CAVANAUGH, R. E. WERDIN, C. C. CHASE, D. W. MISKIMINS, AND R. F. ROSENBUSCH. 1995. Immunohistochemical and pathological study of *Mycoplasma bovis*-associated lung abscesses in calves. *Journal of Veterinary Diagnostic Investigation* 7: 333–337.
- , ———, R. G. NUTSCH, R. G. KADLEC, AND R. F. ROSENBUSCH. 1996. *Mycoplasma bovis*-associated pneumonia and arthritis complicated with pyogranulomatous tenosynovitis in calves. *Journal of the American Veterinary Medical Association* 209: 647–649.
- ALMEIDA, R. A., AND R. F. ROSENBUSCH. 1994. Impaired tracheobronchial clearance of bacteria in calves infected with *Mycoplasma dispar*. *Zentralblatt für Veterinärmedizin* 41: 473–482.
- BAAS, E. J., AND D. E. JASPER. 1972. Agar block technique for identification of mycoplasmas by use of fluorescent antibody. *Applied Microbiology* 23: 1097–1100.
- BAUMANN, C. D., W. R. DAVIDSON, D. E. ROSCOE, AND K. BEHELER-AMASS. 2001. Intracranial abscessation in white-tailed deer of North America. *Journal of Wildlife Diseases* 37: 661–670.
- BRYN, A., H. GUNTHER, AND D. SCHIMMEL. 1989. Experimental *Mycoplasma bovis* infection of the respiratory tract of calves. *Archiv für Experimentelle Veterinärmedizin* 43: 667–676.
- BUCHAROVA, Y., AND A. VESSELINOVA. 1989. On the aetiopathogenesis of *Mycoplasma pneumoniae* in calves. *Archiv für Experimentelle Veterinärmedizin* 43: 685–689.
- DAVIDSON, W. R., V. F. NETTLES, L. E. HAYES, E. W. HOWERTH, AND C. E. COUVILLION. 1990. Epidemiologic features of an intracranial abscessation/suppurative meningoencephalitis complex in white-tailed deer. *Journal of Wildlife Diseases* 26: 460–467.
- GOURLAY, R. N., AND S. B. HOUGHTON. 1995. Experimental pneumonia in conventionally reared and gnotobiotic calves by dual infection with *Mycoplasma bovis* and *Pasteurella haemolytica*. *Research in Veterinary Science* 38: 377–382.
- , L. H. THOMAS, AND S. G. WYLD. 1989. Increased severity of calf pneumonia associated with appearance of *Mycoplasma bovis* in a rearing herd. *The Veterinary Record* 124: 420–422.
- HAINES, D. B., K. M. MARGIN, E. G. CLARK, G. K. JIM, AND E. D. JANZEN. 2001. The immunohistochemical detection of *Mycoplasma bovis* and bovine viral diarrhoea virus in tissues of feedlot cattle with chronic, unresponsive respiratory disease and/or arthritis. *Canadian Veterinary Journal* 42: 857–860.

- HSIUNG, G. D. 1982. Diagnostic virology, 3rd Edition, Yale University Press, New Haven, Connecticut, pp. 60–61.
- INGEBRIGSTEN, D. K., J. R. LUDWIG, AND A. W. MCCLURKIN. 1986. Occurrence of antibodies to the etiologic agents of infectious bovine rhinotracheitis, parainfluenza 3, leptospirosis, and brucellosis in white-tailed deer in Minnesota. *Journal of Wildlife Diseases* 22: 83–86.
- RODRIGUEZ, F., D. G. BRYSON, H. J. BALL, AND F. FORSTER. 1996. Pathological and immunohistochemical studies of natural and experimental *Mycoplasma bovis* pneumonia in calves. *Journal of Comparative Pathology* 115: 151–162.
- SADI, L., R. JOYAL, M. ST.-GEORGES, AND L. LAMONTAGNE. 1991. Serologic survey of white-tailed deer on Anticosti Island, Quebec, for bovine herpesvirus 1, bovine viral diarrhea, and parainfluenza 3. *Journal of Wildlife Diseases* 27: 569–577.
- SORDEN, S. D., L. W. WOODS, AND H. D. LEHMKUHL. 2000. Fatal pulmonary edema in white-tailed deer (*Odocoileus virginianus*) associated with adenovirus infection. *Journal of Veterinary Diagnostic Investigation* 12: 378–380.
- THOMAS, L. H., C. J. HOWARD, E. J. SCOTT, AND K. R. PARSONS. 1986. *Mycoplasma bovis* infection in gnotobiotic calves and combined infection with respiratory syncytial virus. *Veterinary Pathology* 23: 571–578.
- TURNQUIST, S. E., AND W. H. FALES. 1998. *Actinomyces pyogenes* infection in a free-ranging white-tailed deer. *Journal of Veterinary Diagnostic Investigation* 10: 86–89.
- WALZ, P. H., T. P. MULLANEY, J. A. RENDER, R. D. WALKER, T. MOSSER, AND J. C. BAKER. 1997. *Otitis media* in preweaned Holstein dairy calves in Michigan due to *Mycoplasma bovis*. *Journal of Veterinary Diagnostic Investigation* 9: 250–254.
- WATSON, G. L., AND R. F. SLOCOMBE. 1986. Mycoplasmosis in a Thomson's gazelle. *Veterinary Pathology* 23: 329–331.
- WHITHEAR, K. G. 2001. Diseases due to mycoplasmas. In *Infectious diseases of wild mammals*, 3rd Edition, E. S. Williams and I. K. Barker (eds.). Iowa State University Press, Ames, Iowa, pp. 413–422.
- WOODS, L. W., P. K. SWIFT, B. C. BARR, M. C. HORIZINEK, R. W. NORDHAUSEN, M. H. STILLIAN, J. F. PATTON, M. N. OLIVER, K. R. JONES, AND N. J. MACLACHLAN. 1996. Systemic adenovirus infection associated with high mortality in mule deer (*Odocoileus hemionus*) in California. *Veterinary Pathology* 33: 125–132.
- , R. S. HANLEY, P. H. CHIUR, H. D. LEHMKUHL, R. W. NORDHAUSEN, M. H. STILLIAN, AND P. K. SWIFT. 1999. Lesions and transmission of experimental adenovirus hemorrhagic disease in black-tailed deer fawns. *Veterinary Pathology* 36: 100–110.
- , H. D. LEHMKUHL, P. K. SWIFT, P. H. CHIU, R. S. HANLEY, R. W. NORDHAUSEN, M. H. STILLIAN, AND M. L. DREW. 2001. Experimental adenovirus hemorrhagic disease in white-tailed deer fawns. *Journal of Wildlife Diseases* 37: 153–158.

Received for publication 9 June 2003.