



Leptospirosis in Northern Elephant Seals (*Mirounga angustirostris*) Stranded along the California Coast

Authors: Colegrove, Kathleen M., Lowenstine, Linda J., and Gulland, Frances M. D.

Source: Journal of Wildlife Diseases, 41(2) : 426-430

Published By: Wildlife Disease Association

URL: <https://doi.org/10.7589/0090-3558-41.2.426>

BioOne Complete (complete.BioOne.org) is a full-text database of 200 subscribed and open-access titles in the biological, ecological, and environmental sciences published by nonprofit societies, associations, museums, institutions, and presses.

Your use of this PDF, the BioOne Complete website, and all posted and associated content indicates your acceptance of BioOne's Terms of Use, available at www.bioone.org/terms-of-use.

Usage of BioOne Complete content is strictly limited to personal, educational, and non-commercial use. Commercial inquiries or rights and permissions requests should be directed to the individual publisher as copyright holder.

BioOne sees sustainable scholarly publishing as an inherently collaborative enterprise connecting authors, nonprofit publishers, academic institutions, research libraries, and research funders in the common goal of maximizing access to critical research.

SHORT COMMUNICATIONS

Journal of Wildlife Diseases, 41(2), 2005, pp. 426–430
© Wildlife Disease Association 2005

Leptospirosis in Northern Elephant Seals (*Mirounga angustirostris*) Stranded along the California Coast

Kathleen M. Colegrove,^{1,4} Linda J. Lowenstine,² and Frances M. D. Gulland³ ¹ Veterinary Medical Teaching Hospital, One Shields Ave., University of California, Davis, California 95616, USA; ² Department of Pathology, Microbiology and Immunology, School of Veterinary Medicine, One Shields Ave., University of California, Davis, California 95616, USA; ³ The Marine Mammal Center, Marin Headlands, Sausalito, California 94965, USA; ⁴ Corresponding author (email: kmcolegrove@ucdavis.edu)

ABSTRACT: Leptospirosis was identified in six northern elephant seals (*Mirounga angustirostris*) that were stranded in 1995 along the coast of California (USA). Histologic lesions in all seals included tubulointerstitial nephritis with tubular degeneration and necrosis. Infection was confirmed through identification of spirochetes using an immunohistochemical stain for *Leptospira* sp. antigens. One affected seal had an elevated titer to *Leptospira interrogans* serovar pomona. Four of the six seals developed leptospirosis during rehabilitation, and two seals had evidence of exposure in the wild. Potential sources of infection during rehabilitation include other elephant seals, California sea lions (*Zalophus californianus*), Pacific harbor seals (*Phoca vitulina richardsii*), or free-ranging wildlife. These results indicate that northern elephant seals are susceptible to leptospirosis and can develop disease both in the natural environment and in a rehabilitation setting.

Key words: Immunohistochemistry, *Leptospira interrogans* serovar pomona, leptospirosis, *Mirounga angustirostris*, nephritis, northern elephant seal.

Leptospirosis is an ubiquitous disease that affects humans and a wide range of domestic and wild animal species. Among marine mammal species, leptospirosis has most frequently been reported in two otariids in the eastern North Pacific Ocean, California sea lions (*Zalophus californianus*) and northern fur seals (*Callorhinus ursinus*). Accounts of leptospirosis in phocids are restricted to two reports documenting infection in four Pacific harbor seals (*Phoca vitulina richardsii*) (Stamper et al., 1998; Stevens et al., 1999). In California sea lions and northern fur seals, infection is caused by *Leptospira interrogans* serovar pomona, whereas infection in harbor seals has been reported due

to *L. kirschneri grippotyphosa* (formally *L. interrogans* serovar grippotyphosa) (Smith et al., 1977; Gulland et al., 1996; and Stamper et al., 1998). Leptospirosis is endemic in California sea lions along the California coast (USA), where periodic epizootics can result in large numbers of animals stranding due to renal disease (Colagross-Schouten et al., 2002). Clinical signs of infection in California sea lions include depression, dehydration, polydipsia, vomiting, and reluctance to use the hind flippers (Gulland et al., 1996). Although northern elephant seals (*Mirounga angustirostris*) have the same range as California sea lions and harbor seals along the California coast, and there is direct contact between these species on some California rookeries (Odell, 1971), leptospirosis has not been reported from elephant seals. In a previous study of leptospirosis in harbor seals by Stamper et al. (1998), three elephant seals housed at the rehabilitation facility had high antibody titers to *L. interrogans* serovar bratislava and *L. kirschneri grippotyphosa*. No signs of renal disease were noted in these animals and all were released following rehabilitation. The aim of this study was to characterize the clinical signs, biochemical abnormalities, serologic responses, and pathologic lesions associated with leptospiral infection in free-ranging and rehabilitated elephant seals.

Medical records from The Marine Mammal Center, Sausalito, California (USA), a rehabilitation center, were reviewed for all northern elephant seals that stranded live between January, 1992 and December, 2001 along the central Califor-

nia coast (37°42'N, 123°05'W to 35°59'N, 121°30'W). Parameters evaluated included appearance at stranding, clinical signs, complete blood count, serum chemistry profiles, and gross and histopathologic findings. Based on serum biochemistry data, six elephant seals were identified that had renal disease of unknown etiology. Four of these seals were females and two were males. All six seals stranded between 4 April 1995 and 12 July 1995. Age at stranding (ranging from 3 mo to 3 yr) was determined using date, standard length, weight, tooth development, and pelage (Gerber et al., 1993). Clinical signs prior to death or euthanasia included weight loss, dehydration, anorexia, and moderate to severe lethargy. Similar biochemical abnormalities were found in blood samples taken from each of the six seals. These abnormalities included elevated blood urea nitrogen (range 80–266 mg/dl, reference range 33–76 mg/dl); serum creatinine (range 1.0–3.8 mg/dl, reference range 0.2–0.8 mg/dl); sodium (range 150–306 mEq/l, reference range 143–154 mEq/l); phosphorus (range 11.5–16.2 mg/dl, reference range 6.6–9.9 mg/dl); and calcium (range 8.6–13.1 mg/dl, reference range 10.2–12.8 mg/dl) levels (Bossart et al., 2001). These abnormalities are similar to the biochemical abnormalities observed in California sea lions with leptospirosis (Gulland et al., 1996) and are consistent with severe renal disease. No hematologic abnormalities were identified in any of the six seals.

Gross necropsy findings were similar in all seals and included swollen kidneys with pale cortices and loss of renicular and corticomedullary differentiation. Tissue samples from major organs collected at necropsy were placed in 10% neutral buffered formalin, processed routinely for paraffin embedding, sectioned at 5 μ m, and stained with hematoxylin and eosin (Luna, 1968). Histologically, all six seals had tubulointerstitial nephritis with varying degrees of renal tubular degeneration, necrosis, and regeneration. Moderate to large numbers of lymphocytes, plasma cells, and

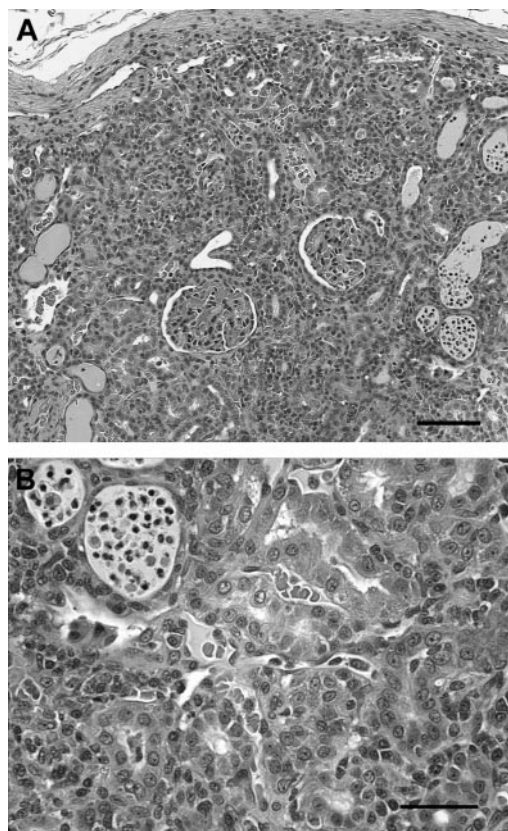


FIGURE 1. Photomicrograph of a hematoxylin and eosin-stained section of renal cortex from an elephant seal diagnosed with leptospirosis. A. Note the prominent tubular ectasia, tubular epithelial necrosis, and tubulointerstitial inflammation. Bar = 100 μ m. B. Higher magnification photomicrograph illustrating tubular ectasia with intratubular proteinaceous fluid, necrotic epithelial cells, and neutrophils. There are moderate numbers of lymphocytes and plasma cells in the cortical interstitium. Bar = 50 μ m.

histiocytes were present in the cortical interstitium. Multiple tubules were dilated, lined by flattened epithelial cells, and contained protein casts, sloughed epithelial cells, and moderate numbers of neutrophils (Fig. 1). The histologic characteristics of the renal lesions in the six elephant seals were similar to lesions reported in California sea lions with leptospirosis (Gulland et al., 1996). In all six seals, renal disease was determined to be the primary factor in the animal's clinical disease and death. Other significant lesions identified included *Otostrongylus circumlitus*—associated ar-

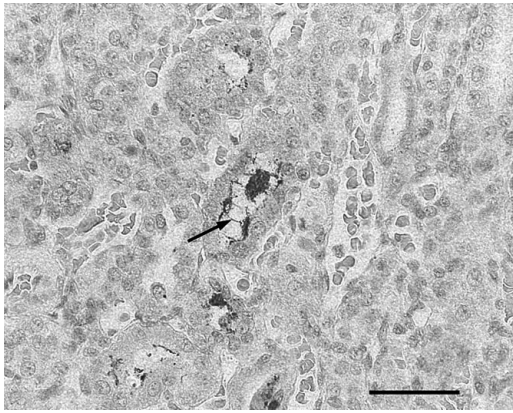


FIGURE 2. Photomicrograph of a section of elephant seal kidney labeled with antibodies directed against *Leptospira* sp. Note the positive staining of leptospires (arrow) in the renal tubules and the globular staining within tubular epithelial cells. Bar = 50 μ m.

teritis ($n=1$) (Gulland et al., 1997), interstitial pneumonia ($n=1$), and enterocolitis ($n=2$).

Using the Warthin–Starry method (pH 4.0) on sections of kidney (Luna, 1968), spirochetes were identified in the renal cortex in four of the six seals. Nonspecific staining of large amounts of necrotic debris might have obscured the spirochetes in the remaining two animals. Immunohistochemical staining was performed using an established streptavidin–biotin staining protocol (Tizard, 1987). The *Leptospira*-specific polyclonal antibody (National Veterinary Services Laboratory, Ames, Iowa, USA) is directed against *L. interrogans* serovars bratislava, canicola, hardjo, icterohemorrhagiae, and pomona, and *L. kirschneri grippotyphosa*. Variable numbers of spirochetes were identified within the lumens of renal tubules in all six seals via immunohistochemistry. Positive granular staining of antigen was observed within numerous tubular epithelial cells and within intertubular inflammatory cells (Fig. 2). This staining pattern is similar to previous reports in both experimentally infected and naturally exposed species (Pereira et al., 1997; Yener and Keles, 2001; Wild et al., 2002), and might vary with chronicity

of infection. The staining of antigen in all samples was most prominent in areas of interstitial inflammation.

The microscopic agglutination test (MAT) was performed on serum that had been banked at -70 C from two of the six elephant seals with histologic evidence of leptospirosis to determine possible exposure to *L. interrogans* serovars bratislava, canicola, hardjo, icterohemorrhagiae, and pomona, and *L. kirschneri grippotyphosa* (Colagross-Schouten et al., 2002). One seal had a positive serologic titer of 3200 to *L. interrogans* serovar pomona at the time of admission to the rehabilitation center, indicating that exposure occurred prior to stranding. The seal had normal hematologic and serum biochemical parameters at admission but developed clinical and biochemical evidence of renal disease 10 days after entering rehabilitation. The other infected seal tested had a negative serologic titer (<100) prior to developing clinical signs of disease, suggesting that infection and seroconversion occurred during rehabilitation. Additional banked serum was analyzed from 26 elephant seals and two California sea lions housed at the rehabilitation center at the same time as the six infected seals, to determine possible exposure sources. Two other elephant seals had elevated serologic titers to *Leptospira* sp. One seal had a titer of 1600 to *L. interrogans* serovar pomona and 200 to *L. interrogans* serovar bratislava, whereas the other seal had a titer of 200 to *L. kirschneri grippotyphosa*. Neither of these seals had clinical evidence of renal disease and both were released following rehabilitation. At no time were these seals housed with any of the six seals with leptospirosis. Both California sea lions evaluated had negative serologic titers.

One of the six seals with histologic evidence of infection died within two days of stranding and had no known contact with other captive seals. A 4 to 10 day interval between exposure and leptospiral bacteremia has been reported for cattle and dogs (Thierman, 1984; Greene et al., 1998) sug-

gesting that this seal was most likely infected prior to arriving at the center, although the time course of infection in marine mammals is unknown. Both this seal and the seal with a positive titer at admission provide evidence that leptospirosis also occurs in free ranging northern elephant seals.

Four of the six infected seals developed clinical evidence of renal disease during the course of rehabilitation, suggesting that exposure occurred during hospitalization. At admission, each of the four seals was underweight and debilitated; however, none had hematologic or serum biochemical evidence of renal disease. In these seals, the time from stranding to onset of clinical signs ranged from 14 to 80 days. Potential on-site exposure sources include California sea lions, harbor seals, or other elephant seals undergoing rehabilitation. Terrestrial wildlife, such as raccoons (*Procyon lotor*), skunks (*Mephitis* sp. and *Spilogale* sp.), and field mice (*Peromyscus* sp.), in the area surrounding the rehabilitation center could also be potential exposure sources. None of the seals were housed with the two seals with evidence of exposure prior to hospitalization. Two of the four seals were housed in the same enclosure for several days. One of these seals developed clinical disease within seven days of being in the enclosure, suggesting that transmission might have occurred between these seals while housed together. Three California sea lions housed at the rehabilitation center during the same period as the six elephant seals had clinical evidence of leptospirosis. Although different species are always housed separately during rehabilitation, cross contamination of enclosures could have occurred through sanitation equipment or water runoff between enclosures. Hospitalized pinnipeds are housed in enclosures that have freshwater pools on a closed circulation system. Water is treated by sand filtration, ozonation, and chlorination prior to distribution to individual pools. It is unlikely, therefore, that a single contaminated water source

was the cause of infection in the hospitalized elephant seals.

In this study, leptospirosis was only diagnosed in elephant seals during a five-month span between April and July 1995. This period corresponds to the season during which the majority of elephant seals strand along the California coast (Gulland et al., 1997). Elephant seals have not been routinely screened for serologic titers against *Leptospira* sp.; therefore, subclinical infection may have been missed previously. A large number of California sea lions were diagnosed with leptospirosis in fall, 1995 (Gulland, pers. comm.), therefore, leptospires might have been more prevalent in the environment during this period. Environmental survival of leptospires might be affected by rainfall and climatic conditions altering temperature (Ward, 2002). Periodic outbreaks of leptospirosis in California sea lions have previously been associated with prior El Niño events (Gulland et al., 1996) and an El Niño event occurred between 1991–1994 along the California coast (Trenberth and Hoar, 1996). Epidemics of leptospirosis in California sea lions have also been hypothesized to be related to relative increases in the proportion of susceptible, non-immune animals in the population (Gulland et al., 1996). Transmission between California sea lions and elephant seals could occur naturally, as these species often haul out in close proximity on rookeries (Odell, 1971).

In conclusion, this study demonstrates that northern elephant seals are susceptible to leptospirosis and illustrates the utility of immunohistochemistry in confirmation of infection. Serologic sampling of wild elephant seal populations is needed to better assess the prevalence of exposure to leptospirosis in the wild. Thorough post mortem evaluation, coupled with serologic sampling of stranded elephant seals undergoing rehabilitation, should also be accomplished to identify potential carriers of leptospiral organisms. Polymerase chain reaction (PCR) has recently been used in

domestic species to diagnosis infection and identify urinary shedding of leptospires (Harkin et al., 2003). Similar techniques could be used to further investigate the epidemiology of leptospirosis in both captive and free-ranging pinnipeds.

We thank the staff and volunteers of The Marine Mammal Center for the care of the animals, Denise Greig for sample collection, Diane Naydan for immunohistochemistry, and the Arthur and Elena Court Nature Conservancy for their financial support.

LITERATURE CITED

- BOSSART, G. D., T. H. REIDARSON, L. A. DIERAUF, AND D. A. DUFFIELD. 2001. Clinical pathology. In CRC Handbook of marine mammal medicine, 2nd Edition, L. A. Dierauf and F. M. D. Gulland (eds.). CRC Press, Boca Raton, Florida, pp. 383–436.
- COLAGROSS-SCHOUTEN, A. M., J. A. K. MAZET, F. M. D. GULLAND, M. A. MILLER, AND S. HIETALA. 2002. Diagnosis and seroprevalence of leptospirosis in California sea lions from coastal California. *Journal of Wildlife Diseases* 38: 7–17.
- GERBER, J. A., J. ROLETTO, L. E. MORGAN, D. M. SMITH, AND L. J. GAGE. 1993. Findings in pinnipeds stranded along the central and northern California coast, 1984–1990. *Journal of Wildlife Diseases* 29: 423–433.
- GREENE, C. E., M. A. MILLER, AND C. A. BROWN. 1998. Leptospirosis. In *Infectious diseases of the dog and cat*, 2nd Edition, C. E. Green (ed.). W.B. Saunders Company, St. Louis, Missouri, pp. 273–281.
- GULLAND, F. M. D., M. KOSKI, L. J. LOWENSTINE, A. COLAGROSS, L. MORGAN, AND T. SPRAKER. 1996. Leptospirosis in California sea lions (*Zalophus californianus*) stranded along the central California coast, 1981–1994. *Journal of Wildlife Diseases* 32: 572–580.
- , K. BECKMEN, K. BUREK, L. LOWENSTINE, L. WERNER, T. SPRAKER, M. DAILEY, AND E. HARRIS. 1997. Nematode (*Otostrongylus circumlitus*) infestation of Northern elephant seals (*Mirounga angustirostris*) stranded along the Central California coast. *Marine Mammal Science* 13: 446–459.
- HARKIN, K. R., Y. M. ROSHTO, J. T. SULLIVAN, T. J. PURVIS, AND M. M. CHENGAPPA. 2003. Comparison of polymerase chain reaction assay, bacteriologic culture, and serologic testing in assessment of prevalence of urinary shedding of leptospires in dogs. *Journal of the American Veterinary Medical Association* 222: 1228–1233.
- LUNA, L. G. 1968. Manual of histologic staining methods of the Armed Forces Institute of Pathology. 3rd Edition. McGraw-Hill Company, New York, New York, 258 pp.
- ODELL, D. K. 1971. Censuses of pinniped breeding on the California Channel Islands. *Journal of Mammalogy* 52: 187–90.
- PEREIRA, M. M., J. ANDRADE, M. D. LACERDA, N. M. BATORÉU, R. S. MARCHEVSKY, AND R. R. DOS SANTOS. 1997. Demonstration of leptospiral antigens on tissues using monoclonal antibodies and avidin-biotin peroxidase staining. *Experimental Toxicologic Pathology* 49: 505–511.
- SMITH, A. W., R. J. BROWN, D. E. SKILLING, H. L. BRAY, AND M. C. KEYES. 1977. Naturally-occurring leptospirosis in northern fur seals (*Callorhinus ursinus*). *Journal of Wildlife Diseases* 13: 144–148.
- STAMPER, M. A., F. M. D. GULLAND, AND T. SPRAKER. 1998. Leptospirosis in rehabilitated Pacific harbor seals from California. *Journal of Wildlife Diseases* 34: 407–410.
- STEVENS, E., T. P. LIPSCOMB, AND F. M. D. GULLAND. 1999. An additional case of leptospirosis in a harbor seal. *Journal of Wildlife Diseases* 35: 150.
- THIERMANN, A. B. 1984. Leptospirosis: Current developments and trends. *Journal of the American Veterinary Medical Association* 184: 722–725.
- TIZARD, I. 1987. *Veterinary immunology: An introduction*, 3rd Edition. W. B. Saunders Company, Philadelphia, Pennsylvania, 401 pp.
- TRENBERTH, K. E., AND T. J. HOAR. 1996. The 1990–1995 El Niño–Southern Oscillation event: Longest on record. *Geophysical Research Letters* 23: 57–60.
- WARD, M. P. 2002. Seasonality of canine leptospirosis in the United States and Canada and its association with rainfall. *Preventative Veterinary Medicine* 56: 203–213.
- WILD, C. J., J. J. GREENLEE, C. A. BOLIN, J. K. BARNETT, D. A. HAAKE, AND N. F. CHEVILLE. 2002. An improved immunohistochemical diagnostic technique for canine leptospirosis using antileptospiral antibodies on renal tissue. *Journal of Veterinary Diagnostic Investigation* 14: 20–24.
- YENER, Z., AND H. KELES. 2001. Immunoperoxidase and histopathological examination of leptospiral nephritis in cattle. *Journal of Veterinary Medicine*, A 48: 441–447.

Received for publication 4 March 2004.