

Gastric Cryptosporidiosis in a Wild Frilled Lizard From Australia

Authors: Orós, Jorge, Rodríguez, José Luis, and Patterson-Kane, Janet

Source: Journal of Wildlife Diseases, 34(4) : 807-810

Published By: Wildlife Disease Association

URL: <https://doi.org/10.7589/0090-3558-34.4.807>

BioOne Complete (complete.BioOne.org) is a full-text database of 200 subscribed and open-access titles in the biological, ecological, and environmental sciences published by nonprofit societies, associations, museums, institutions, and presses.

Your use of this PDF, the BioOne Complete website, and all posted and associated content indicates your acceptance of BioOne's Terms of Use, available at www.bioone.org/terms-of-use.

Usage of BioOne Complete content is strictly limited to personal, educational, and non - commercial use. Commercial inquiries or rights and permissions requests should be directed to the individual publisher as copyright holder.

BioOne sees sustainable scholarly publishing as an inherently collaborative enterprise connecting authors, nonprofit publishers, academic institutions, research libraries, and research funders in the common goal of maximizing access to critical research.

Gastric Cryptosporidiosis in a Wild Frilled Lizard From Australia

Jorge Orós,^{1,3} José Luis Rodríguez,¹ and Janet Patterson-Kane,² ¹ Department of Histology and Pathology, Veterinary Faculty ULPGC, Trasmontaña, 35416 Arucas (Las Palmas), Canary Islands, Spain; ² Department of Pathobiology, College of Veterinary Medicine, University of Florida, P. O. Box 110880, Gainesville, Florida 32611-0880, USA; and ³ Corresponding author (e-mail: oros@infovia.ulpgc.es).

ABSTRACT: An adult male frilled lizard (*Chlamydosaurus kingi*) was found dead in Northern Territory (Australia). On physical examination it was found to be severely emaciated. At necropsy the stomach was found to be firm with mild thickening of the gastric mucosa. Gastric rugae were prominent and the mucosa was red with a thin layer of dark red mucus on its surface. Light microscopic examination revealed a mild diffuse gastritis with infiltration of the lamina propria by lymphocytes, plasma cells, and heterophils. Large numbers of small, round amphophilic to basophilic (2 to 4 μm in diameter) organisms morphologically consistent with cryptosporidia were seen on the surface of the mucosal epithelium and free in the gastric lumen. The gastric lesions seen in this frilled lizard did not involve atrophy, as previously described in lizards with gastric cryptosporidiosis, and were similar to those described in snakes. The possibility that more than one species of *Cryptosporidium* parasitizes reptiles could explain the different lesions. This is the first report of cryptosporidiosis in a frilled lizard.

Key words: Case report, *Chlamydosaurus kingi*, cryptosporidiosis, *Cryptosporidium* sp., frilled lizard.

Cryptosporidia are small, 4–8 μm protozoa belonging to the phylum Apicomplexa that parasitize the gastrointestinal tract and occasionally other organ systems in humans and many species of animals, including domestic and exotic mammals, birds, fish, and reptiles (Heuschele et al., 1986; O'Donoghue, 1995). The first confirmed report of *Cryptosporidium* sp. in reptiles described infections in 14 snakes belonging to four species and three genera (*Elaphe*, *Crotalus*, and *Sansinia*) at the Baltimore Zoo (Brownstein et al., 1977) in the USA. Since then, infections have been reported in over 58 different reptilian species including 40 species of snakes (boids, colubrids, elapids, and viperids), 15 species of lizards (agamids, gekkonids, chamaeleonids, helodermatids, lacertids, teiids, and varanids), and two species of

tortoises (both testudinids) worldwide (O'Donoghue, 1995). Recently, *Cryptosporidium* sp. oocysts were identified in fecal and intestinal samples from free-ranging sea turtles (*Chelonia mydas*) from the Hawaiian Islands (USA) (Graczyk et al., 1997). No infections have been reported in crocodylians (Carmel and Groves, 1993). To date, the only reported case of cryptosporidial disease in amphibians is a positive fecal examination of an American toad (*Bufo* sp.) (Cranfield and Graczyk, 1996).

It is likely that more than one species of *Cryptosporidium* occurs in reptiles (Upton et al., 1989). Nearly all infections in snakes have been associated with chronic gastric disease (O'Donoghue, 1995), although recently a case of biliary cryptosporidiosis in two corn snakes (*Elaphe guttata*) was reported (Cimon et al., 1996). Most case reports have described clinical or subclinical infections in captive animals; cryptosporidiosis is rarely documented in wild reptile populations (Upton et al., 1989; Upton, 1990; O'Donoghue, 1995).

The first report of cryptosporidia in a reptile from Australia was described by McKenzie et al. (1978) in a red-bellied black snake (*Pseudechis porphyriacus*). Very few reports in reptiles in Australia have been described subsequently (Carmel and Groves, 1993; O'Donoghue, 1995).

This report describes the histopathological features associated with gastric infection by a *Cryptosporidium* sp. in a wild frilled lizard (*Chlamydosaurus kingi*). This host, a 0.22 kg 380 mm adult male frilled lizard of unknown age, was found dead in the area of Rum Jungle (Northern Territory, Australia; 13°02'S, 131°01'E) in February 1997. On physical examination, the frilled lizard was severely emaciated. At

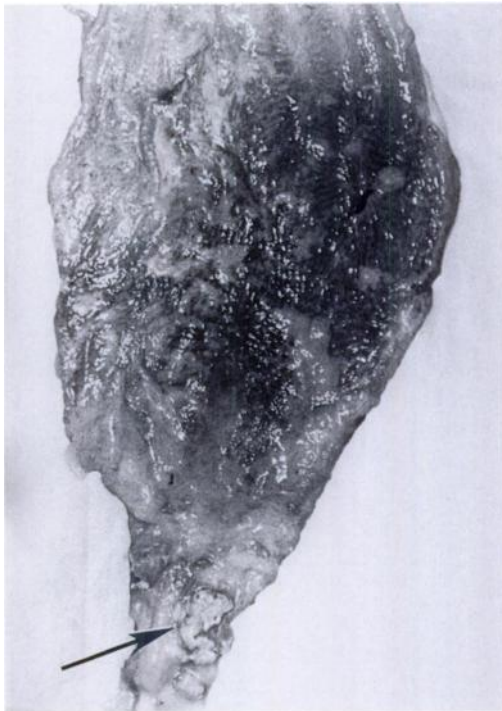

FIGURE 1. Gastric mucosa of a frilled lizard from Australia showing a dark color, prominent rugae and excessive amounts of mucus. Note also the firm yellow-white material on the pyloric mucosa (arrow).

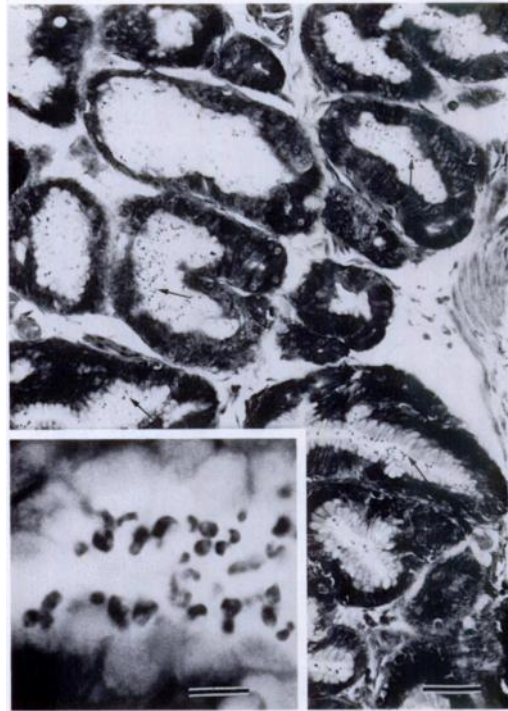


FIGURE 2. Severe *Cryptosporidium* sp. infection within gastric glands (arrows) of a frilled lizard from Australia. Giemsa stain. Bar = 240 μ m. Inset showing cryptosporidia on the surface of the mucosal epithelium and free in the gastric lumen. Giemsa stain. Bar = 11 μ m.

necropsy, it was judged to be in very poor nutritional condition due to paucity of adipose tissue and generalized muscle atrophy. The spleen was enlarged and friable. The liver also was friable, with a locally extensive pale area over one half of the dorsal hepatic surface. The stomach was firm with mild thickening of the gastric mucosa. Gastric rugae were prominent and the mucosa was red with a thin layer of dark red mucus on its surface (Fig. 1). In addition, a 6 mm diameter area of firm yellow-white material was observed on the mucosa of the pyloric region. The intestinal tract was empty and no macroscopic parasites were observed. The lungs showed diffuse reddening. No gross lesions were visible in other major organs.

Tissue samples of lungs, trachea, heart, liver, spleen, kidneys, stomach, and intestine were fixed in 10% neutral buffered formalin and sent to the Department of

Histology and Pathology, Veterinary Faculty of Las Palmas (Canary Islands, Spain) where they were routinely processed, embedded in paraffin, sectioned at 4 μ m, and stained with hematoxylin and eosin. Selected samples from stomach and intestine also were stained with Giemsa stain.

Light microscopic examination of the gastric samples revealed a mild diffuse gastritis with infiltration of the lamina propria by lymphocytes, plasma cells, and heterophils. A diffuse loss of granular cells was observed. Large numbers of small, round amphophilic to basophilic (2 to 4 μ m in diameter) protozoal organisms resembling cryptosporidia were seen on the surface of the mucosal epithelium and free in the gastric lumen (Fig. 2). The organisms stained basophilic with Giemsa stain. The mucosa of the pyloric region was necrotic, with disorganized mucosal epithelium and

infiltrate of mononuclear inflammatory cells. There were small amounts of cellular debris, and few cryptosporidia free in the lumen. The submucosa showed moderate diffuse infiltration by lymphocytes and marked congestion of blood vessels. The intestine showed no microscopic lesions and cryptosporidia were not detected on the intestinal epithelium. Post mortem alterations due to autolysis were found in the liver and spleen. The lungs showed mild diffuse hemorrhages. No microscopic lesions were seen in other organs.

The morphology of the organisms and their location along the surface of the gastric epithelial cells were consistent with those of *Cryptosporidium* spp. A voucher specimen has been deposited in the U.S. National Parasite Collection (Beltsville, Maryland, USA; USNPC Accession No. 87385).

This is the first report of cryptosporidiosis in a frilled lizard. Most cases of cryptosporidiosis reported in lizards have involved subclinical gastric infections (Upton, 1990), although overt clinical signs of disease such as anorexia, weight loss, and lethargy also have been described in a chameleon (*Chamaeleo chamaeleo senegalensis*) (Dillehay et al., 1986), and in two ocellated lacertas (*Lacerta lepida*) (Frost et al., 1994). In addition, cloacal infection was reported in two species of geckos (*Hemidactylus turcicus* and *Phelsuma madagascariensis grandis*) but their clinical significance was unclear due to simultaneous infections with other coccidia (Upton and Barnard, 1987). No clinical signs were observed in this frilled lizard. However, the very poor nutritional condition observed indicated chronic disease, similar to that described previously in the lizards (Dillehay et al., 1986; Frost et al., 1994).

The gastric lesions seen in this frilled lizard did not involve atrophy, as previously described in lizards with gastric cryptosporidiosis (Dillehay et al., 1986; Frost et al., 1994). Lesions of the pyloric region were similar to the necrotizing gastritis as-

sociated with *Cryptosporidium* spp. and secondary bacteremia which was previously described in a green iguana (*Iguana iguana*) (Cranfield and Graczyk, 1996). Alterations in the gastric epithelium due to *Cryptosporidium* sp. infection increases the susceptibility to invasion by opportunistic microbial organisms (Frost et al., 1994). No microbiological cultures were made in this case.

Lesions associated with cryptosporidiosis in snakes include proliferative gastritis characterized by hyperplasia of mucous cells of gastric glands. There is replacement of granular cells, edema of the submucosa and lamina propria, cellular infiltrates, and mucosal necrosis superimposed on epithelial hyperplasia in severe cases (Frost et al., 1994). The resulting excess mucus production and inadequate secretion of gastric enzymes produces a maldigestion syndrome leading to chronic weight loss and, in some cases, death (Frost et al., 1994). Although some authors suggest that the response of lizards differs from that of snakes to cryptosporidial infections (Frost et al., 1994), the gastric lesions observed in this frilled lizard were similar to those described previously in snakes (McKenzie et al., 1978; Carmel and Groves, 1993; O'Donoghue, 1995; Cimon et al., 1996; Cranfield and Graczyk, 1996). The possibility that more than one species of *Cryptosporidium* parasitize reptiles (Upton et al., 1989) could explain the different lesions, although other aspects such as immune status, intensity of the infection, and presence of simultaneous infections should be considered.

LITERATURE CITED

- BROWNSTEIN, D. G., J. D. STRANDBERG, R. J. MONTALI, M. BUSH, AND J. FORTNER. 1977. *Cryptosporidium* in snakes with hypertrophic gastritis. *Veterinary Pathology* 14: 606-617.
- CARMEL, B. P., AND V. GROVES. 1993. Chronic cryptosporidiosis in Australian elapid snakes: control of an outbreak in a captive colony. *Australian Veterinary Journal*, 70: 293-295.
- CIMON, K. Y., R. D. OBERST, S. J. UPTON, AND D. A. MOSIER. 1996. Biliary cryptosporidiosis in

- two corn snakes (*Elaphe guttata*). *Journal of Veterinary Diagnostic Investigation* 8: 398–399.
- CRANFIELD, M. R., AND T. K. GRACZYK. 1996. Cryptosporidiosis. In *Reptile medicine and surgery*. D. R. Mader (ed.). W. B. Saunders Company, Philadelphia, Pennsylvania, pp. 359–363.
- DILLEHAY, D. L., T. R. BOOSINGER, AND S. MCKENZIE. 1986. Gastric cryptosporidiosis in a chameleon. *Journal of the American Veterinary Medical Association* 189: 1139–1140.
- FROST, D. F., D. K. NICHOLS, AND S. B. CITINO. 1994. Gastric cryptosporidiosis in two ocellated lacertas (*Lacerta lepida*). *Journal of Zoo and Wildlife Medicine* 25: 138–142.
- GRACZYK, T. K., G. H. BALAZS, T. WORK, A. ALONSO AGUIRRE, D. M. ELLIS, S. K. K. MURAKAWA, AND R. MORRIS. 1997. *Cryptosporidium* sp. infections in green turtles, *Chelonia mydas*, as a potential source of marine waterborne oocysts in the Hawaiian Islands. *Applied and Environmental Microbiology* 63: 2925–2927.
- HEUSCHELE, W. P., J. OOSTERHUIS, D. JANSEN, P. T. ROBINSON, P. K. ENSLEY, J. E. MEIER, T. OLSON, M. P. ANDERSON, AND K. BENIRSCHKE. 1986. Cryptosporidial infections in captive wild animals. *Journal of Wildlife Diseases* 22: 493–496.
- MCKENZIE, R. A., P. E. GREEN, W. J. HARTLEY, AND C. C. POLLIT. 1978. *Cryptosporidium* in a red-bellied black snake (*Pseudechis porphyriacus*). *Australian Veterinary Journal* 54: 365–366.
- O'DONOGHUE, P. J. 1995. *Cryptosporidium* and cryptosporidiosis in man and animals. *International Journal for Parasitology* 25: 139–195.
- UPTON, S. J. 1990. *Cryptosporidium* spp. in lower vertebrates. In *Cryptosporidiosis of man and animals*. J. P. Dubey, C. A. Speer, and R. Fayer (eds.). CRC Press Inc., Boca Raton, Florida, pp. 149–156.
- UPTON, S. J., AND S. M. BARNARD. 1987. Two new species of Coccidia (Apicomplexa: Eimeriidae) from Madagascar gekkonids. *Journal of Protozoology* 34: 625–629.
- UPTON, S. J., C. T. MCALLISTER, P. S. FREED, AND S. M. BARNARD. 1989. *Cryptosporidium* spp. in wild and captive reptiles. *Journal of Wildlife Diseases* 25: 20–30.

Received for publication 22 December 1997.