



Sarcoptic Mange in Free-Ranging Pampas Foxes in the Gran Chaco, Bolivia

Authors: Deem, Sharon L., Noss, Andrew J., Cuéllar, Rosa Leny, Villarroel, Richard, Linn, Michael J., et al.

Source: Journal of Wildlife Diseases, 38(3) : 625-628

Published By: Wildlife Disease Association

URL: <https://doi.org/10.7589/0090-3558-38.3.625>

BioOne Complete (complete.BioOne.org) is a full-text database of 200 subscribed and open-access titles in the biological, ecological, and environmental sciences published by nonprofit societies, associations, museums, institutions, and presses.

Your use of this PDF, the BioOne Complete website, and all posted and associated content indicates your acceptance of BioOne's Terms of Use, available at www.bioone.org/terms-of-use.

Usage of BioOne Complete content is strictly limited to personal, educational, and non - commercial use. Commercial inquiries or rights and permissions requests should be directed to the individual publisher as copyright holder.

BioOne sees sustainable scholarly publishing as an inherently collaborative enterprise connecting authors, nonprofit publishers, academic institutions, research libraries, and research funders in the common goal of maximizing access to critical research.

Sarcoptic Mange in Free-Ranging Pampas Foxes in the Gran Chaco, Bolivia

Sharon L. Deem,^{1,5} Andrew J. Noss,² Rosa Leny Cuéllar,² Richard Villarroel,² Michael J. Linn,³ and Donald J. Forrester⁴ ¹ Field Veterinary Program, Wildlife Conservation Society, 2300 Southern Boulevard, New York 10460, USA; ² Proyecto Kaa-Iya, CABI-WCS Bolivia, Casilla 6272, Santa Cruz, Bolivia; ³ Department of Pathology, Wildlife Conservation Society, 2300 Southern Boulevard, New York 10460, USA; ⁴ Department of Pathobiology, College of Veterinary Medicine, Gainesville, Florida 32610-0126, USA; ⁵ Corresponding author (email: sdeem@wcs.org)

ABSTRACT: *Sarcoptes scabiei* infestation was diagnosed in two freshly dead free-ranging pampas foxes (*Pseudalopex gymnocercus*) in the Gran Chaco, Bolivia. Diagnosis was made based on histologic evaluation of skin biopsies and identification of the parasite from skin scrapings. Characteristic gross lesions consistent with mange were noted in 19 of 94 observations of free-ranging pampas foxes in the region from December 1998 to January 2000. None of 16 crab-eating foxes (*Cerdocyon thous*) observed during the same time period had visible lesions consistent with scabies. These are the first case reports of *S. scabiei* in pampas foxes.

Key words: Bolivia, Gran Chaco, mange, pampas fox, *Pseudalopex gymnocercus*, *Sarcoptes scabiei*.

Sarcoptes scabiei infestation is an intensely pruritic and highly contagious disease of domestic and free-ranging canids worldwide (Muller et al., 1983; Davidson and Nettles, 1997). Epidemics of mange caused by *S. scabiei* commonly occur in free-ranging canid populations (Trainer and Hale, 1969; Lindstrom, 1991). However, in many wild canid populations sarcoptic mange is often endemic and only occasionally causes epidemics (Todd et al., 1981; Pence et al., 1983). Among fox species, susceptibility to clinical disease associated with *S. scabiei* infestation varies. In red foxes (*Vulpes vulpes*) *S. scabiei* infestations are often severe and debilitating (Lindstrom, 1991; Davidson and Nettles, 1997); whereas gray foxes (*Urocyon cinereoargenteus*) are poor hosts with only an occasional animal reported to have clinical signs associated with sarcoptes mites (Davidson and Nettles, 1997; Little et al., 1998).

Two fox species, the pampas fox (*Pseu-*

dalopex gymnocercus) and the crab-eating fox (*Cerdocyon thous*), occur in the Gran Chaco region of Bolivia (Eisenberg and Redford, 1999). The Gran Chaco ecosystem is a neotropical dry forest with dense, thorny vegetation that covers a region of approximately one million square kilometers in Argentina, Bolivia, Brazil, and Paraguay (Taber et al., 1997). To the authors' knowledge, cases of *S. scabiei* infestation have not been reported in either captive or free-ranging pampas foxes. Here we describe cases of natural *S. scabiei* in free-ranging pampas foxes in the Gran Chaco, Bolivia. Additional evidence of scabies in the pampas fox population of the Gran Chaco, Bolivia is provided based on observations and epidemiologic data.

An adult, female pampas fox was found dead in May 1999 in the Gran Chaco, Bolivia (19°10'43.3"S, 62°31'33.0"W) and an adult, male pampas fox was found dead in July 1999 near the site of the first fox (19°38'7.5"S, 62°39'24.3"W). Both animals were found next to a dirt road. There was no evidence of vehicular trauma and the cause of death was not apparent for either fox. Gross lesions consisted of alopecia and thickened, flaky skin over the caudal dorsal trunk and tail. Three skin scrapings were collected from the alopecic areas of both animals. Scrapings were placed in 70% ethyl alcohol for subsequent parasite identification. Additionally, three skin biopsies were collected and stored in 10% neutral buffered formalin for histologic examination. Skin biopsies from both foxes were embedded in paraffin, sectioned at 5 μ m, and stained with hematoxylin and eosin (HE). Skin scrapings containing mites

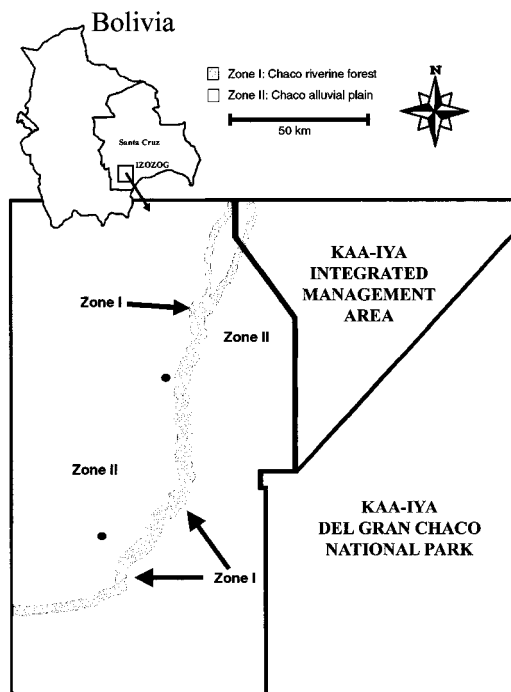


FIGURE 1. Map of the Izozog study area within the Gran Chaco, Bolivia with zones I (in gray) and II (in white) indicated and the locations (●) of pampas foxes (*Pseudalopex gymnocercus*) with scabies.

were examined microscopically for identification purposes. Voucher specimens were deposited in the arthropod section of the United States Department of Agriculture, National Veterinary Services Laboratories, Ames, Iowa, USA (Accession Number 99-30736).

Between December 1998 and January 2000 foxes were observed opportunistically during monthly field trips to the Gran Chaco. These fox observations were part of a larger study in which we recorded every mammal seen while traveling in the study area either in a vehicle or on foot. The study area included two principal landscape systems (Navarro and Fuentes, 1999). Zone I is a narrow strip of Chaco riverine forest extending up to 2 km on either side of the Parapetí river, which cuts through the Chaco alluvial plain of zone II (Fig. 1). This zone includes all of the 24 Izoceño communities (total population 8,000 inhabitants) present in the Bolivian

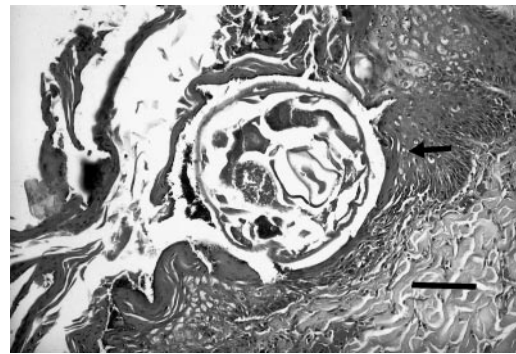


FIGURE 2. Moderate, chronic dermatitis with orthokeratotic hyperkeratosis and intracorneal sarcoptic mite (arrow) in the skin of a female pampas fox (*Pseudalopex gymnocercus*). HE. Bar=85 μ m.

Chaco, together with their irrigated fields and domestic animals, along an 80 km stretch of the Parapetí River. Zone II consists of hunting and extensive livestock grazing areas, and contains a mosaic of low dense thorny forests with patches of grasslands on sandy soils. We recorded location of foxes in zone I (near Izoceño villages) or zone II (far from Izoceño villages), presence or absence of clinical signs suggestive of *S. scabiei* infestation, and live versus dead. Data were analyzed by the chi-square test (Ott, 1988).

In August 2000, skin scrapings were collected from seven adult domestic dogs from four Izoceño villages in the Gran Chaco. Samples were collected from dogs with alopecia, pruritis, and hyperkeratosis. Scrapings were placed in 70% ethyl alcohol for subsequent parasite identification.

Histologic lesions in the skin from both dead foxes were chronic, moderate dermatitis with orthokeratotic hyperkeratosis and intracorneal sarcoptic mites (Fig. 2). Mites were oval and 100–300 μ m \times 125 μ m. Mites had a thick chitinous cuticle with prominent dorsal spines. Sections of thin shelled, oval 70–100 μ m \times 30–70 μ m ova were also present in some areas of the stratum corneum. Presence of sarcoptic mites in skin sections from the foxes in our study is uncommon in domestic dogs (Yager and Scott, 1993) and supports a diagnosis of mange. Identification of the mites

as *S. scabiei* was confirmed based on morphologic features seen with light microscopic examination of materials from skin scrapings.

Nineteen of 94 (20%) pampas foxes observed between December 1998 and January 2000 had clinical signs suggestive of *S. scabiei* infestation. Of 38 pampas fox sightings in zone I, five (13%) pampas foxes had signs of *S. scabiei* infestation. Of 56 sightings in zone II, fourteen (25%) pampas foxes had signs of *S. scabiei* infestation. There was no statistical difference (chi-square; $P = 0.16$) in observations of mange in pampas foxes between zone I and zone II.

Nineteen of 94 (20%) pampas fox observations were from animals found dead and three of these 19 (16%) dead foxes had lesions suggestive of sarcoptic mange. Histology and parasite identification confirmed the presence of *S. scabiei* in two foxes. There was no statistical difference (chi-square; $P=0.59$) between dead versus live pampas foxes observed with clinical signs of scabies infestation.

From December 1998 to January 2000 we observed 16 crab-eating foxes. All these foxes were alive, sighted in zone I (near villages), and none had visible signs of *S. scabiei* infestation. The prevalence of clinical signs of *S. scabiei* was higher in pampas foxes than crab-eating foxes (chi-square; $P<0.05$).

One of seven dogs from which skin scrapings were collected was positive for *S. scabiei*. Evidence of fungal infection in skin scrapings from two dogs was found based on light microscopic examinations (Muller et al., 1983).

Some domestic dogs in the study area have mange based on clinical signs and positive skin scrapings. Although we only detected mites in one of seven dogs tested, the true prevalence in the area may be much higher because *S. scabiei* is notoriously difficult to find in skin scrapings from domestic dogs (Yager and Scott, 1993). *Sarcoptes scabiei* is highly contagious and transmission is possible between

different canid species (Davidson and Nettles, 1997). In our study area, we do not know what species acts as a reservoir of *S. scabiei* or what role domestic dogs play in the transmission of *S. scabiei* to wild carnivores in the Gran Chaco. If domestic dogs are responsible for transmission of *S. scabiei* to the pampas foxes, more foxes in zone I (near Izoceño villages and a large population of domestic dogs) than in zone II would be expected to have clinical signs. Pampas foxes were observed in zone I ($n=38$) and zone II ($n=56$) and yet 14 of 19 pampas foxes with clinical lesions were sighted in zone II. Although published data on the home range of pampas foxes is not available, our anecdotal findings suggest that it is not large enough to bias the prevalence of pampas fox scabies in zone I and zone II if the foxes are acquiring the agent from domestic dogs.

The density and distribution of the two fox species within the Gran Chaco, Bolivia is presently unknown. Pampas foxes and crab-eating foxes in the Gran Chaco have similar dietary requirements and it is possible that some competitive exclusion occurs due to similar diets (Langguth, 1975). These two fox species are sympatric throughout the region, although the pampas fox may prefer more open habitat when available (i.e., zone II); whereas crab-eating foxes may be more dependent on riverine forest habitat (i.e., zone I) (Berta, 1982; Brooks, 1992). This may explain distribution and range of crab-eating foxes which have a small home range, 0.6–0.9 km², which would limit them to zone I in our study area (Berta, 1982; Eisenberg and Redford, 1999). Thus, it is interesting that none of 16 crab-eating foxes we observed had clinical signs suggestive of scabies although they were all present in zone I (near Izoceño villages). Possible explanations for this finding are a lower susceptibility to scabies in this species compared to pampas fox, an insignificant role of domestic dogs in the transmission of this agent, or the small number of foxes examined in our study.

Prevalence of clinical signs of scabies infestation was different between pampas and crab-eating foxes. Although we were able to collect samples from just two of 19 pampas foxes with skin lesions, further studies would help elucidate the role of *S. scabiei* as a cause of morbidity and mortality in this population. Mange may reduce wild canid populations (Trainer and Hale, 1969; Lindstrom, 1991). However, another study found no effect of mange on canid population dynamics and abundance (Pence et al., 1983). If *S. scabiei* is an important parasite of pampas foxes it may be wise to set management recommendations to minimize the potential impact of this disease on this CITES appendix II species (Nowak, 1991).

We gratefully acknowledge M. M. Uhart for her help with the literature search, K. C. Poppe for help in map design, and J. W. Mertins for confirmation of the identification of mites. We also thank J. Ayala for assisting in data collection. This manuscript was made possible by financial support of the United States Agency for International Development (USAID) through the Kaa-Iya Project (USAID/Bolivia Grant No. 511-0000-6-00-6031).

LITERATURE CITED

- BERTA, A. 1982. *Cerdocyon thous*. Mammalian Species 186: 1–4.
- BROOKS, D. M. 1992. Notes on group size, density, and habitat association of the pampas fox (*Dusicyon gymnocerus*) in the Paraguayan Chaco. Mammalia 56: 314–316.
- DAVIDSON, W. R., AND V. F. NETTLES. 1997. Field manual of wildlife diseases in the southeastern United States, 2nd Edition. Southeastern Cooperative Wildlife Disease Study, Athens, Georgia, pp. 181–183.
- EISENBERG, J. F., AND K. H. REDFORD. 1999. Mammals of the neotropics, The central neotropics, Vol. 3, Ecuador, Peru, Bolivia, Brazil. University of Chicago Press, Chicago, Illinois, pp. 281–284.
- LANGGUTH, A. 1975. Ecology and evolution in the South American canids. In *The wild canids*, M. W. Fox (ed.). Van Nostrand Rienhold Company, New York, New York, pp. 192–206.
- LINDSTROM, E. 1991. Patterns of spread and effects of sarcoptic mange among red fox populations in Sweden. In *Global trends in wildlife management*, B. Bobek, K. Perzanowski and W. L. Regelin (eds.). 18th International Union of Game Biologists Congress, Transactions Vol. 1, Swiat Press, Kraków-Warszawa, Poland, pp. 591–595.
- LITTLE, S. E., W. R. DAVIDSON, E. W. HOWERTH, P. M. RAKICH, AND V. F. NETTLES. 1998. Diseases diagnosed in red foxes from southeastern United States. *Journal of Wildlife Diseases* 34: 620–624.
- MULLER, G. H., R. W. KIRK, AND D. W. SCOTT. 1983. *Small animal dermatology*, 3rd Edition. W.B. Saunders, Philadelphia, Pennsylvania, pp. 243–300, pp. 351–360.
- NAVARRO, G., AND A. FUENTES. 1999. Geobotánica y sistemas ecológicos de paisaje en el Gran Chaco de Bolivia. *Revista Boliviana de ecología y conservación ambiental* 5: 25–50.
- NOWAK, R. M. 1991. Order Carnivora. In *Walker's mammals of the World*, 5th Edition, Vol. 2, R. M. Nowak (ed.). The Johns Hopkins University Press, Baltimore, Maryland, pp. 1045–1219.
- OTT, L. 1988. *An introduction to statistical methods and data analysis*, 3rd Edition. PWS-Kent Publishing Company, Boston, Massachusetts, pp. 217–286.
- PENCE, D. B., L. A. WINDBERG, B. C. PENCE, AND R. SPROWLS. 1983. The epizootiology and pathology of sarcoptic mange in coyotes, *Canis latrans*, from south Texas. *Journal Parasitology* 69: 1100–1115.
- TABER, A. B., G. NAVARRO, AND M. A. ARRIBAS. 1997. A new park in the Bolivian Gran Chaco—An advance in tropical dry forest conservation and community-based management. *Oryx* 31: 189–198.
- TODD, A. W., J. R. GUNSON, AND W. M. SAMUEL. 1981. Sarcoptic mange: An important disease of coyotes and wolves of Alberta, Canada. In *Worldwide furbearer conference proceedings*, J. A. Chapman and D. Pursley (eds.). Worldwide Furbearer Conference, Inc., Frostburg, Maryland, pp. 706–729.
- TRAINER, D. O., AND J. B. HALE. 1969. Sarcoptic mange in red foxes and coyotes of Wisconsin. *Bulletin of the Wildlife Disease Association* 5: 387–391.
- YAGER, J. A., AND D. W. SCOTT. 1993. The skin and appendages. In *Pathology of domestic animals*, 4th Edition, Vol. 1, J. K. Jubb, P. C. Kennedy and N. Palmer (eds.). Academic Press, Inc., New York, New York, pp. 681–683.

Received for publication 1 May 2001.