



EVIDENCE FOR CHRONIC STRESS IN CAPTIVE BUT NOT FREE-RANGING CHEETAHS (ACINONYX JUBATUS) BASED ON ADRENAL MORPHOLOGY AND FUNCTION

Authors: Terio, Karen A., Marker, Laurie, and Munson, Linda

Source: Journal of Wildlife Diseases, 40(2) : 259-266

Published By: Wildlife Disease Association

URL: <https://doi.org/10.7589/0090-3558-40.2.259>

BioOne Complete (complete.BioOne.org) is a full-text database of 200 subscribed and open-access titles in the biological, ecological, and environmental sciences published by nonprofit societies, associations, museums, institutions, and presses.

Your use of this PDF, the BioOne Complete website, and all posted and associated content indicates your acceptance of BioOne's Terms of Use, available at www.bioone.org/terms-of-use.

Usage of BioOne Complete content is strictly limited to personal, educational, and non - commercial use. Commercial inquiries or rights and permissions requests should be directed to the individual publisher as copyright holder.

BioOne sees sustainable scholarly publishing as an inherently collaborative enterprise connecting authors, nonprofit publishers, academic institutions, research libraries, and research funders in the common goal of maximizing access to critical research.

EVIDENCE FOR CHRONIC STRESS IN CAPTIVE BUT NOT FREE-RANGING CHEETAHS (*ACINONYX JUBATUS*) BASED ON ADRENAL MORPHOLOGY AND FUNCTION

Karen A. Terio,^{1,3} Laurie Marker,² and Linda Munson¹

¹Department of Pathology, Microbiology, and Immunology, School of Veterinary Medicine, University of California—Davis, Davis, California 95616, USA

²Cheetah Conservation Fund, P.O. Box 1755, Otjiwarongo, Namibia

³Corresponding author (email: kterio@lumc.edu)

ABSTRACT: The cheetah (*Acinonyx jubatus*) is highly endangered because of loss of habitat in the wild and failure to thrive in captivity. Cheetahs in zoos reproduce poorly and have high prevalences of unusual diseases that cause morbidity and mortality. These diseases are rarely observed in free-ranging cheetahs but have been documented in cheetahs that have been captured and held in captive settings either temporarily or permanently. Because captivity may be stressful for this species and stress is suspected as contributing to poor health and reproduction, this study aimed to measure chronic stress by comparing baseline concentrations of fecal corticoid metabolites and adrenal gland morphology between captive and free-ranging cheetahs. Additionally, concentrations of estradiol and testosterone metabolites were quantified to determine whether concentrations of gonadal steroids correlated with corticoid concentration and to assure that corticosteroids in the free-ranging samples were not altered by environmental conditions. Concentrations of fecal corticoids, estradiol, and testosterone were quantified by radioimmunoassay in 20 free-ranging and 20 captive cheetahs from samples collected between 1994 and 1999. Concentrations of baseline fecal corticoids were significantly higher ($p=0.005$) in captive cheetahs (196.08 ± 36.20 ng/g dry feces) than free-ranging cheetahs (71.40 ± 14.35 ng/g dry feces). Testosterone concentrations were lower in captive male cheetahs (9.09 ± 2.84 ng/g dry feces) than in free-ranging cheetahs (34.52 ± 12.11 ng/g dry feces), which suggests suppression by elevated corticoids in the captive males. Evidence for similar suppression of estradiol concentrations in females was not present. Adrenal corticomedullary ratios were determined on midsagittal sections of adrenal glands from 13 free-ranging and 13 captive cheetahs obtained between 1991 and 2002. The degree of vacuolation of cortical cells in the zona fasciculata was graded for each animal. Corticomedullary ratios were larger ($p=0.05$) in captive cheetahs; however, there was no difference ($p=0.31$) in the degree of corticocyte vacuolation between the two populations. These data provide both morphologic and functional evidence suggestive of chronic stress in captive cheetahs. Further research into the role of hypercortisolemia in the pathogenesis of the reproductive abnormalities and unusual diseases of captive cheetahs is needed.

Key words: *Acinonyx jubatus*, adrenal, captivity, cheetah, corticoids, fecal steroids.

INTRODUCTION

The cheetah (*Acinonyx jubatus*) is highly endangered due to loss of habitat in the wild and conflicts with farmers in remaining habitats (Marker, 2002). Species survival cannot be assured through captive breeding programs alone because captive cheetahs reproduce poorly and are prone to develop unusual diseases that cause considerable morbidity and mortality (Marker et al., 1989; Munson, 1993; Munson et al., 1999). A reproductive survey of the North American captive cheetah population found that poor fecundity was mainly due to gonadal inactivity. Folliculogenesis in these cheetahs could be stim-

ulated by exogenous hormones, which indicates that gonadal function was suppressed (Wildt et al., 1993). The possibility that an endocrine stress response might be inhibiting the hypothalamic-pituitary-gonadal axis has been proposed (Jurke et al., 1997).

Captive cheetahs have a high prevalence of unusual diseases, such as veno-occlusive disease and glomerulosclerosis, that rarely occur in other species (Munson, 1993; Bolton and Munson, 1999). Also, common infectious agents, such as *Helicobacter* and feline infectious peritonitis (FIP), cause persistent and severe inflammatory disease in cheetahs (Eaton et al., 1993; Munson,

1993). These same unusual diseases occur within captive South African cheetahs whose environment and diet more closely mimic those of free-ranging cheetahs (Munson et al., 1999). Because captive and free-ranging cheetahs both lack genetic heterogeneity (O'Brien et al., 1985), one would expect to find similar diseases present within free-ranging cheetahs if these diseases had a genetic basis. However, these diseases have only rarely been documented in free-ranging Namibian cheetahs, which suggests the cause of these diseases in captive populations is more complex (Munson, unpubl. data). Interestingly, free-ranging cheetahs captured because of conflicts with humans and held in a captive setting temporarily or permanently have similar diseases to those of captive cheetahs in zoological parks. Furthermore, there is a trend toward increasing severity of these diseases with increasing time in captivity (Munson, unpubl. data). Results of these studies indicate that diseases seen in captive and wild-caught cheetahs are linked in some way to the captive environment. It is possible that captivity is stressful for this species, which is typically solitary and adapted for running, and that stress is a contributing factor in the poor health and reproduction of captive cheetahs.

Stressful stimuli result in release of adrenocorticotrophic hormone (ACTH) from the pituitary, which stimulates the cells of the zona fasciculata of the adrenal cortex to increase synthesis and secretion of cortisol (Axelrod et al., 1984). Persistent ACTH release, as occurs with chronic or repeated exposure to stressors, causes initial hypertrophy and then hyperplasia of the zona fasciculata (Dallman, 1984). Therefore, enlargement of the adrenal cortex has been used as a morphologic indicator of chronic stress (Estivariz et al., 1992). Adrenal cortical hyperplasia has been noted in captive, but not free-ranging, cheetahs (Munson, 1993; Munson et al., 1999); however, morphometric analyses and comparisons have not been con-

ducted on adrenal glands of free-ranging and captive cheetahs. Additionally, it is not known whether this hyperplasia is associated with a functional increase in corticoid production. Therefore, this research aimed to determine whether captive cheetahs had enlarged adrenal cortices and elevated baseline corticoid concentrations in comparison to free-ranging cheetahs.

MATERIALS AND METHODS

Adrenal and gonadal steroid concentrations

To determine baseline and variation in fecal corticoid concentrations in individual animals, daily fecal samples were collected for 14 consecutive days from 20 captive cheetahs (11 males, nine females) located at three different facilities within North America between 1994 and 1999. Samples were collected during the months of March–December and during a time period in which the animals were under consistent management. Animals were housed both on exhibit ($n=4$) where they could be viewed by the public and off exhibit ($n=16$) without exposure to the public. All cheetahs were born in captivity. Cheetahs had been reared naturally by their mothers ($n=12$) or taken from their mothers when they were young cubs and hand reared by humans ($n=5$). All five of the hand-reared captive cheetahs were housed off exhibit, while mother-reared cheetahs were housed on exhibit ($n=3$) or off exhibit ($n=9$). The rearing status of three animals was not known. Animals were exposed to natural variations in photoperiod and fed a commercial ground horse meat-based diet (Nebraska Brand Canine Diet; Central Nebraska Packing Co., North Platte, Nebraska, USA). Water was available ad libitum. Fecal samples were stored frozen immediately after collection and shipped on dry ice to our laboratory for analysis.

Single, fresh, fecal samples from free-ranging cheetahs were collected at “playtrees” located on farmlands in north-central Namibia in a region extending from 19°30'S to 23°30'S and 16°E to 19°E (Marker, 2002). Playtrees are sites at which cheetahs deposit feces and urine for territory marking. Twenty samples collected between 1994 and 1999 were selected for analysis based on radio-tracking data of animal movements, spoor, or camera trap data at the playtrees to optimize the likelihood that the samples collected were from different individuals. Samples were collected during the months of March–December. The sex of individuals was unknown; however, behavioral research has

shown that male cheetahs visit playtrees more frequently than females (Marker, 2002). Fecal samples collected from playtrees were stored frozen and shipped to our laboratory in 100% ethanol (Terio et al., 2002).

Fecal samples were dried, pulverized, and mixed, and the steroids were extracted using established methodology developed for cat feces (Graham and Brown, 1996; Brown and Wildt, 1997; Brown et al., 1998). Briefly, ~0.20 g of dried fecal sample was boiled in 5 ml of 90% ethanol:distilled water for 20 min. After centrifugation ($500 \times G$, 15 min), the supernatant was recovered and the pellet resuspended in an additional 5 ml of 90% ethanol:distilled water, vortexed for 1 min, and recentrifuged. The ethanol supernatants were combined, dried under air, and resuspended in 1 ml of methanol before diluting (1:10) in phosphate buffer (0.01 M PO_4 , 0.14 M NaCl, 0.01% NaN_3 , pH 7.4) for radioimmunoassay (RIA). All fecal data are expressed on a per gram dry weight basis.

Concentrations of cortisol, estradiol, and testosterone metabolites in fecal extracts were quantified using radioimmunoassay protocols previously validated for cheetahs and domestic cats (Brown et al., 1994, 1998; Graham and Brown, 1996; Terio et al., 1999). Fecal cortisol metabolite concentrations were quantified using a commercially available double-antibody ^{125}I -corticosterone RIA (ICN Biomedicals, Costa Mesa, California, USA; Terio et al., 1999) with a sensitivity of 12.5 ng/ml. Because of concerns that samples collected and handled under field conditions could be degraded by environmental and storage conditions and therefore have lower steroid hormone concentrations, concentrations of estradiol and testosterone were also quantified in all samples to determine whether these hormones were similarly affected. Fecal estradiol metabolite concentrations were quantified with a ^{125}I -estradiol double-antibody assay (Diagnostic Systems Laboratories, Inc., Webster, Texas, USA) with a sensitivity of 2.2 pg/ml. Fecal testosterone concentrations were quantified using a commercially available double-antibody ^{125}I -testosterone RIA (ICN Biomedicals) with a sensitivity of 0.1 ng/ml. All samples were assayed in duplicate. Inter-assay and intra-assay coefficients of variation were <10%.

Adrenal morphometry

Adrenal gland(s) were obtained from 13 adult free-ranging Namibian cheetahs (12 males, one female) that were either shot ($n=12$) for trophy hunting or depredation purposes or died from vehicular trauma ($n=1$) be-

tween 1997 and 2002. Estimated ages based on dentition and general body size ranged from 1 to 7 yr (Marker, 2002). Either one or both adrenal glands of 13 captive cheetahs (eight males, five females) ages 1–14 yr were selected from submissions to the American Zoo and Aquarium Cheetah Species Survival Plan Pathology Survey between 1991 and 2002. These cheetahs were selected because they died acutely without underlying chronic disease processes. The cause of death in these cheetahs was anesthetic accident during annual examinations ($n=6$), acute renal failure secondary to oxalate nephrosis ($n=4$), trauma ($n=1$), gastrointestinal perforation ($n=1$), and acute hemorrhagic necrosis of the liver ($n=1$). All but one captive cheetah was born in captivity. One cheetah was wild caught and brought into captivity at approximately 1 yr of age. Animals were housed both on exhibit ($n=8$) and off exhibit ($n=5$).

Both adrenal glands from nine captive and eight free-ranging cheetahs and one adrenal gland from four captive and five free-ranging cheetahs (other gland not available) were measured. Corticomedullary ratios were determined on midsagittal sections using an ocular micrometer. Two measurements were obtained from two different, random sites for each adrenal gland and averaged. When both adrenal glands were available, the corticomedullary ratios for each adrenal gland were averaged. The degree of vacuolation of corticocytes within the zona fascicularis was graded 0 to 3. Grade 1 consisted of multifocal vacuolation of corticocytes, grade 2 consisted of diffuse vacuolation with rare areas of cellular degeneration, and grade 3 consisted of diffuse vacuolation with numerous large vacuoles and large areas of cellular degeneration.

Data analysis

To determine whether corticoids from a single fecal sample were representative of the baseline concentration in an individual, the number of samples that fell within 2 standard deviations of the mean was determined from the 14 consecutive samples collected from 20 captive cheetahs. The majority (90%) of single sample corticoid concentrations fell within 2 standard deviations of the mean concentration for an individual captive cheetah, which indicates that a single fecal corticoid value from an animal likely represents its baseline value. Then, single samples from free-ranging cheetahs were compared with the first sample of the 14-day sample collection period from captive cheetahs. Mean baseline corticoid concentrations in captive and free-ranging cheetahs were

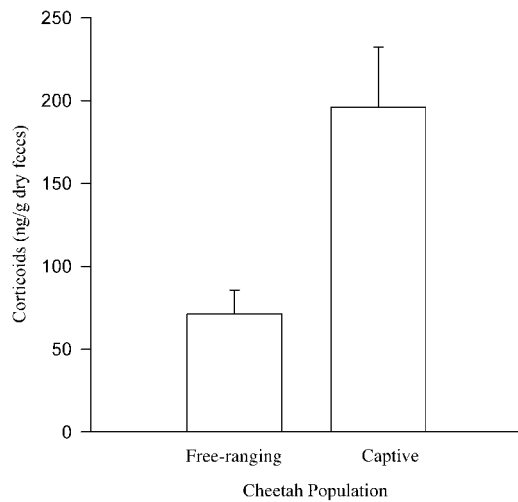


FIGURE 1. Mean \pm SEM baseline concentrations of fecal corticoids in captive and free-ranging cheetahs. Differences in corticoid concentration between these two populations are statistically significant ($P=0.005$).

compared using Wilcoxon signed rank test (Snedecor and Cochran, 1989). To test whether corticoid concentrations were altered from improper sample handling, correlation between concentrations of corticoids with estradiol and testosterone were evaluated using the Pearson correlation coefficient (Snedecor and Cochran, 1989).

To determine whether adrenal measurements from cases with only one adrenal gland available were representative of the average size of both adrenal glands, corticomedullary ratios for each adrenal gland were compared to the average of both adrenal glands in animals from which both adrenal glands were available using the Pearson's correlation coefficient (Snedecor and Cochran, 1989). Values from single adrenal gland measurements significantly correlated with the average ($R=0.832$), which validates the use of single adrenal glands to reflect the size of adrenal glands in an animal. Corticomedullary ratios and degrees of cortical vacuolation between captive and free-ranging cheetahs were compared using the Wilcoxon signed rank test (Snedecor and Cochran, 1989).

RESULTS

Captive cheetahs had significantly higher baseline corticoid concentrations than free-ranging cheetahs ($P=0.005$; Fig. 1). Mean \pm standard error of the mean (SEM) baseline concentrations were 196.08 ± 36.20

for captive cheetahs and 71.40 ± 14.35 ng/g dry feces for free-ranging cheetahs. In general, there was a tendency for concentrations of corticoids to be higher ($P=0.068$) in animals housed on exhibit (mean 283.63 ± 51.30 ng/g dry feces) than in animals housed off exhibit (138.98 ± 15.17 ng/g dry feces). However, there was a large amount of individual variation with baseline corticoid concentrations of cheetahs at one off-exhibit facility ranging from 53.46 to 256.88 ng/g dry feces so that differences between on- and off-exhibit groups were not significant. Cheetahs that were hand reared had lower concentrations of corticoids (90.20 ± 14.10 ng/g dry feces) than those that were mother reared (186.11 ± 22.72 ng/g dry feces; $P=0.022$); however, all of the hand-reared animals were housed off exhibit. When baseline corticoid concentrations between hand-reared and mother-reared animals housed off exhibit were compared, the difference was not significant ($P=0.131$).

Animals in both populations with low corticoids did not also have lower concentrations of estradiol ($R=0.178$) or testosterone ($R=0.176$). Within the cheetahs of known sex, there was no difference in cortisol metabolite concentrations between males and females ($P=0.42$). Concentrations of testosterone metabolites were significantly higher in free-ranging cheetahs (unknown sex) than in captive males ($P=0.048$), while concentrations of estradiol were significantly higher in captive females and males than in free-ranging cheetahs (unknown sex; $P=0.006$; Fig. 2). There was no difference ($P=0.953$) in concentrations of estradiol metabolites between captive female (14.73 ± 28.50 ng/g dry feces) and captive male cheetahs (14.42 ± 2.89 ng/g dry feces).

Corticomedullary ratios of adrenal glands of captive cheetahs were higher than those of free-ranging cheetahs ($P=0.05$; Fig. 3). The mean \pm SEM corticomedullary ratios were 2.07 ± 0.18 for captive cheetahs and 1.92 ± 0.26 for free-ranging cheetahs. The degree of vacuola-

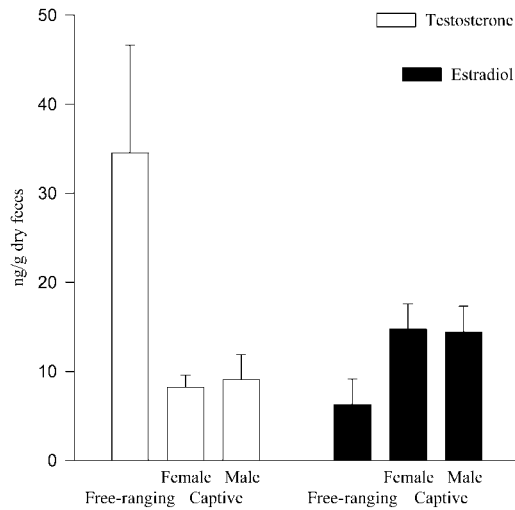


FIGURE 2. Mean \pm SEM concentrations of estradiol and testosterone metabolites measured in the feces of free-ranging ($n=20$), captive female ($n=9$), and captive male ($n=11$) cheetahs. The sex of the free-ranging cheetahs was not known, although most were likely males. Concentrations of testosterone are higher ($P=0.048$) and concentrations of estradiol are lower ($P=0.006$) in free-ranging cheetahs than in either captive males or captive females.

tion of corticocytes within the zona fascicularis did not differ between captive and free-ranging cheetahs ($P=0.31$).

DISCUSSION

Results of this study provide both functional and morphologic evidence that cheetahs in captivity are under chronic stress. Adrenal cortices were larger and

corticoid concentrations were significantly higher in captive than in free-ranging cheetahs in this study. While numerous studies have evaluated the effects of capture on free-ranging animals, few studies have assessed the long-term effects of captivity on adrenal morphology and function. The adrenal glands of wild-caught captive-held African green monkeys (*Cercopithecus aethiops*), platypus (*Ornithorhynchus anatinus*), and nine-banded armadillos (*Dasypus novemcinctus*) are enlarged in comparison to adrenal glands from free-ranging animals of these species (McColl, 1983; Rideout et al., 1985; Suleman et al., 2000). Adrenocortical hyperplasia has also been documented in captive black rhinoceroses (Munson et al., 1998). Persistent elevations in cortisol concentrations have been noted in wild-caught, captive-held brushtail possums (*Trichosurus vulpecula*), sparrows (*Zonotrichia* sp.), and black rhinoceroses (*Diceros bicornis*; Kock et al., 1990; Marra et al., 1995; Baker et al., 1998). The results of these studies in a diverse range of mammalian and avian species corroborate the results in the present study that certain species may be maladapted to captivity and that maladaptation can result in a persistent adrenocortical stress response.

Increased baseline corticoid concentrations in captive cheetahs suggest that adrenal hyperplasia is associated with chronic

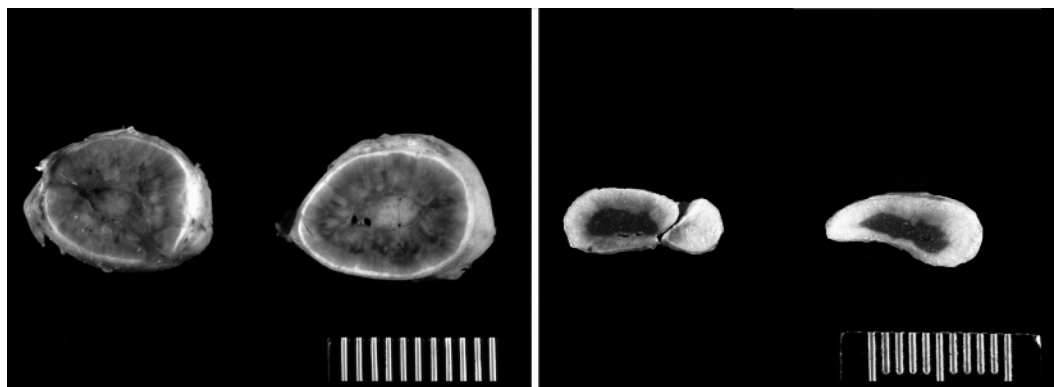


FIGURE 3. Adrenal glands from a captive (left) and a free-ranging (right) cheetah demonstrating significantly enlarged cortices in the captive cheetahs ($p=0.05$).

stimulation and an increase in corticoid production, although these variables were measured in different individuals. These findings were significant despite the large amount of individual variation in corticoid concentration. This variation could be due to timing of sample collection; however, long-term studies of adrenal activity in Namibian cheetahs have failed to demonstrate any seasonal effect on corticoid excretion (Terio et al., in press). Because cheetahs tend to defecate once daily, prandial and diel affects on corticoid secretion are also not thought to have contributed to the observed individual variation (Terio et al., 1999). Considerable individual variation has been documented in other species (Baker et al., 1998) and may be related to social (Shively and Kaplan, 1984), as well as environmental (Carlstead et al., 1992, 1993; Wielebnowski et al., 2002), factors.

The fact that cheetahs housed on exhibit tended to have higher baseline concentrations than those housed off exhibit suggests that cheetahs are also affected by their environment. These differences were not significant most likely because of the small sample size for the on-exhibit group and the large amount of individual variation even among animals housed at the same institution. Elevated corticoid concentrations have been found in clouded leopards on public display compared with those maintained off exhibit (Wielebnowski et al., 2002). Captive black rhinoceroses with more public access had increased mortality from diseases, some of which are suspected to be stress related (Munson et al., 1998; Carlstead et al., 1999). Based on these results in cheetahs and findings in other species, a broader survey of baseline corticoid concentrations in species whose health is thought to be adversely affected by stress needs to be conducted between different management conditions.

In our study, both free-ranging and captive cheetahs had adrenal cortical vacuolation. The time required to develop cortical vacuolation in cheetahs is not known.

In laboratory rats, total RNA levels were increased within the 24 hr following ACTH stimulation; however, adrenal histomorphology was only evaluated after prolonged stimulation (Dallman, 1984). Vacuolation and degeneration have been noted in free-ranging armadillos and wild-caught African green monkeys held in captivity for as little as 1 day (Rideout et al., 1985; Suleman et al., 2000). It is not known how long the animals shot as trophies in this study were pursued prior to being killed, but it is possible that the act of being hunted was perceived as a stressor resulting in the histologic vacuolation and degeneration of adrenal cortical cells. Alternatively, vacuolation of the adrenal cortical cells may not be a sensitive indicator of chronic stress.

Lack of correlation between corticoid concentrations and concentrations of estradiol or testosterone in these samples suggests that these lower concentrations of corticoids in free-ranging cheetahs were not the result of field conditions or improper handling. The lower concentrations of testosterone metabolites from captive cheetahs indicate that hypercortisolemia may have had the physiologic effect of suppressing the hypothalamic-pituitary-gonadal axis, an effect that has been documented in other species (Rivier and Rivest, 1991). If the free-ranging group included some females, then one would expect these differences in testosterone concentrations between the captive and free-ranging cheetahs to be even greater.

In contrast, concentrations of estradiol metabolites were significantly higher in the captive female cheetahs in comparison to those in free-ranging cheetahs, whose sex was unknown. This could be largely explained if the majority of the free-ranging cheetahs were male and therefore would be expected to have lower concentrations of estradiol. It is not likely that degradation of estradiol occurred, because previous research had indicated that concentrations of quantifiable estradiol metabolites tend, if anything, to increase when ex-

posed to heat and ultraviolet light, the most likely environmental factors to cause degradation of the samples collected from free-ranging cheetahs (Terio et al., 2002).

There was a wide range of estradiol metabolite concentrations in the captive females, which suggests that at least some of the animals were reproductively active. Unexpectedly, captive male cheetahs had strikingly similar mean concentrations of estradiol metabolites to captive females. It is possible that captive cheetahs are exposed to an exogenous source of estrogenic compounds in their diet, which are excreted into the feces in a form that is recognizable by the estradiol radioimmunoassay antiserum. The captive cheetahs in this study were all fed a commercial ground horse meat diet that has been shown to contain the phytoestrogens daidzein and genistein and may contain equid estrogens (Setchell et al., 1987). The phytoestrogens likely come from soy, which is added to the diet for increased protein. How these phytoestrogens are metabolized, whether they are physiologically active, and in what form they would be excreted is not known. While it is known that the assay antiserum cross-reacts with estrogenic compounds other than estradiol, there is no available information on the cross-reactivity of this antiserum with phytoestrogens. It is also possible that exogenous estrogens led to reductions in the testosterone concentrations noted in the captive male cheetahs.

In summary, captive cheetahs in this study had significantly higher baseline corticoid concentrations and larger adrenal cortices than free-ranging cheetahs. These findings suggest that captive cheetahs react to confinement through a persistent adrenocortical response. This chronic stress, manifested as elevated corticoids, could then be exerting physiologic effects that likely contribute to the high prevalence of unusual diseases and low reproductive success of captive cheetahs.

ACKNOWLEDGMENTS

The authors would like to thank the following institutions and their veterinarians for con-

tributing tissues and collecting fecal samples for this study: Binder Park Zoo, Caldwell Zoo, Cheetah Conservation Fund, Fossil Rim Wildlife Center, the Living Desert, Montgomery Zoo, White Oak Conservation Center, Wild About Cats, Zoo New England, and the Zoological Society of San Diego. We also wish to thank H. Theis of the Cheetah Conservation Fund for collection of wild cheetah fecal samples. We thank S. Wasser for advice on study design. This research was funded, in part, by a grant from the Morris Animal Foundation.

LITERATURE CITED

- AXELROD, J., AND T. D. REISINE. 1984. Stress hormones: Their interaction and regulation. *Science* 224: 452–459.
- BAKER, M. L., E. GEMMELL, AND R. T. GEMMELL. 1998. Physiological changes in brushtail possums, *Trichosurus vulpecula*, transferred from the wild to captivity. *Journal of Experimental Zoology* 280: 203–212.
- BOLTON, L. A., AND L. MUNSON. 1999. Glomerulosclerosis in captive cheetahs (*Acinonyx jubatus*). *Veterinary Pathology* 36: 14–22.
- BROWN, J. L., AND D. E. WILDT. 1997. Assessing reproductive status in wild felids by non-invasive faecal steroid monitoring. *International Zoo Yearbook* 35: 173–191.
- , S. K. WASSER, D. E. WILDT, AND L. H. GRAHAM. 1994. Comparative aspects of steroid hormone metabolism and ovarian activity in felids, measured noninvasively in feces. *Biology of Reproduction* 51: 776–786.
- , K. A. TERIO, AND L. H. GRAHAM. 1998. Fecal androgen metabolite analysis for non invasive monitoring of testicular steroidogenic activity in felids. *Zoo Biology* 15: 425–434.
- CARLSTEAD, K., J. L. BROWN, S. L. MONFORT, R. KILLENS, AND D. E. WILDT. 1992. Urinary monitoring of adrenal responses to psychological stressors in domestic and nondomestic felids. *Zoo Biology* 11: 165–176.
- , ———, AND J. SEIDENSTICKER. 1993. Behavioral and adrenocortical responses to environmental changes in leopard cats (*Felis bengalensis*). *Zoo Biology* 12: 321–331.
- , J. FRASER, C. BENNETT, AND D. G. KLEIMAN. 1999. Black rhinoceros (*Diceros bicornis*) in U. S. zoos: II. Behavior, breeding success, and mortality in relation to housing facilities. *Zoo Biology* 18: 35–52.
- DALLMAN, M. F. 1984. Control of adrenocortical growth *in vivo*. *Endocrine Research* 10: 213–242.
- EATON, K. A., M. J. RADIN, L. W. KRAMER, R. F. WACK, R. SHERDING, S. KRAKOWKA, J. G. FOX, AND D. R. MORGAN. 1993. Epizootic gastritis associated with gastric spiral bacilli in cheetahs

- (*Acinonyx jubatus*). *Veterinary Pathology* 30: 55–63.
- ESTIVARIZ, F. E., P. J. LOWRY, AND S. JACKSON. 1992. Control of adrenal growth. In *The adrenal gland*, V. H. T. James (ed.). Raven Press, Ltd., New York, New York, pp. 43–70.
- GRAHAM, L. H., AND J. L. BROWN. 1996. Cortisol metabolism in the domestic cat and implications for non-invasive monitoring of adrenocortical function in endangered felids. *Zoo Biology* 15: 71–82.
- JURKE, M. H., N. M. CZEKALA, D. G. LINDBURG, AND S. E. MILLARD. 1997. Fecal corticoid metabolite measurement in the cheetah (*Acinonyx jubatus*). *Zoo Biology* 16: 133–147.
- KOCK, M. D., R. DU TOIT, N. KOCK, D. MORTON, C. FOGGIN, AND B. PAUL. 1990. Effects of capture and translocation on biological parameters in free-ranging black rhinoceroses (*Diceros bicornis*) in Zimbabwe. *Journal of Zoo and Wildlife Medicine* 21: 414–424.
- MARKER, L. 2002. Aspects of the Namibian cheetah: Biology, ecology, and conservation strategies. PhD Dissertation, University of Oxford, Oxford, UK, 475 pp.
- , AND S. J. O'BRIEN. 1989. Captive breeding of the cheetah (*Acinonyx jubatus*) in North American zoos (1871–1986). *Zoo Biology* 8: 3–16.
- MARRA, P. P., K. T. LAMPE, AND B. L. TEDFORD. 1995. Plasma corticosterone levels in two species of *Zonotrichia* sparrows under captive and free-living conditions. *The Wilson Bulletin* 107: 296–305.
- MCCOLL, K. A. 1983. Pathology in captive platypus (*Ornithorhynchus anatinus*) in Victoria, Australia. *Journal of Wildlife Diseases* 19: 118–122.
- MUNSON, L. 1993. Diseases of captive cheetahs (*Acinonyx jubatus*): Results of the Cheetah Research Council Pathology Survey. *Zoo Biology* 12: 105–124.
- , J. W. KOEHLER, J. E. WILKINSON, AND R. E. MILLER. 1998. Vesicular and ulcerative dermatopathy resembling superficial necrolytic dermatitis in captive black rhinoceroses (*Diceros bicornis*). *Veterinary Pathology* 35: 31–42.
- , J. W. NESBIT, D. G. A. MELTZER, L. P. COLLY, L. BOLTON, AND N. P. J. KRIEK. 1999. Diseases of captive cheetahs (*Acinonyx jubatus jubatus*) in South Africa: A 20 year retrospective survey. *Journal of Zoo and Wildlife Medicine* 30: 342–347.
- O'BRIEN, S. J., M. E. ROELKE, L. MARKER, A. NEWMAN, C. A. WINKLER, D. MELTZER, L. COLLY, J. F. EVERMANN, M. BUSH, AND D. E. WILDT. 1985. Genetic basis for species vulnerability in the cheetah. *Science* 227: 1428–1434.
- RIDEOUT, B. A., G. E. GAUSE, K. BENIRSCHKE, AND B. L. LASLEY. 1985. Stress-induced adrenal changes and their relation to reproductive failure in captive nine-banded armadillos (*Dasypus novemcinctus*). *Zoo Biology* 4: 129–137.
- RIVIER, C., AND S. RIVEST. 1991. Effect of stress on the activity of the hypothalamic-pituitary-gonadal axis: Peripheral and central mechanisms. *Biology of Reproduction* 45: 523–532.
- SETCHELL, K. D. R., S. J. GOSSELIN, M. B. WELSH, J. O. JOHNSTON, W. F. BALISTRERI, L. W. KRAMER, B. L. DRESSER, AND M. J. TARR. 1987. Dietary estrogens—a probable cause of infertility and liver disease in captive cheetahs. *Gastroenterology* 93: 225–233.
- SHIVELY, C., AND J. KAPLAN. 1984. Effects of social factors on adrenal weight and related physiology of *Macaca fascicularis*. *Physiology and Behavior* 33: 777–782.
- SNEDECOR, G. W., AND W. G. COCHRAN. 1989. *Statistical methods*. 8th Edition. Iowa State University Press, Ames, Iowa, 524 pp.
- SULEMAN, M. A., E. WANGO, I. O. FARAH, AND J. HAU. 2000. Adrenal cortex and stomach lesions associated with stress in wild male African green monkeys (*Cercopithecus aethiops*) in the post-capture period. *Journal of Medical Primatology* 29: 338–342.
- TERIO, K. A., S. B. CITINO, AND J. L. BROWN. 1999. Fecal cortisol metabolite analysis for non-invasive monitoring of adrenocortical function in the cheetah (*Acinonyx jubatus*). *Journal of Zoo and Wildlife Medicine* 30: 484–491.
- , J. L. BROWN, R. MORELAND, AND L. MUNSON. 2002. Comparison of different drying and storage methods on quantifiable concentrations of fecal steroids in the cheetah. *Zoo Biology* 21: 215–222.
- , L. MARKER, E. W. OVERSTROM, AND J. L. BROWN. 2003. Analysis of ovarian and adrenal activity in Namibian cheetahs. *South African Journal of Wildlife Research* 33: 71–78.
- WIELEBNOWSKI, N., N. FLETCHALL, K. CARLSTEAD, J. M. BUSSO, AND J. L. BROWN. 2002. Noninvasive assessment of adrenal activity associated with husbandry and behavioral factors in the North American clouded leopard population. *Zoo Biology* 21: 77–98.
- WILDT, D. E., J. L. BROWN, M. BUSH, M. A. BARONE, K. A. COOPER, J. GRISHAM, AND J. G. HOWARD. 1993. Reproductive status of cheetahs (*Acinonyx jubatus*) in North American zoos: The benefits of physiological surveys for strategic planning. *Zoo Biology* 12: 45–80.

Received for publication 13 January 2003.