



Generalized Tuberculosis Due to *Mycobacterium caprae* in a Red Fox (*Vulpes vulpes*) in Austria

Authors: Steinparzer, Romana, Stanclova, Gabriela, Bagó, Zoltán, Revilla-Fernández, Sandra, Leth, Christoph, et al.

Source: Journal of Wildlife Diseases, 56(4) : 956-958

Published By: Wildlife Disease Association

URL: <https://doi.org/10.7589/2019-10-249>

BioOne Complete (complete.BioOne.org) is a full-text database of 200 subscribed and open-access titles in the biological, ecological, and environmental sciences published by nonprofit societies, associations, museums, institutions, and presses.

Your use of this PDF, the BioOne Complete website, and all posted and associated content indicates your acceptance of BioOne's Terms of Use, available at www.bioone.org/terms-of-use.

Usage of BioOne Complete content is strictly limited to personal, educational, and non - commercial use. Commercial inquiries or rights and permissions requests should be directed to the individual publisher as copyright holder.

BioOne sees sustainable scholarly publishing as an inherently collaborative enterprise connecting authors, nonprofit publishers, academic institutions, research libraries, and research funders in the common goal of maximizing access to critical research.

Generalized Tuberculosis due to *Mycobacterium caprae* in a Red Fox (*Vulpes vulpes*) in Austria

Romana Steinparzer,¹ Gabriela Stanclova,¹ Zoltán Bagó,¹ Sandra Revilla-Fernández,¹ Christoph Leth,¹ Erwin Hofer,¹ Barbara Pohl,¹ and Friedrich Schmoll¹ ¹Institute for Veterinary Disease Control, Austrian Agency for Health and Food Safety (AGES), Robert Koch Gasse 17, 2340 Mödling, Austria; ²Corresponding author (email: romana.steinparzer@ages.at)

ABSTRACT: *Mycobacterium caprae* subtype Lechtal was detected in a red fox (*Vulpes vulpes*) shot by a hunter in 2018 in the western part of Austria, where, among wildlife, tuberculosis is known to occur in red deer (*Cervus elaphus*). The red fox showed a generalized (disseminated) manifestation of the disease and a multibacillary distribution of mycobacteria in the inner organs.

Tuberculosis is one of the most prevalent zoonotic diseases worldwide and is caused by *Mycobacterium* species, classified among the *Mycobacterium tuberculosis* complex (MTC). In several countries, tuberculosis has been detected in wildlife species. In Austria, wildlife tuberculosis is caused by *Mycobacterium caprae*, a species occurring mainly in Europe. It can be found in red deer (*Cervus elaphus*) in the western Austrian states of Tyrol and Vorarlberg. In 2008, the prevalence of *M. caprae* in red deer was reported to be up to 23% (Schoepf et al. 2012; Fink et al. 2015). Another member of the MTC found in wildlife in Austria was *Mycobacterium microti*, found in a red deer in 2017 and in a fox in 2016. The degree of susceptibility and the pathologic characteristics of tuberculosis in red foxes are poorly researched. We provide a unique description of a *M. caprae* infection in a red fox.

In May 2018, the carcass of a hunted red fox from the state of Vorarlberg (47°9'N, 9°49'E) was sent to the Institute for Veterinary Disease Control in Mödling (Austria) to be tested for rabies and canine distemper virus (CDV) because of a behavioral disorder. Necropsy and routine histologic examination of organs were performed. The fluorescent antibody test on brain smears was used for excluding rabies (OIE 2018), and immunohistochemistry (IHC) using the avidin-biotin-

peroxidase complex technique was used for detection of the CDV antigen (primary antibody: CDV/NP/Clone/3780). Ziehl-Neelsen staining, an acid-fast staining of the affected organs, was conducted because the macroscopic and histologic findings indicated a mycobacterium infection. Cultivation of lungs, kidneys, and intestine was performed with the two MTC growth media: Löwenstein-Jensen with glycerin and PACT (polymyxin B, amphotericin B, carbenicillin, and trimethoprim) and Stonebrink with pyruvate and PACT (OIE 2009). Cultivation of liver and spleen was not feasible because of autolysis. A pooled organ sample (lungs, liver, spleen, kidneys, brain, stomach, and urinary bladder) was tested with two MTC-specific real-time PCRs targeting the *HELI* and the *IS1081* genes (Ringuet et al. 1999) and a modified mycobacteria genus nested PCR based on the *hsp65* gene (Friedrich Löffler Institute 2015). Region of difference 4 (RD4)-PCR (Domogalla et al. 2013) and the mycobacterial interspersed repetitive unit typing (MIRU) variable number tandem repeats (VNTR) technique (Supply et al. 2006) were conducted for genotyping of the MTC. The extracted DNA was also tested for CDV using the modification of Scagliarini et al. (2007) and for *Toxoplasma gondii* (LSI VetMAX, Thermo Fisher Scientific, Vienna, Austria).

The fox was an adult male in poor body condition. Despite severe auto- and heterolysis in the internal parenchymatous organs, such as lungs, liver, spleen, and kidneys, multifocal white miliary granulomas could be detected. The spleen was moderately enlarged; the other organs did not show any macroscopic changes. Histology revealed a moderate granulomatous, partially purulent

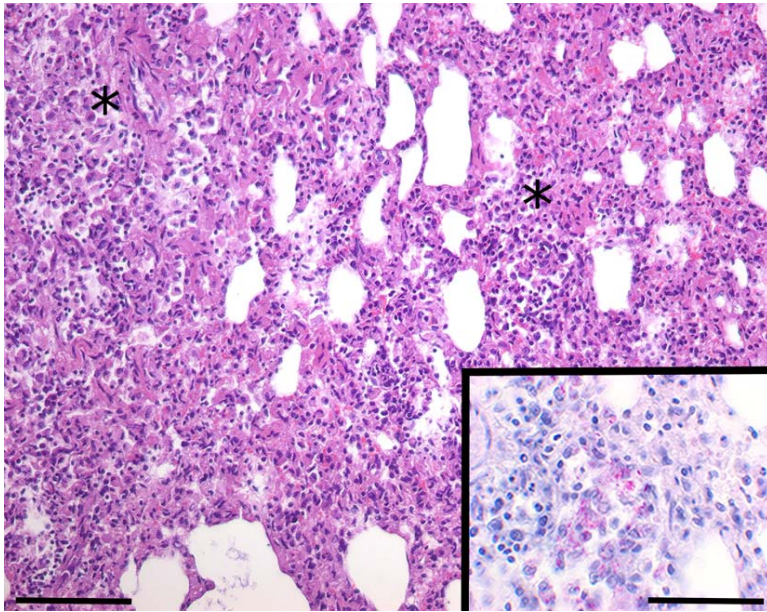


FIGURE 1. Tuberculosis in a red fox (*Vulpes vulpes*) shot by a hunter in 2018 in western Austria, showing multifocal granulomatous pneumonia (*) without nodular and giant cell formation. H&E stain. Bar=100 μ m. Inset: Numerous intralésional acid-fast bacilli. Ziehl-Neelsen stain. Bar=50 μ m.

pneumonia associated with numerous foamy macrophages within the alveoli. A severe multifocal granulomatous and purulent hepatitis accompanied by interstitial fibrosis was present. The spleen showed moderate red pulp hyperplasia with diffuse histiocytic infiltration. Severe multifocal granulomatous and purulent nephritis with giant cell formation and extensive parenchymatous necrosis were found. No inclusion bodies, as frequently found in CDV infections, could be seen. Numerous acid-fast and rod-shaped bacilli were demonstrated within the lesions of the lungs, liver, spleen, and kidneys using Ziehl-Neelsen staining (Fig. 1). Cultivation of tissue from lungs and intestine revealed a mycobacteria-positive result, whereas tissue from kidneys was negative. We detected MTC DNA in the pooled organ sample by the two MTC-specific real-time PCRs and the *hsp65*-nested PCR method. The RD4-PCR from the extracted DNA of the pooled organ sample and the RD4-PCR and MIRU-VNTR from positive bacterial cultures both identified *M. caprae* of the subtype Lechtal. The red fox tested negative for rabies by fluorescent

antibody test and for CDV by IHC, but CDV virus was amplified by real-time PCR. *Toxoplasma gondii* was not detected.

We detected *M. caprae* in a red fox hunted in the Austrian state of Vorarlberg, a region with a known presence of *M. caprae* in red deer. The subtype Lechtal was identified, which, in addition to subtypes Karwendel and Allgäu, is one of the three subtypes of *M. caprae* known in red deer in Austria (Domogalla et al. 2013). A total of 14 red deer tested positive for subtype Lechtal in the same area (47°9'N, 9°49'E) and in the same year 2018, whereas subtypes Karwendel and Allgäu were not detected. These results suggest an epidemiologic link between red deer and red foxes.

In Spain (Muñoz-Mendoza et al. 2013) and France (Zanella et al. 2008; Michelet et al. 2018), *Mycobacterium bovis* has been detected in red foxes by molecular biologic techniques or cultivation. Findings of *M. bovis* infections in red foxes from Spain (Millán et al. 2008), Portugal (Matos et al. 2016), and England (Delahay et al. 2007) are associated with macroscopic or microscopic lesions. In 2009, we detected *M. caprae* in the lymph

nodes of a red fox in Austria with no macroscopic lesions indicative of tuberculosis. A manifestation of the disease that was comparable to the present case was described in one red fox in Spain with a *M. bovis* infection (Millán et al. 2008). A possible reason for the disseminated manifestation, which is an advanced stage of the tuberculosis disease, in the present case and the case described in Spain is their common characteristic. Both red foxes had a concurrent viral infection, which is an immunosuppressive factor and can support the progression of the disease. In the case we described, but not in the case from Spain, a stage of late generalization of tuberculosis was also supported by the multibacillary intracellular distribution of the mycobacteria, which is in contrast to the characteristic *M. caprae* and *M. bovis* paucibacillary distribution. In conclusion, we can say that red foxes are susceptible to infection with *M. caprae* and a disseminated manifestation of the disease.

The authors thank the staff of the Institute for Veterinary Disease Control (AGES) for their excellent technical assistance and C. Örvell from the Karolinska Institute, Stockholm, Sweden, who provided the primary antibody for CDV IHC.

LITERATURE CITED

- Delahay RJ, Smith GC, Barlow AM, Walker N, Harris A, Clifton-Hadley RS, Cheeseman CL. 2007. Bovine tuberculosis infection in wild mammals in the South-West region of England: A survey of prevalence and a semi-quantitative assessment of the relative risks to cattle. *Vet J* 173:287–301.
- Domogalla J, Prodinger WM, Blum H, Krebs S, Gellert S, Müller M, Neuendorf E, Sedlmaier F, Büttner M. 2013. Region of difference 4 in alpine *Mycobacterium caprae* isolates indicates three variants. *J Clin Microbiol* 51:1381–1388.
- Fink M, Schleicher C, Gonano M, Prodinger WM, Pacciarini M, Glawischnig W, Ryser-Degiorgis MP, Walzer C, Stalder GL, Lombardo D, et al. 2015. Red deer as maintenance host for bovine tuberculosis, Alpine region. *Emerg Infect Dis* 21:464–467.
- Friedrich Löffler Institute. 2015. Tuberkulose der Rinder (*Mycobacterium bovis* und *Mycobacterium caprae*). In: *Antliche Methodensammlung*. www.openagrar.de/receive/openagrar_mods_00005698. Accessed May 2015.
- Matos AC, Figueira L, Martins MH, Pinto ML, Matos M, Coelho AC. 2016. New insights into *Mycobacterium bovis* prevalence in wild mammals in Portugal. *Transbound Emerg Dis* 63:313–322.
- Michelet L, De Cruz K, Hénauld S, Tambosco J, Richomme C, Réveillaud É, Gares H, Moyen JL, Boschirolu ML. 2018. *Mycobacterium bovis* infection of red fox, France. *Emerg Infect Dis* 24:1151–1153.
- Millán J, Jiménez MÁ, Viota M, Candela MG, Peña L, León-Vizcaíno L. 2008. Disseminated bovine tuberculosis in a wild red fox (*Vulpes vulpes*) in southern Spain. *J Wildl Dis* 44:701–706.
- Muñoz-Mendoza M, Marreros N, Boadella M, Gortázar C, Menéndez S, de Juan L, Bezos J, Romero B, Copano MF, Amado J, et al. 2013. Wild boar tuberculosis in Iberian Atlantic Spain: A different picture from Mediterranean habitats. *BMC Vet Res* 9:176.
- OIE (World Organization of Animal Health). 2009. Bovine tuberculosis. In: *Manual of diagnostic tests and vaccines for terrestrial animals*. www.oie.int/standard-setting/terrestrial-manual/access-online/. Accessed May 2018.
- OIE. 2018. Rabies. In: *Manual of diagnostic tests and vaccines for terrestrial animals*. www.oie.int/standard-setting/terrestrial-manual/access-online/. Accessed May 2018.
- Ringuet H, Akoua-Koffi C, Honore S, Varnerot A, Vincent V, Berche P, Gaillard JL, Pierre-Audigier C. 1999. *Hsp65* sequencing for identification of rapidly growing mycobacteria. *J Clin Microbiol* 37:852–857.
- Scagliarini A, Dal Pozzo F, Gallina L, Vaccari F, Morganti L. 2007. TaqMan based real time PCR for the quantification of canine distemper virus. *Vet Res Commun* 31 (Suppl 1):261–263.
- Schoepf K, Prodinger WM, Glawischnig W, Hofer E, Revilla-Fernandez S, Hofrichter J, Fritz J, Köfer J, Schmoll F. 2012. A two-years' survey on the prevalence of tuberculosis caused by *Mycobacterium caprae* in red deer (*Cervus elaphus*) in Tyrol, Austria. *ISRN Vet Sci* 2012:245138.
- Supply P, Allix C, Lesjean S, Cardoso-Oelemann M, Rüschi-Gerdes S, Willery E, Savine E, de Haas P, Van Deutekom H, Roring S, et al. 2006. Proposal for standardization of optimized mycobacterial interspersed repetitive unit-variable-number tandem repeat typing of *Mycobacterium tuberculosis*. *J Clin Microbiol* 44:4498–4510.
- Zanella G, Durand B, Hars J, Moutou F, Garin-Bastuji B, Duvauchelle A, Fermé M, Karoui C, Boschirolu ML. 2008. *Mycobacterium bovis* in wildlife in France. *J Wildl Dis* 44:99–108.

Submitted for publication 7 October 2019.

Accepted 9 March 2020.