



## PARASITIC NEOPLASIA IN THE GOLDEN PHEASANT\*

Authors: HELMBOLDT, C F., and WYAND, D. S.

Source: Journal of Wildlife Diseases, 8(1) : 3-6

Published By: Wildlife Disease Association

URL: <https://doi.org/10.7589/0090-3558-8.1.3>

---

BioOne Complete ([complete.BioOne.org](https://complete.BioOne.org)) is a full-text database of 200 subscribed and open-access titles in the biological, ecological, and environmental sciences published by nonprofit societies, associations, museums, institutions, and presses.

Your use of this PDF, the BioOne Complete website, and all posted and associated content indicates your acceptance of BioOne's Terms of Use, available at [www.bioone.org/terms-of-use](https://www.bioone.org/terms-of-use).

Usage of BioOne Complete content is strictly limited to personal, educational, and non - commercial use. Commercial inquiries or rights and permissions requests should be directed to the individual publisher as copyright holder.

---

BioOne sees sustainable scholarly publishing as an inherently collaborative enterprise connecting authors, nonprofit publishers, academic institutions, research libraries, and research funders in the common goal of maximizing access to critical research.

## PARASITIC NEOPLASIA IN THE GOLDEN PHEASANT\*

C. F. HELMBOLDT and D. S. WYAND

Department of Animal Diseases, University of Connecticut, Storrs, Connecticut 06268

**Abstract:** A neoplastic process considered to be a leiomyoma was seen in the cecal wall of three golden pheasants (*Chrysolophus pictus*). In each neoplasm, remnants of *Heterakis* sp. were present. This parasite caused inflammation which developed into the tumor. The reaction was unusual as Aves ordinarily react to focal intestinal insult by granuloma formation.

### INTRODUCTION

There is evidence that some parasites elicit neoplasia in the host. *Schistosoma* sp. are said to cause carcinoma of the bladder or of the colon in man,<sup>1,5</sup> while *Spirocercia lupi* is thought to induce fibrosarcoma and osteosarcoma in the canine esophagus with metastasis to the lung.<sup>10</sup> Rats have both sarcoma and carcinoma of parasitic origin: *Gongylonema neoplasticum* causes a gastric carcinoma,<sup>17</sup> but sarcoma results from *Cysticercus fasciolaris*.<sup>4,6</sup> *Heterakis isolonche* causes nodular lesions in the cecum of the golden pheasant. Some authorities considered these as neoplasms while others described them as nodular typhlitis. The purpose of this paper is to redirect attention to this somewhat unusual reaction.

A fibrosarcoma caused by *Heterakis papillosa* was reported by Galli-Valerio<sup>7</sup> in the cecum of a pheasant (*Phasianus versicolor*). Wassink<sup>18</sup> described a tumor caused by *Heterakis neoplastica* in the cecum of *Phasianus colchicus*, which Baylis<sup>2</sup> stated was actually *H. isolonche*. Krahnert<sup>11</sup> saw a sarcoid leiomyoma in a golden pheasant — he used the German term "Sarkoides Leiomyoma". Wetzl,<sup>10</sup> in a review paper, discussed *H. isolonche* in the golden pheasant and described the lesion as a tumor-like granuloma.

Letulle and Marotel<sup>12</sup> reported nodular

typhlitis in an unidentified type of pheasant caused by *Heterakis vesicularis*. Schwartz<sup>15</sup> ascribed nodular typhlitis in golden pheasants to *H. isolonche*, although *Heterakis gallinae* was present in the lumen. Beaudette<sup>3</sup> saw nodular typhlitis caused by *H. isolonche* in golden pheasants while Meads and Taylor<sup>14</sup> ascribed identical lesions in this bird to *H. gallinae*.

### CLINICAL HISTORY

Three specimens were submitted over a period of 6 months to the Department of Animal Diseases, University of Connecticut for diagnostic opinion. Two birds came from the same premises. Both "farms" were of the backyard variety and were characterized by confinement of several species of birds in inadequate quarters.

Nos. 1 and 2. Male, 1 year old, golden pheasants (*Chrysolophus pictus*) were presented dead. Age was not given for pheasant No. 2. The owner reported that the birds had become progressively weaker and emaciated over a period of several weeks and exhibited terminal gasping.

No. 3. Male, 8-month-old golden pheasant, formalin-fixed sections were submitted. This bird died after weeks of gasping, weight loss, and weakness.

\*Scientific Contribution No. 458, Storrs Agricultural Experiment Station, University of Connecticut, Storrs 06268.

## METHODS

The dead birds were examined by necropsy and samples for bacteriologic study were taken from heart blood, liver, and gall bladder. Tryptose agar and selenite broth were used for initial isolation. Representative sections of all systems were fixed in 10% formo-saline, embedded in paraffin, and stained with hematoxylin and eosin. The submitted fixed specimens were handled in a similar manner. Special stains used were Masson's trichrome, van Gieson's, Verhoeff's, and methenamine silver; these were employed in selected sections.

## RESULTS

### Gross and bacteriologic observations.

The two dead birds were emaciated. In No. 1, fibrinous peritonitis and pericarditis were present and from this specimen *Salmonella typhimurium* was isolated.

In all three birds, white nodules 1 to 2 mm in diameter were located about 1 cm apart in the walls of the cecum. The serosa was raised at this point and when the cecum was opened the mucosa was likewise elevated.

No other pathogenic bacteria were isolated and no other lesions were seen. In two birds *H. gallinae*\* was found in the cecal lumen.

### Histologic observations.

The lesion was directly under the muscularis mucosa of the cecum. It was discrete (Fig. 1), although a definite capsule did not exist (Fig. 2). There were gradations in the lesion from inflammatory to neoplastic. The more immature lesion was inflammatory, consisting of a mixture of lymphocytes and histiocytes accompanied by mesenchymal cells. The mesenchymal cells were often

distended by fat in the cytoplasm. The presumably mature lesion was dense, containing cells with large vesicular nuclei and "swirling" cytoplasm. Lymphocytes and histiocytes were not present. The staining characteristics resembled smooth muscle when van Gieson's technique was employed. Verhoeff's and Masson's trichrome techniques contributed no further characterization and methenamine silver revealed the absence of reticulin fibers within the mass. The majority of the lesions fell within the latter phase of development.

Within the body of this lesion were sections of small nematodes (Fig. 3) compatible with the morphology of *Heterakis* sp.<sup>13</sup> Nematodes were found in all nodules.

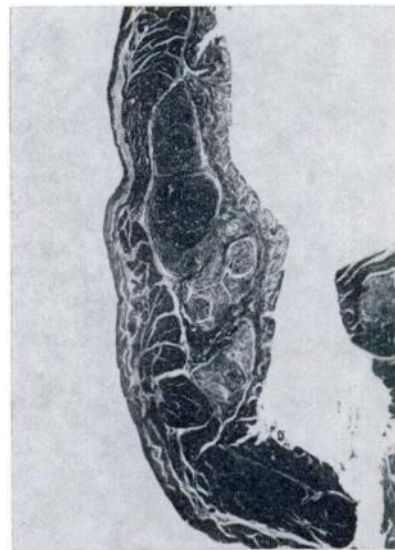

FIGURE 1. The mucosa is a thin portion to the right and the muscularis mucosa is represented as a thinner darker line. Several nodules are seen which are bordered on the left by muscle. H. and E. X 16.

\*We thank Dr. L. R. Penner, Biological Sciences Group, University of Connecticut, Storrs, for the identification of this parasite.

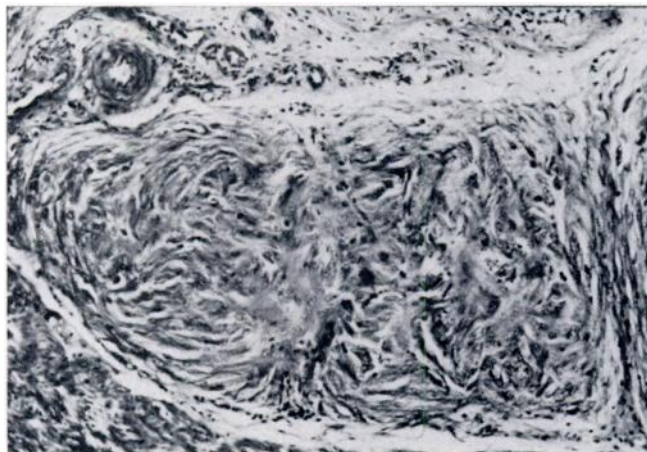


FIGURE 2. The swirling pattern of the smooth muscle, the leiomyoma, is seen in this nodule. H. and E. X 250.

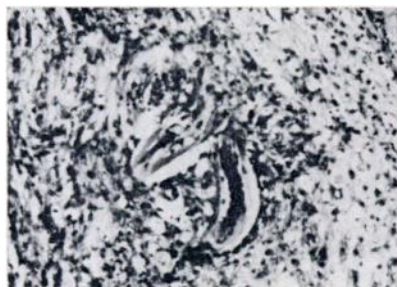


FIGURE 3. A fragment of the parasite lies within a nodule and a group of reactive lymphocytes. H. and E. X 250.

#### DISCUSSION

The duration of the neoplastic lesion was unknown and thus pathogenic interpretations are speculative. It is possible that after the parasite penetrated the mucosa the inflammatory reaction was followed by neoplasia. The inflammatory reaction was mild and chronic, characterized by lymphocytes and some vague attempt at granulation tissue. However, the classical granulation tissue of Mammalia is not common in Aves, perhaps because the heterophil is employed less often in phylogenetically lower forms.

The neoplastic response was not the expected avian reaction to focal insult of the intestine. This usually is a granu-

loma such as seen in colibacillosis,<sup>9</sup> *Eimeria necatrix*, and foreign body reaction. (The apparent predilection of birds to form granulomata has been observed by the authors in routine histopathologic work over many years.) Thus, the unusual neoplastic reaction immediately changes the aspect of the lesion.

Since van Gieson's stain suggested myogenic origin, it was classified as a leiomyoma; a common benign neoplasm of the reproductive tract of the domestic fowl. In the human uterus where it is commonly called a "fibroid", it is a benign tumor of smooth muscle, well demarcated from the surrounding muscle with interlacing bundles of fusiform cells with long processes and nuclei with blunted ends, a resemblance to smooth muscle;<sup>10</sup> the apparent capsule is the muscle which becomes compressed as the tumor increases.<sup>6</sup> The tumor in the present study had no capsule, resembled smooth muscle with a swirling pattern and blunted nuclei, was well demarcated from the surrounding tissue, and appeared to be benign. These characteristics, common to the leiomyoma of man and of the fowl, are support for the classification of leiomyoma.

The fate of the parasite is unknown. It seemed to fix and stain as viable tissue. Whether or not it eventually could find its way to the cecal lumen is purely a matter of conjecture.

## LITERATURE CITED

1. ASH, J. E., and B. SPITZ. 1945. *Pathology of Tropical Diseases*. W. B. Saunders Co., Philadelphia, Pennsylvania.
2. BAYLIS, H. A. 1925. On the identity of *Heterakis neoplastica* Wassink. *J. Trop. Med.* London 28: 362-364.
3. BEAUDETTE, F. R. 1942. *Heterakis isolonche* Linstow (1906) in a pheasant with remarks on tuberculosis and gapeworms. *J. Am. Vet. Med. Assoc.* 101: 274-275.
4. BULLOCK, F. D., and M. R. CURTIS. 1920. Experimental production of sarcoma of the liver of the rat. *Proc. N.Y. Pathol. Soc. (N.S.)* 20: 149-175.
5. CHANDLER, A. C. 1954. *Introduction to Parasitology*. John Wiley & Sons, Inc., New York.
6. DUNNING, W. F., and M. R. CURTIS. 1946. Multiple peritoneal sarcoma in rats from intraperitoneal injection of washed, ground *Taenia* larvae. *Cancer Res.* 6: 668-670.
7. GALLI-VALERIO, B. 1896. Nota preventiva sopra alcune neoformazioni nodulari. *Il Moderno Zooiatro* 7: 392-395, 405-412.
8. HERTIG, A. T., and H. GORE. 1960. Tumors of the female sex organs. Armed Forces Institute of Pathology, Fascicle 33, Section IX, pp. 234-235. Washington, D.C.
9. HJARRE, A., and G. WRAMBY. 1945. Undersökningar över en med specifika granuloma förlöpande hönssjukdom orsakad av mukoida kolibacterier (Koligranulom). *Skand. Veterinärtidskr.* 35: 449.
10. HORN, R. C., JR. 1966. Alimentary tract. In *Pathology*, (W. A. D. Anderson, editor), Chapter 26, pp. 878-879, 5th edition, C. V. Mosby, St. Louis, Missouri.
11. KRAHNERT, R. 1952. Sarkoides Leiomyom nach Heterakidenbefall. *Monatsh. Veterinärmed.* 7: 71-75.
12. LETULLE, M., and G. MAROTEL. 1909. Etudes des typhlitis parasitaires; nodules des caecum parasitaires chez le fiasem. *Arch. de parasit.* 12: 361-368.
13. MACHADO DE MENDONCA, J. 1953. *Heterakis isolonche* Linstow, 1906 e *Heterakis gallinae* (Gmelin, 1790) agentes causais da Tiflite verrucosa em faisoes no Jardim Zoologico do Distrito Federal. *Med. inst. Oswaldo Cruz* 51: 675-687.
14. MEADS, E. S., and P. A. TAYLOR. 1963. Typhlitis in pheasants due to *Heterakis gallinae*. *Canad. Vet. J.* 4: 56-59.
15. SCHWARTZ, B. 1924. Occurrence of nodular typhlitis in pheasants due to *Heterakis isolonche* in North America. *J. Am. Vet. Med. Assoc.* 65: 622-628.
16. SEIBOLD, H. R., W. S. BARLEY, B. F. HOERLEIN, E. M. JORDAN, and C. S. SCHWABE. 1955. Observations on the possible relations of malignant esophageal tumors and *Spirocerca lupi* lesions in the dog. *Am. J. Vet. Res.* 16: 5-14.
17. SMITH, H. A., and T. C. JONES. 1966. *Veterinary Pathology*, 3rd edition, Lea and Febiger, Philadelphia, Pennsylvania.
18. WASSINK, W. F. 1917. Over Gazwellen by den Fazant, veroorzaakt door een Worm, *Heterakis neoplastica*. *Nederl. Tydschr. Vergel. Geneesk.* 2.
19. WETZEL, H. C. R. 1967. Parasitäre Erkrankungen des Darmes. In Volume VI, *Joest's Handbuch Der Speziellen Pathologischen Anatomie Der Haustiere*, pp. 672-675. Paul Parey, Berlin.

Received for publication February 5, 1971